



Preoperative Functional MRI and Diffusion Tensor Imaging; Acquisition and Visualization for Neurosurgery

Department of Neurosurgery
Surgical Planning Laboratory

Brigham and Women's Hospital, Harvard Medical School, Boston, MA, USA

National Center for Image-Guided Therapy

Stephen Whalen, BS; Ralph Suarez, PhD; Daniel Branco, MD; James O'Shea, BS;
Yanmei Tie, PhD; Lauren O'Donnell, PhD; Isaiah Norton; Alireza Radmanesh, MD;
Sharon Peled, PhD; Carl-Fredrik Westin, PhD; Alexandra Golby, MD



CLINICAL FMRI AND DTI FOR SURGICAL PLANNING

OVERVIEW

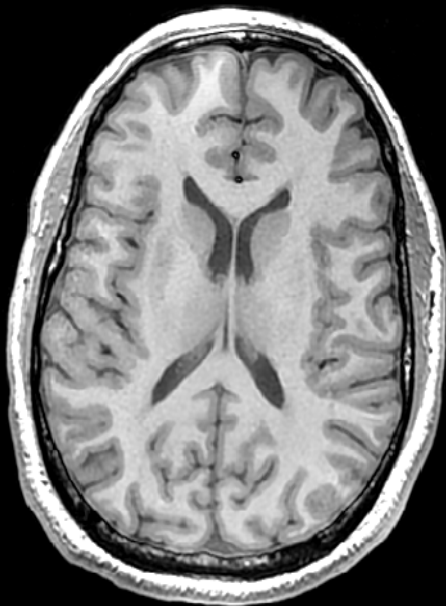
- The goal of surgical treatment for cerebral neoplasms is to maximize the extent of tumor resection while preventing or minimizing postoperative neurologic deficits.
- Preoperative functional MRI and DTI are highly effective, non-invasive methods of mapping eloquent cortical areas and critical white matter structures, so as to assess their relationship with a tumor or other pathological neural manifestations.

FUNCTIONAL MRI ANATOMICAL SCANS

ANATOMICAL SCANS

T1

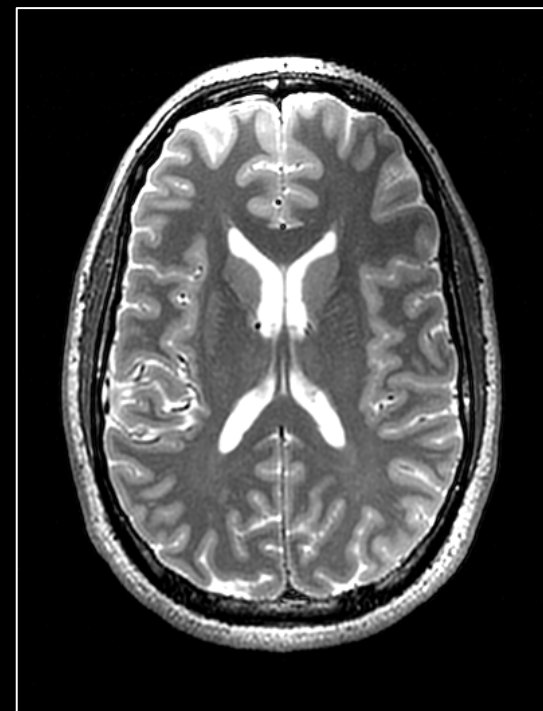- We use a high-resolution T1 scan for the anatomical underlay of functional activations.
- The T1 scan provides a high-resolution display for activations in all three planes, axial, sagittal, and coronal.
- T1 contrast causes the white matter to appear white, the gray matter to appear gray, and the cerebrospinal fluid to appear dark.



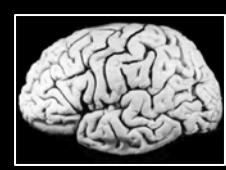SCAN PARAMETERS:
FREQ=256
PHASE=256
SLICE
THICKNESS=1.0mm
TE=30msec
TR=7200msec
PREP TIME=450msec
FLIP ANGLE=20°
BANDWIDTH=31.25Hz
FOV=25.6cm
NEX=1.0
PHASE FOV=1.0
FREQ DIR=A/P
SHIM=AUTO
SCAN TIME=9min

T2

- The T2 scan provides a high-resolution display for activations in the plane in which it was scanned, but also provides good resolution in the other two planes as well.
- T2 contrast causes the white matter to appear gray, the gray matter to appear white, and the cerebrospinal fluid to appear white.
- T2 contrast illuminates the presence of edema and lesions very nicely, as they will appear white.



SCAN PARAMETERS:
FREQ=256
PHASE=256
SLICE
THICKNESS=1.5mm
TE=80msec
ETL=8
TR=7200msec
BANDWIDTH=31.25Hz
FOV=25.6cm
GRAD MODE=ZOOM
SCAN TIME=7min



FUNCTIONAL MRI ACQUISITION

EXPERIMENTAL DESIGN AND LOGISTICS

Functional MRI is the detection of changes in blood flow and blood oxygen concentration in the brain, as an indirect measure of neural activity, during the performance of cognitive, sensory, and motor tasks during a stimulus paradigm

Functional Images are T²*-weighted
Blood Oxygen Level Dependent (BOLD)



BLOCK DESIGN



EVENT-RELATED DESIGN

rapid, **event-related** paradigms deliver a series of stimuli, scheduled in a predetermined interval

block design paradigms include relatively long intervals of alternating periods of task and rest



LANGUAGE

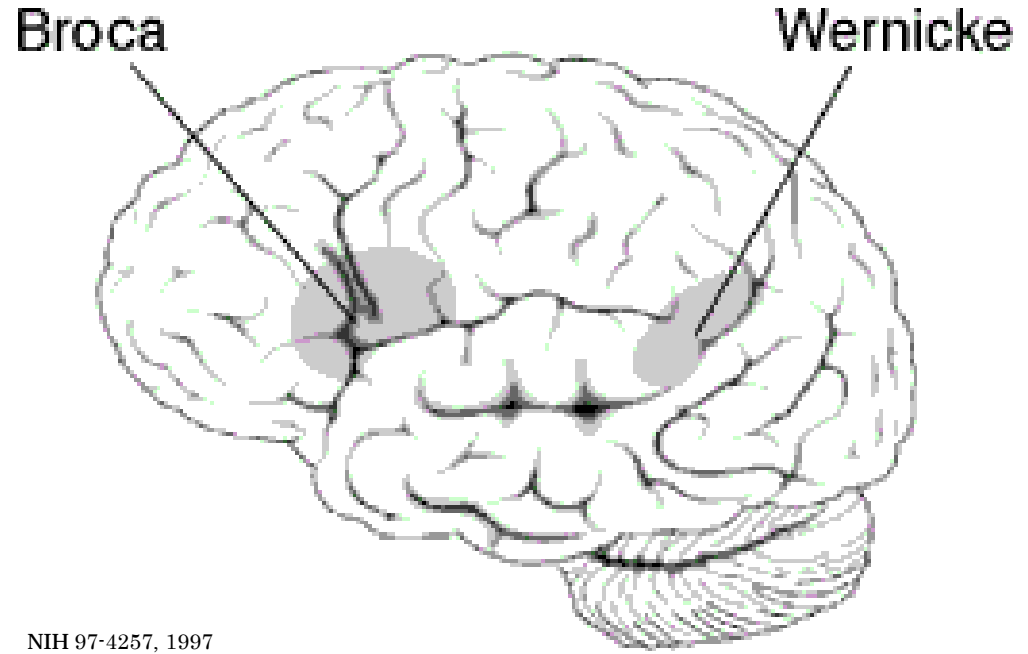
FUNCTIONAL MRI

Objective: the localization and lateralization of Broca and Wernicke's areas; and associated language cortex

Expressive Language

the encoding aspect of language, in Broca's area; motor speech

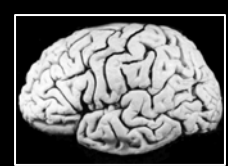- an antonym generation paradigm
- patients respond by thinking of a word they feel is most opposite in meaning to the presented word



Receptive Language

the decoding aspect of language, in Wernicke's area; language comprehension

- a noun categorization paradigm
- patients respond saying either "alive" or "not alive"

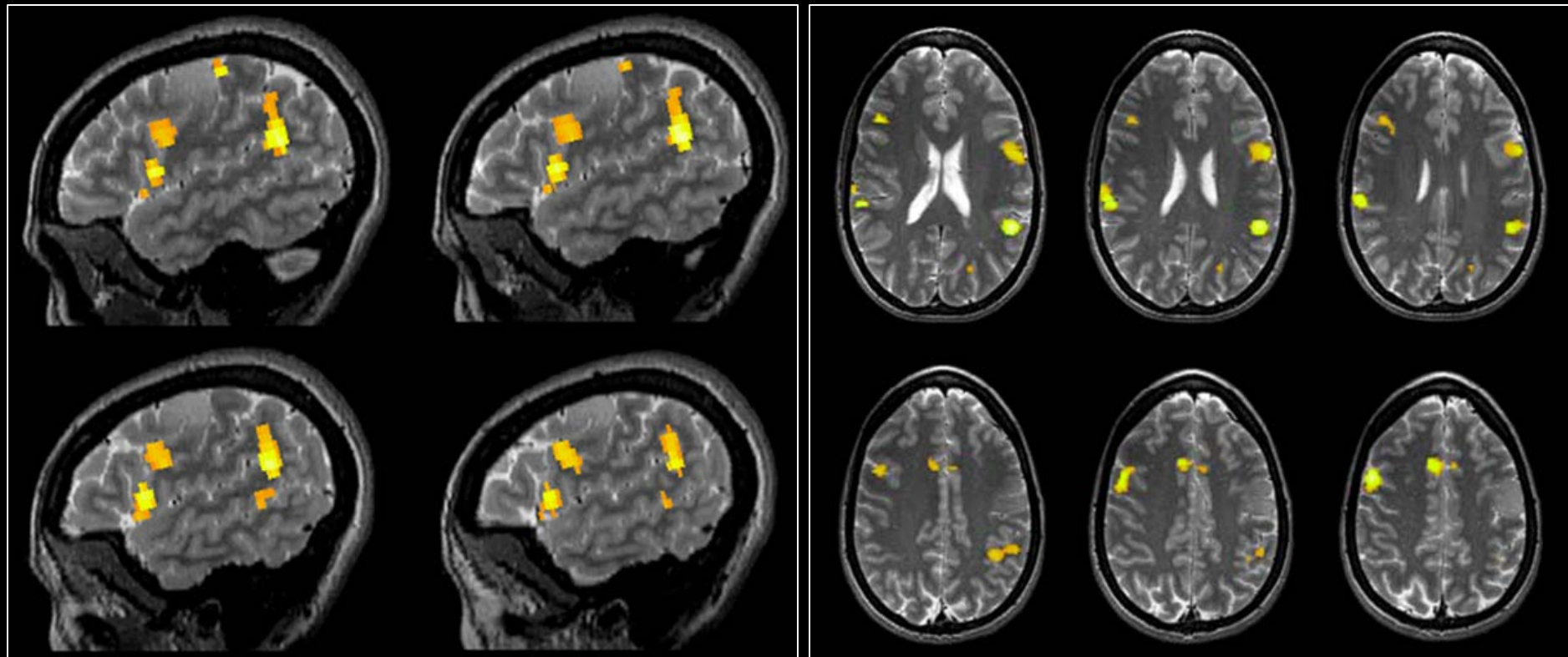


FUNCTIONAL MRI

LANGUAGE

Activation Maps

Expressive Language-Event-related Antonym Generation Task



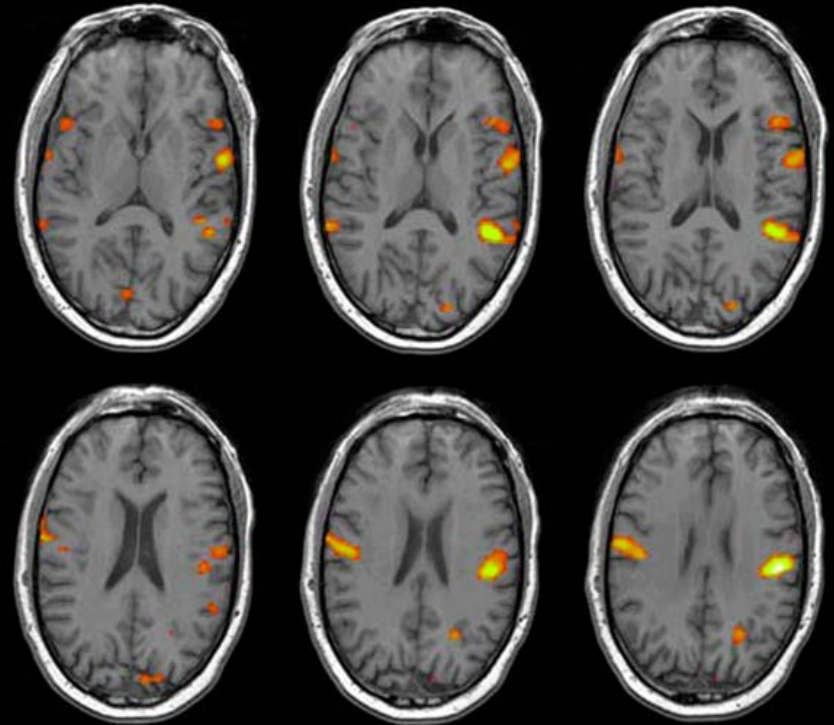
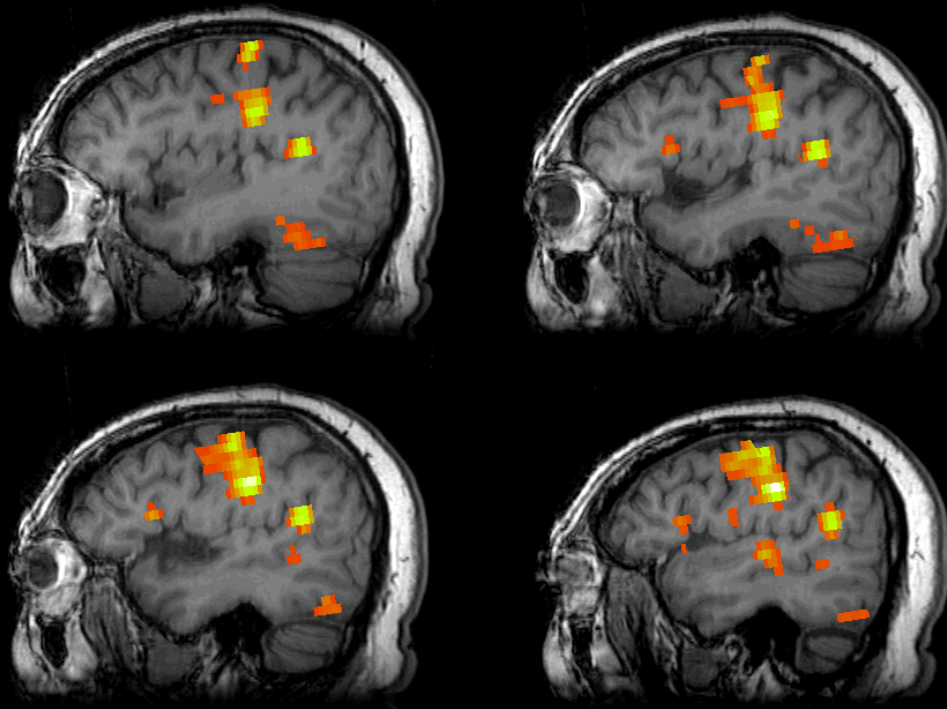


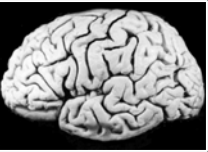FUNCTIONAL MRI

LANGUAGE

Activation Maps

Receptive Language-Event-related Noun Categorization Task



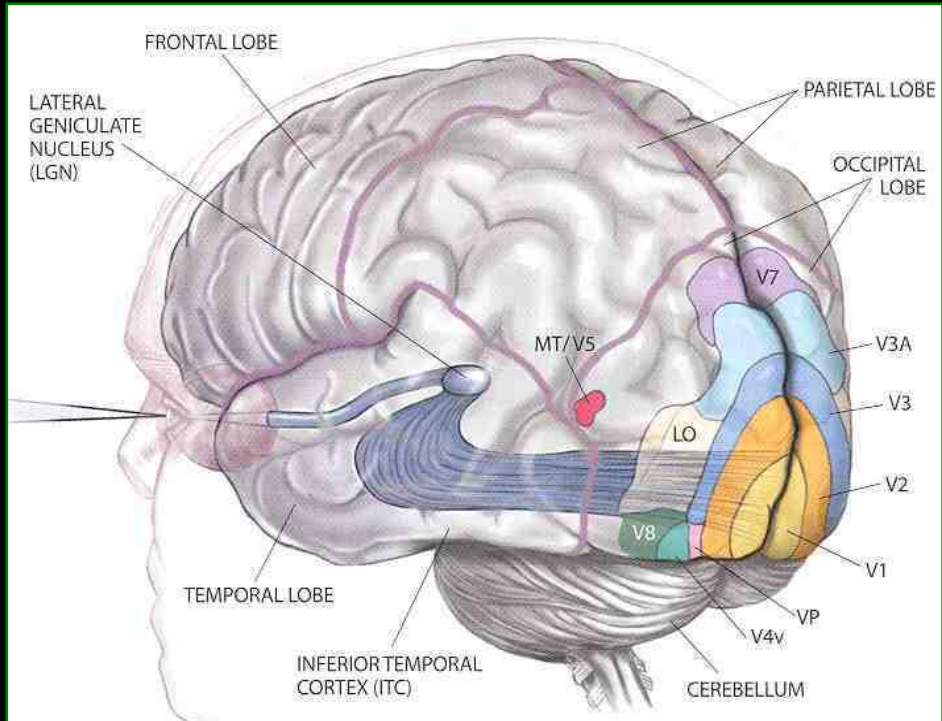


FUNCTIONAL MRI

VISION


Objective: the localization of primary visual cortex; and associated visual cortical structures

- The human visual system begins with the eyes and extends through the entire length of the temporal lobe before ascending to the various regions of the visual cortex in the occipital lobe.
- At the optic chiasm, the optic nerves cross over partially so that each hemisphere of the brain receives input from both eyes. The information is filtered by the lateral geniculate nucleus, which consists of layers of nerve cells that respond only to stimuli from one eye. Logothetis, Sci Am, 1999



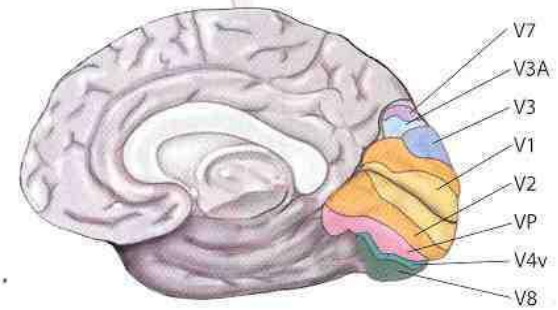
Logothetis, Sci Am, 1999

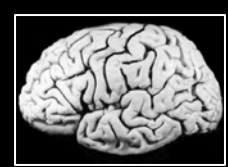Visual Stimuli



whole left hemi right hemi

V1: Primary visual cortex; receives all visual input. Begins processing of color, motion and shape. Cells in this area have the smallest receptive fields. V2, V3, VP: Continue processing; cells of each area have progressively larger receptive fields. V8: Processes color vision.





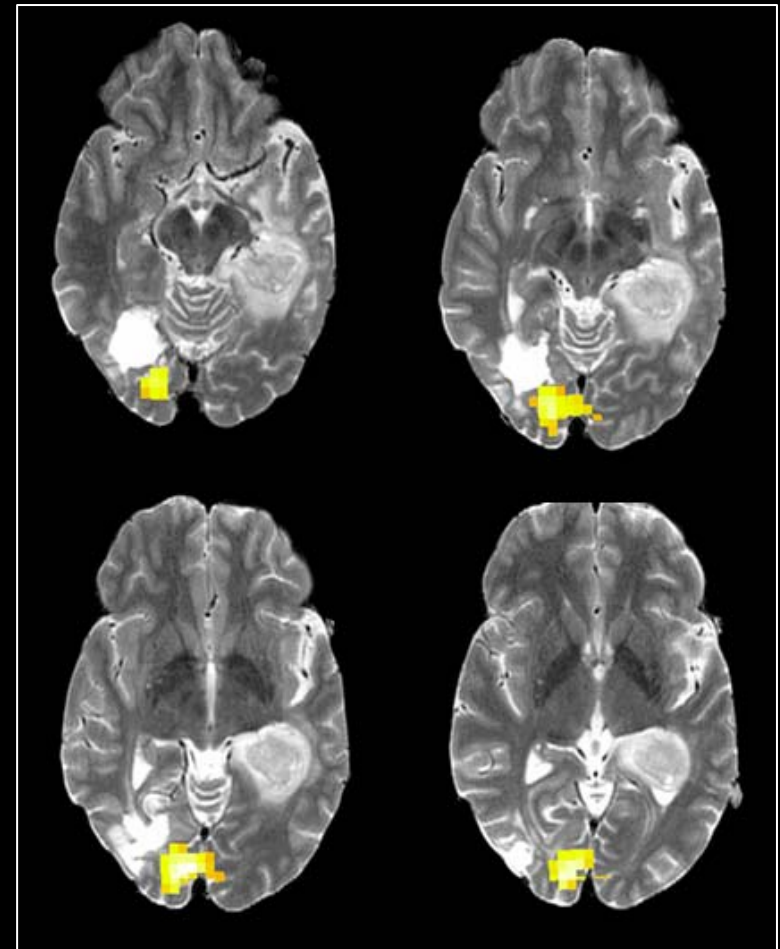
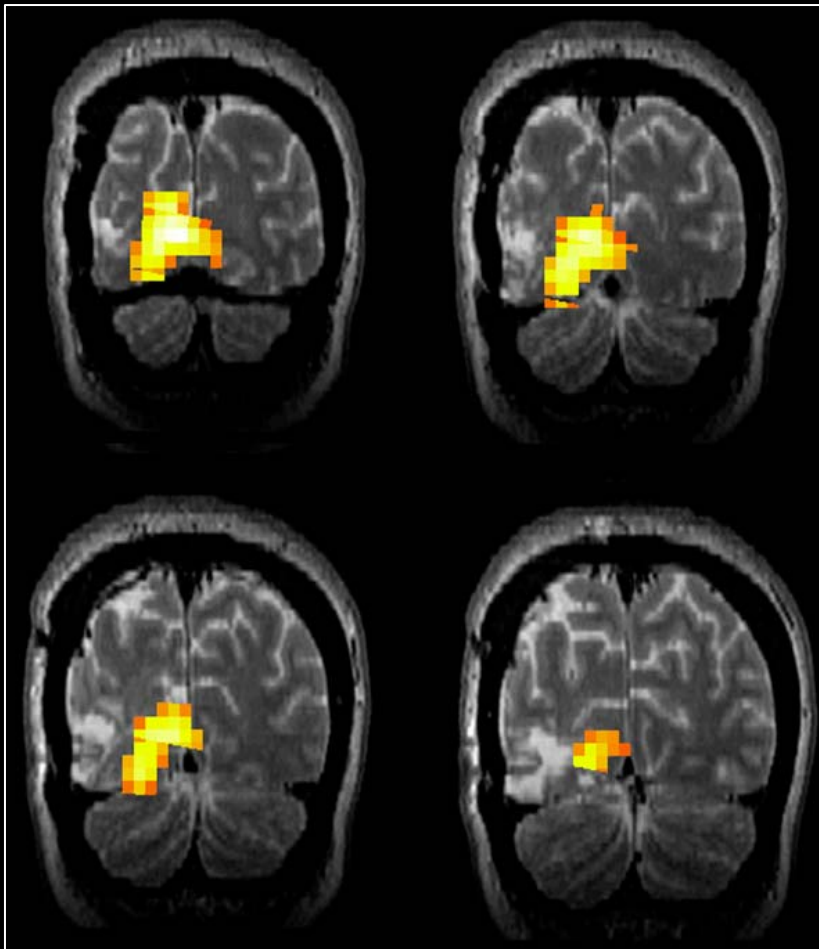
FUNCTIONAL MRI

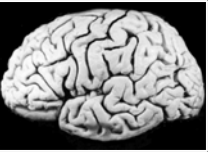
VISION

Visual Task:

- a block paradigm of twenty 20-second blocks of pattern-reversal (2Hz) of radial checkerboard stimuli for right, left, and whole visual field stimulation (lower left), and rest
- patients are instructed to maintain fixation on a point in the center of the radial checkerboard pattern

Activation maps generated from left hemi-field visual stimulation

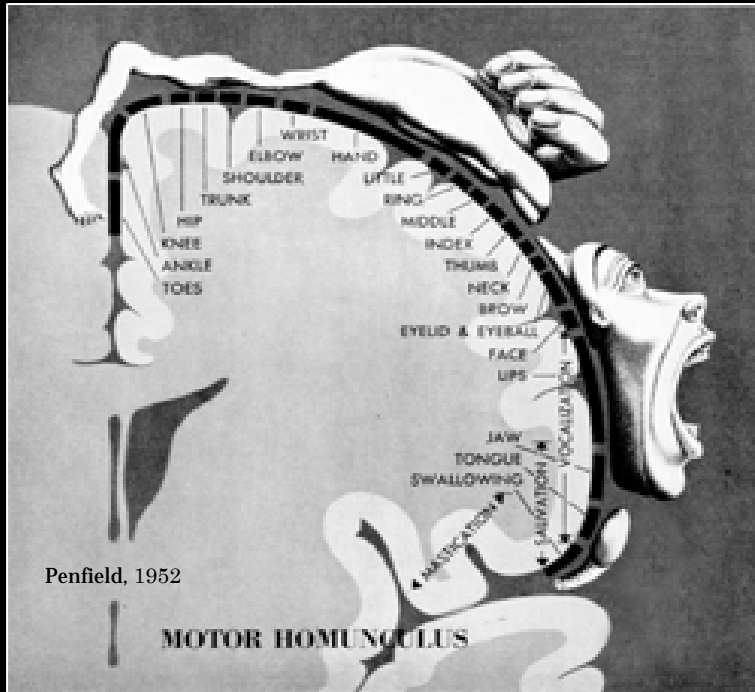




FUNCTIONAL MRI

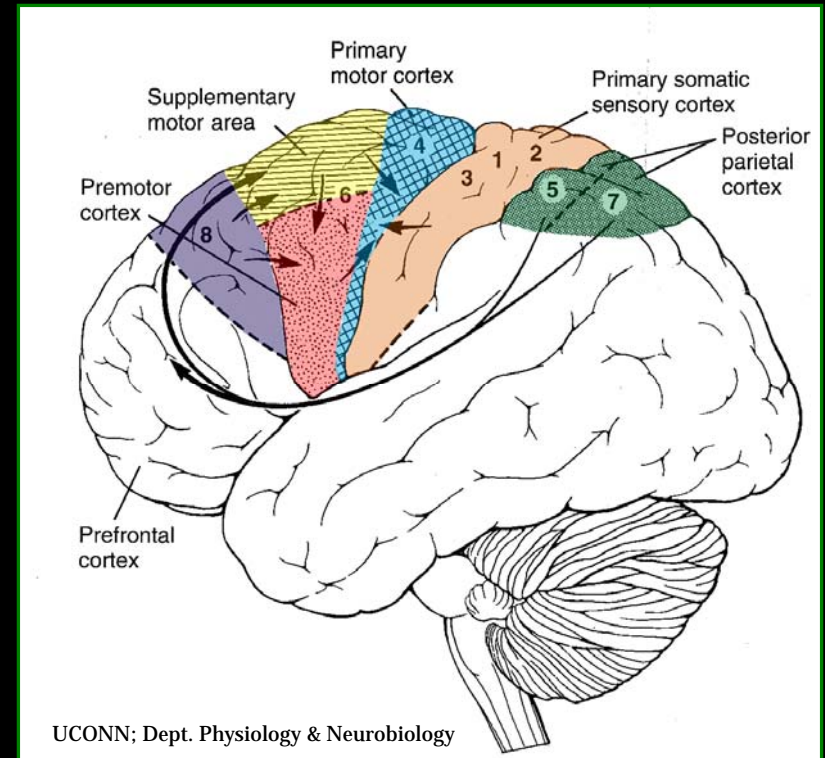
MOTOR

Objective: the localization of primary motor cortex and supplementary motor cortex

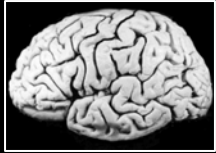

- The motor homunculus (left) is a visual depiction of the association between different body parts and the cortical area in primary motor cortex that is controlling them.

- In the frontal lobe (right), along the central sulcus is the primary motor cortex, important in voluntary movement.
- Adjacent to it are higher order motor areas, supplementary and premotor cortex, which are involved in planning a movement.



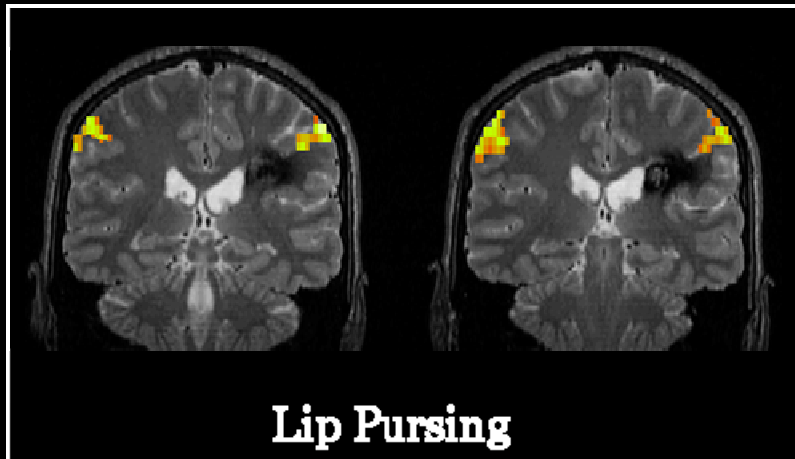
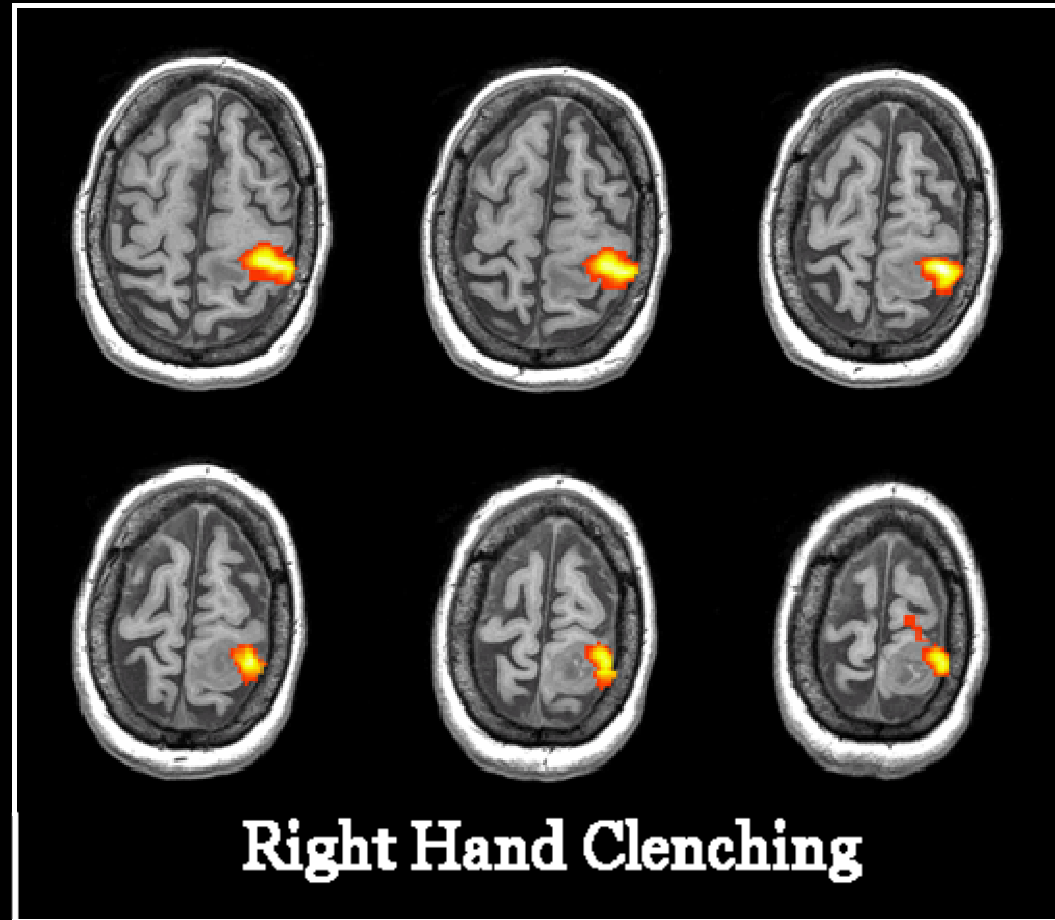
FUNCTIONAL MRI



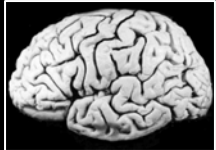MOTOR

Motor Tasks:

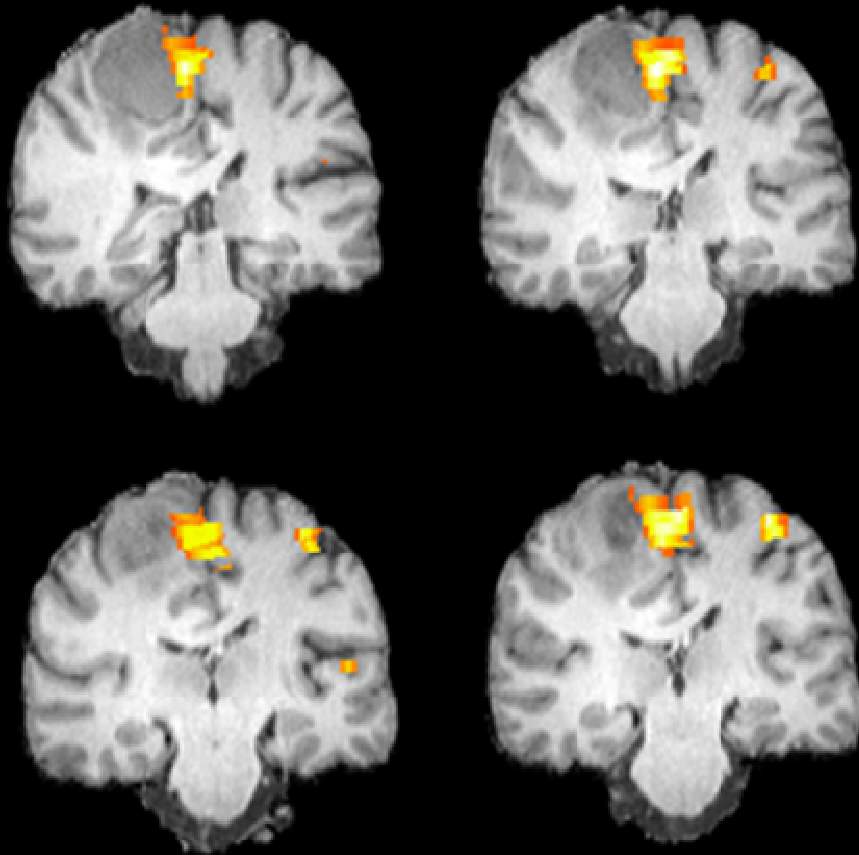
- all tasks are self-paced, block designs of alternating 20 second intervals of task and rest
- Left or Right Hand Clenching
- Left or Right Toe Wiggling
- Left or Right Hand Finger Tapping
- Face: Lip Pursing



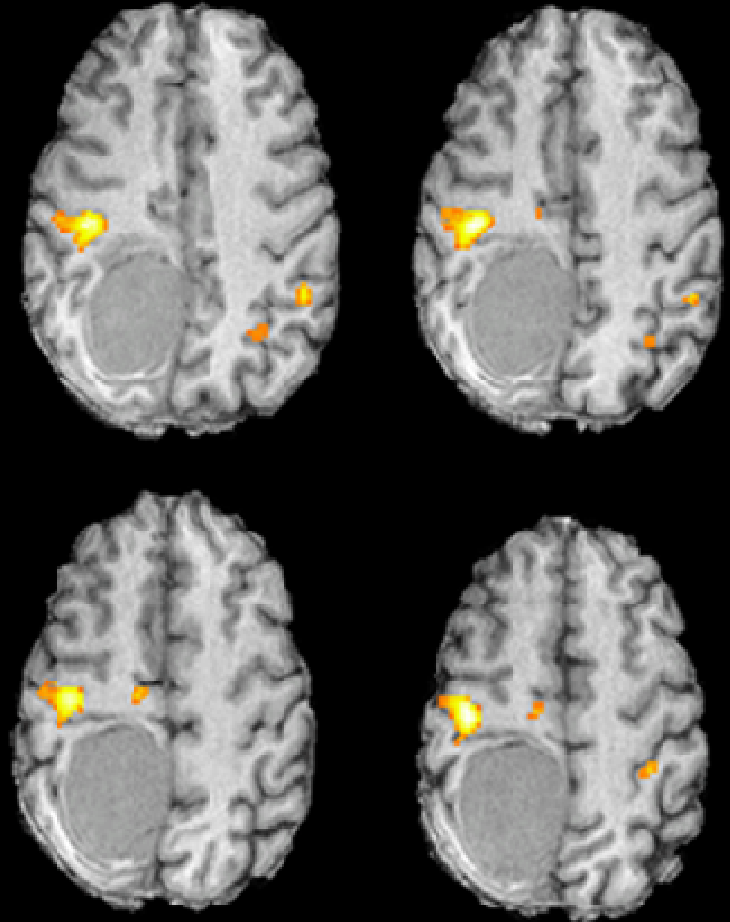
FUNCTIONAL MRI



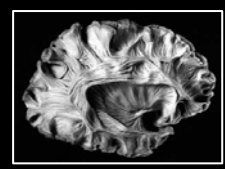
MOTOR



Left Foot Toe Wiggle



Left Hand Finger Tapping

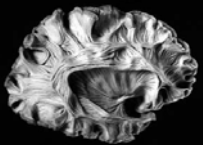


DIFFUSION TENSOR IMAGING

DIFFUSION WEIGHTED IMAGING

- Diffusion weighted imaging provides information about the structural integrity of axonal white matter by measuring the molecular diffusion of water in brain tissue.
- Diffusion is influenced by myelin density, the number of myelinated fibers, and axonal membrane integrity, and is therefore an indirect measure of the structural integrity of axonal white matter.

Beaulieu, *NMR Biomed*, 2002



DIFFUSION TENSOR IMAGING

WHITE MATTER STRUCTURES OF CLINICAL INTEREST

Association Fibers
interconnect cortical areas in each hemisphere

Superior Longitudinal Fasciculus

- a massive bundle that runs along the superior margin of the insula, connecting the frontal lobe cortex to the parietal, temporal, and occipital lobe cortices

Inferior Longitudinal Fasciculus

- connects temporal and occipital lobe cortices
- traverses the entire length of the temporal lobe

Fronto-Occipital Fasciculus

- connects the occipital and frontal lobes
- extends along the inferolateral edge of the claustrum, below the insula

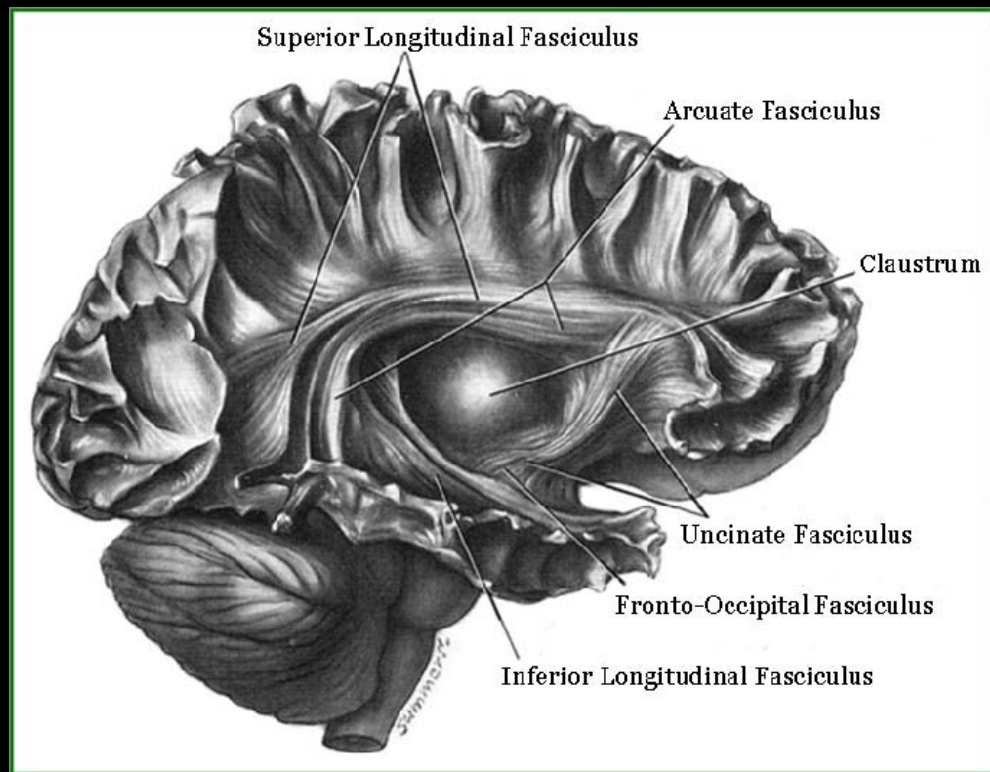
Arcuate Fasciculus

- connects the posterior part of the temporoparietal junction with the frontal cortex

Uncinate Fasciculus

- wraps around the lateral fissure to connect the orbital and inferior frontal gyri of the frontal lobe to the anterior temporal lobe

Jellison, AJNR, 2004



Cingulum

- runs immediately dorsal to the corpus callosum and along the ventral face of the hippocampus
- carries afferent connections from the cingulate gyrus to the entorhinal cortex

Mori, MRI Atlas of Human White Matter, 2005

DIFFUSION TENSOR IMAGING

WHITE MATTER STRUCTURES OF CLINICAL INTEREST

Projection Fibers

interconnect cortical areas with deep nuclei, brain stem, cerebellum, and spinal cord

Corticospinal Tract

(pyramidal tract)

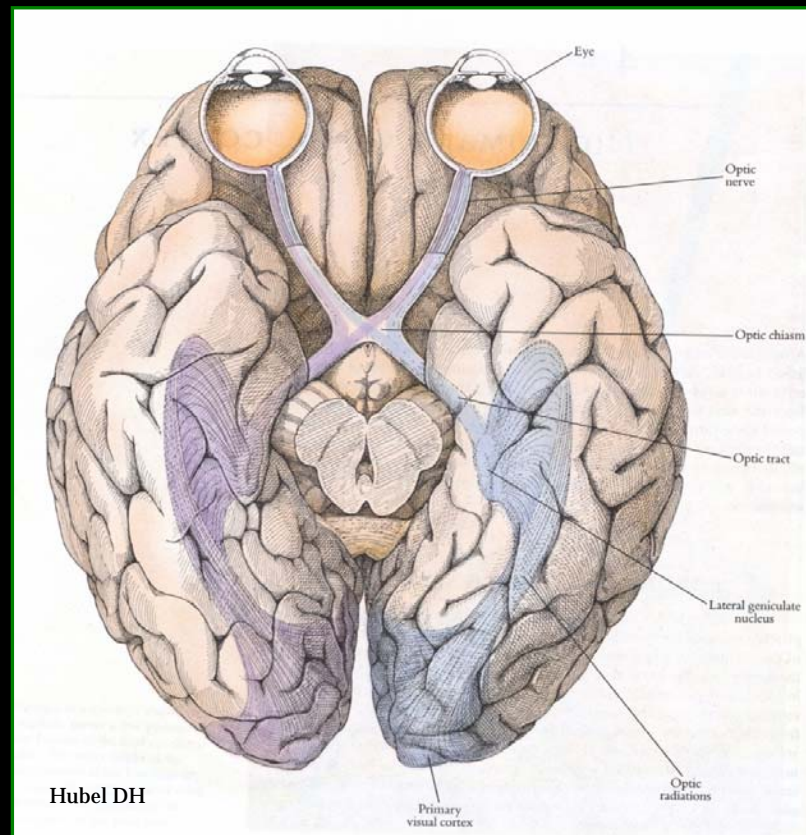
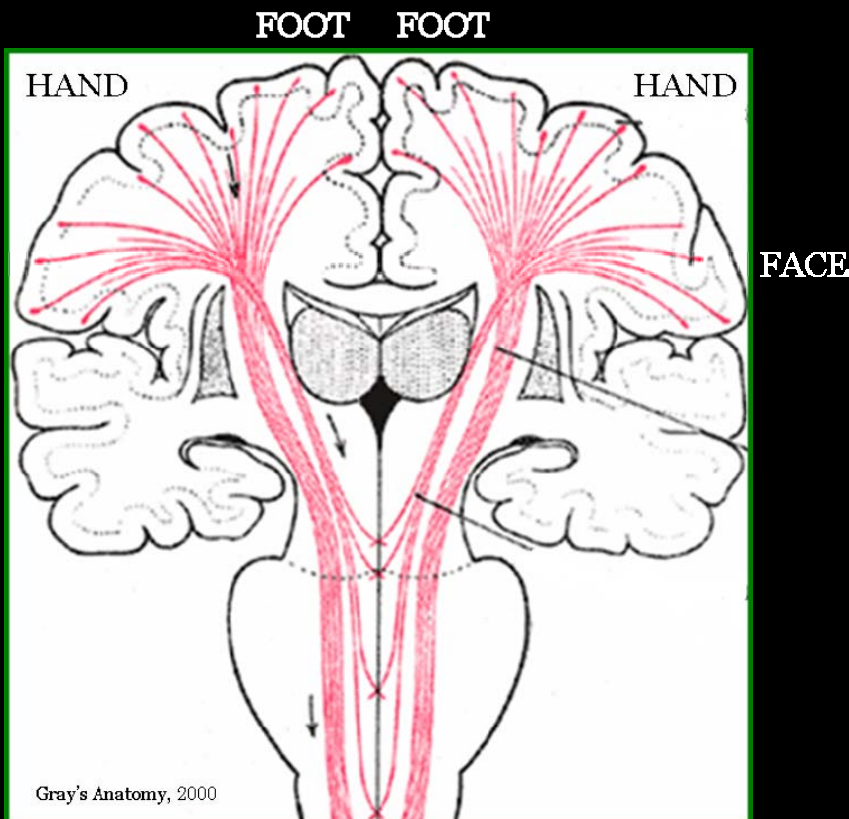
- major efferent projection fibers that connect motor cortex to the brain stem and spinal cord

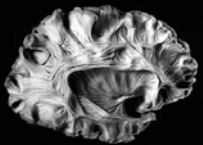
Jellison, *AJNR*, 2004

Optic Radiation-Meyer's Loop

(geniculocalcarine tract)

- connects the lateral geniculate nucleus to occipital (primary visual) cortex





DIFFUSION TENSOR IMAGING

WHITE MATTER STRUCTURES OF CLINICAL INTEREST

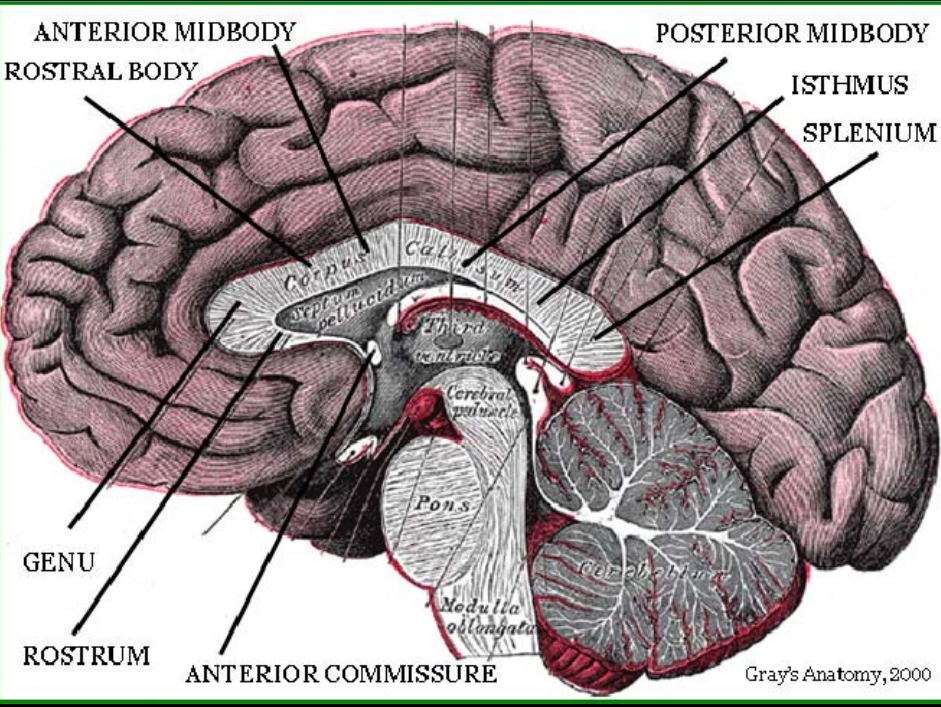
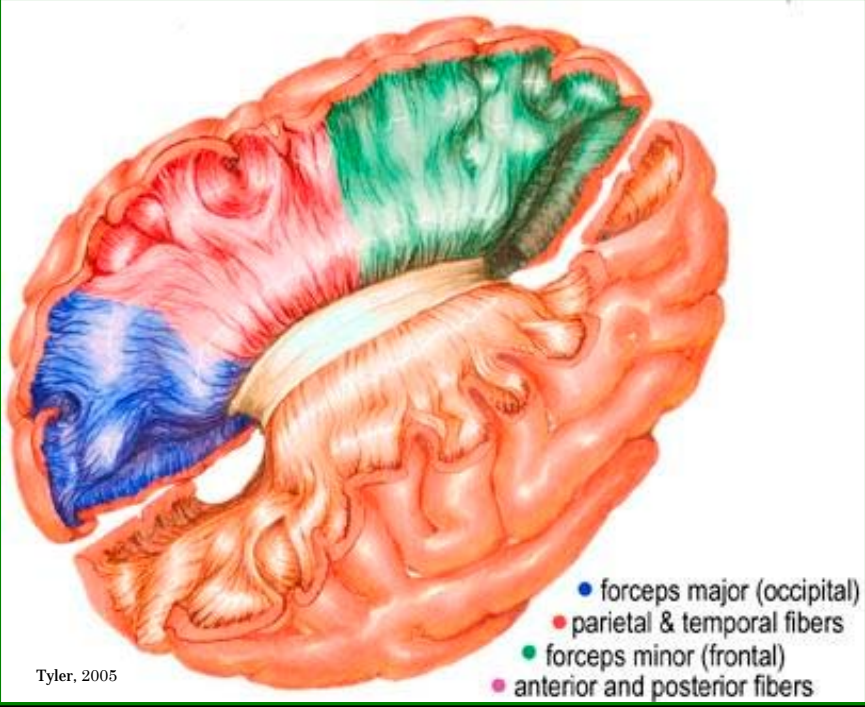
Commissural Fibers

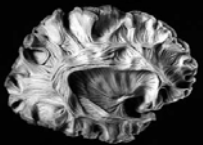
interconnect similar cortical areas between opposite hemispheres

Corpus Callosum

- the largest white matter fiber bundle, the corpus callosum is a massive accumulation of fibers connecting corresponding areas of cortex between the hemispheres
- callosal fibers conjoin with association and projection fibers, creating fiber crossings

Jellison, AJNR, 2004





DIFFUSION TENSOR IMAGING

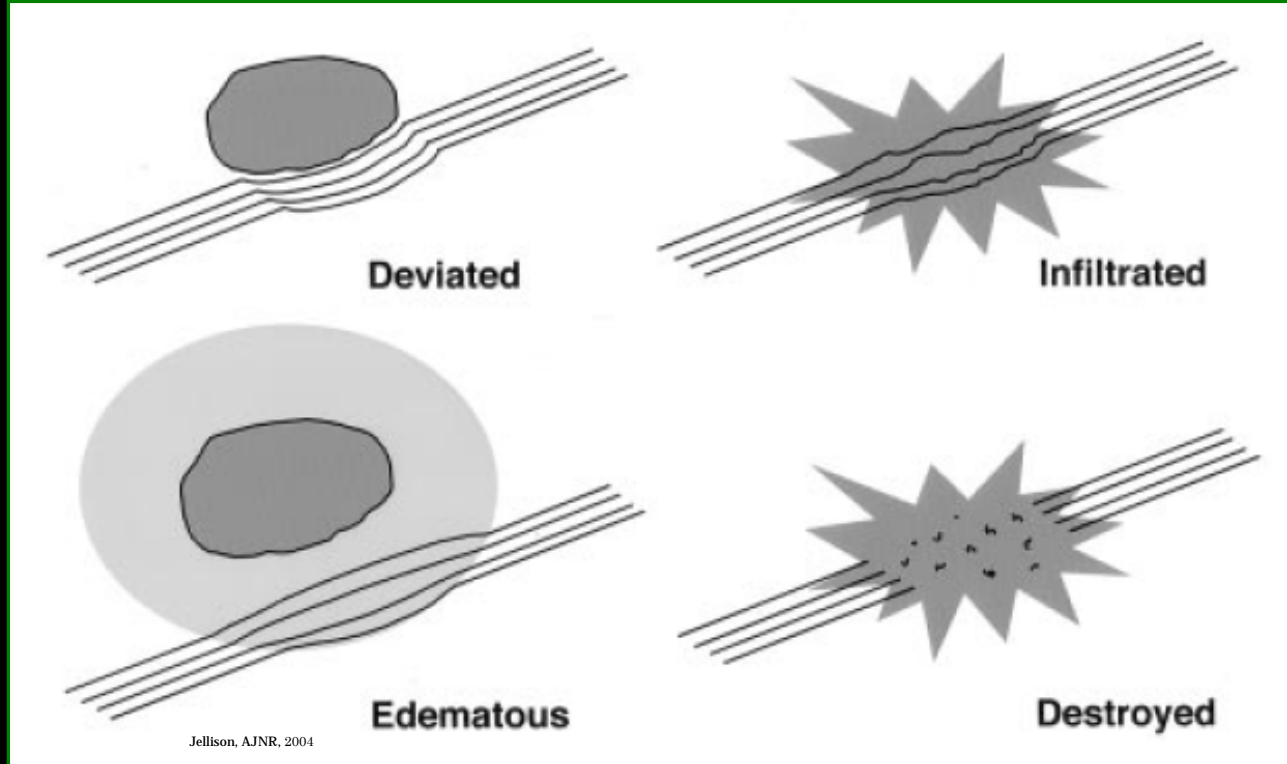
WHITE MATTER PATHOLOGY AND SURGICAL PLANNING

DTI can provide visually appreciable information about white matter pathology that cannot be seen in conventional MRI, as most radiological diagnosis is based on visual inspection of images.

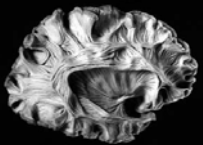
Mori, *Introduction to Diffusion Tensor Imaging*, 2007

- White matter tracts displaced by a tumor can retain their anisotropy and remain identifiable in their new location or orientation on a fiber orientation color map.
- Edematous or tumor-infiltrated tracts may lose anisotropy, but still retain enough orientation organization to remain identifiable on a color map.
- Or white matter tracts might be destroyed or disrupted to the point where directional and anisotropy organization is lost completely.

Jellison, *AJNR*, 2004



Jellison, *AJNR*, 2004

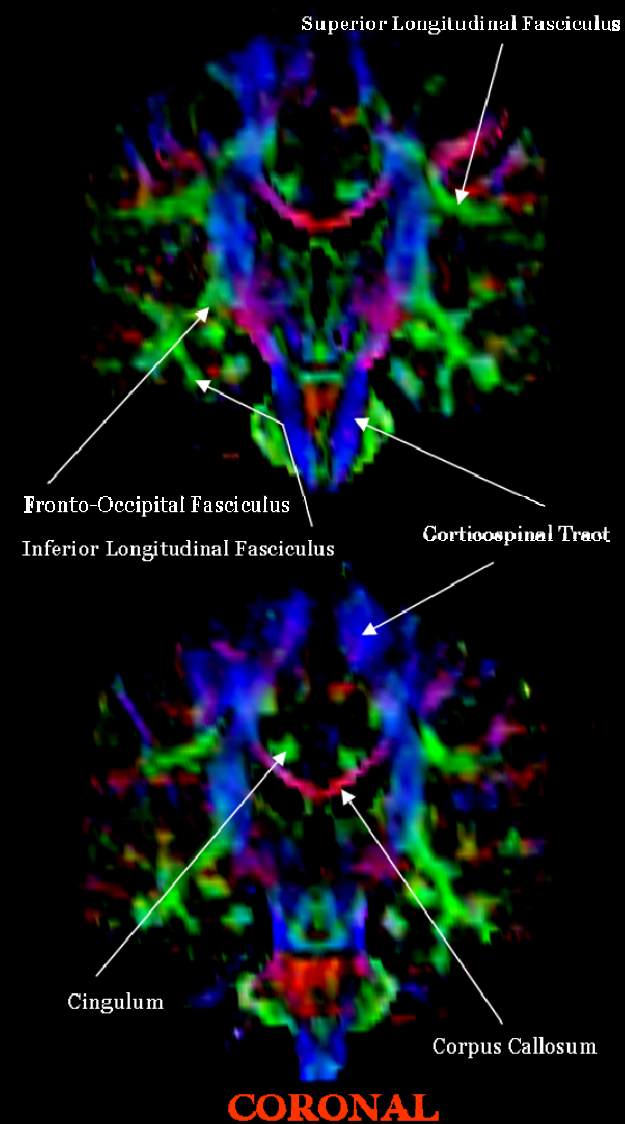
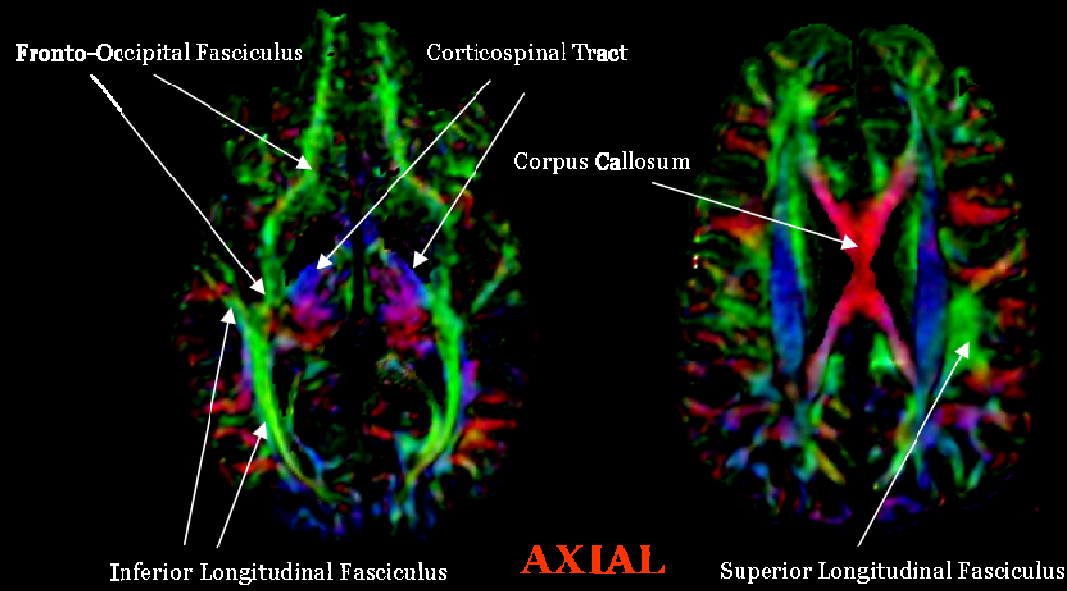
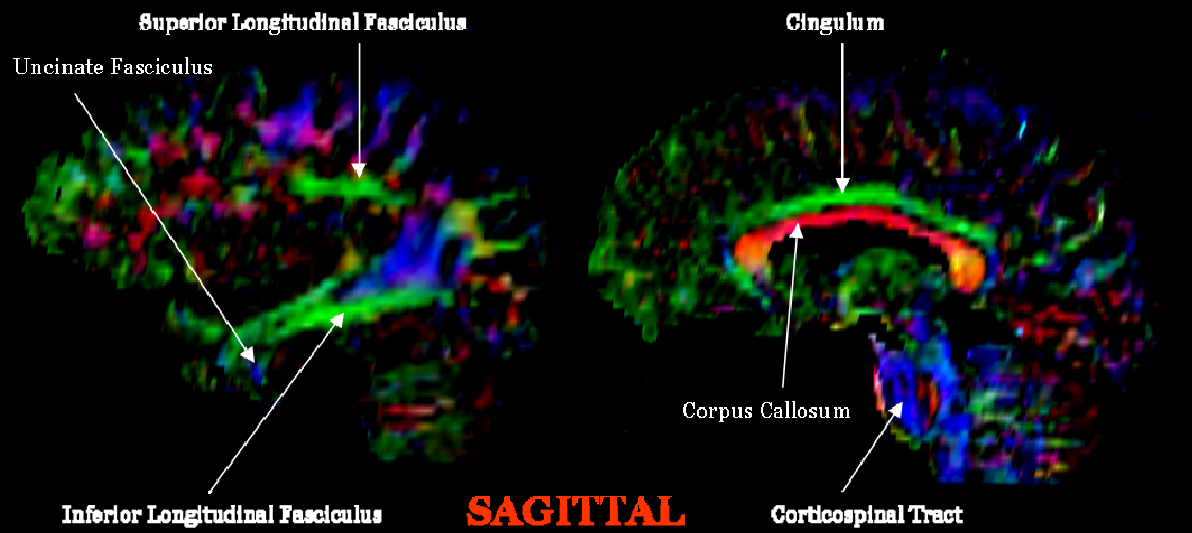


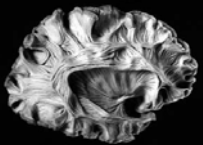
DIFFUSION TENSOR IMAGING

FIBER ORIENTATION MAPS

- Color-coded, fiber orientation maps provide rich anatomical, not physiological, white matter information.

Mori, Introduction to Diffusion Tensor Imaging, 2007



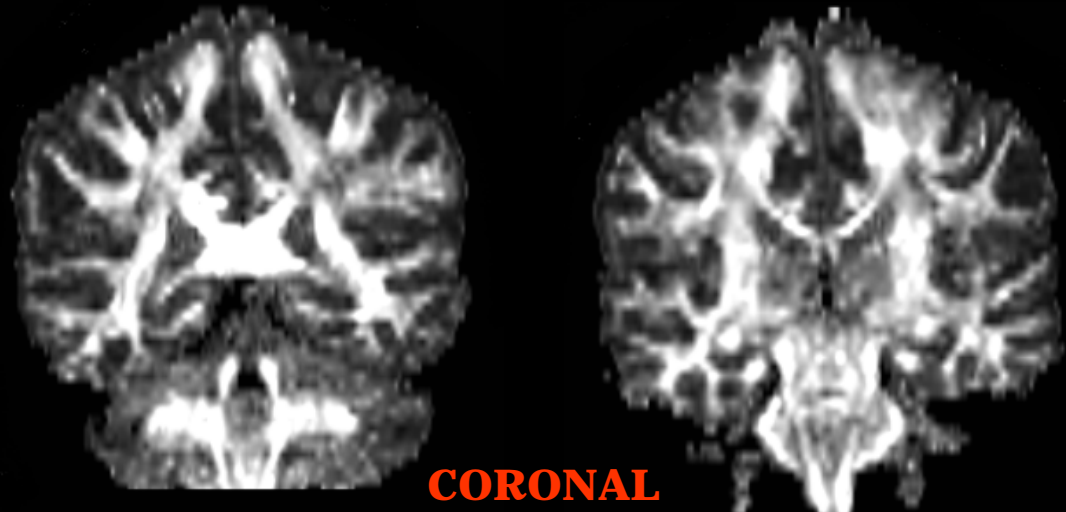
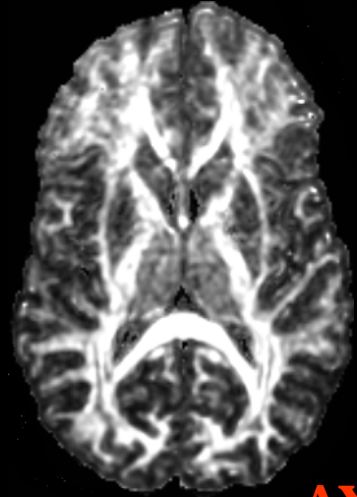
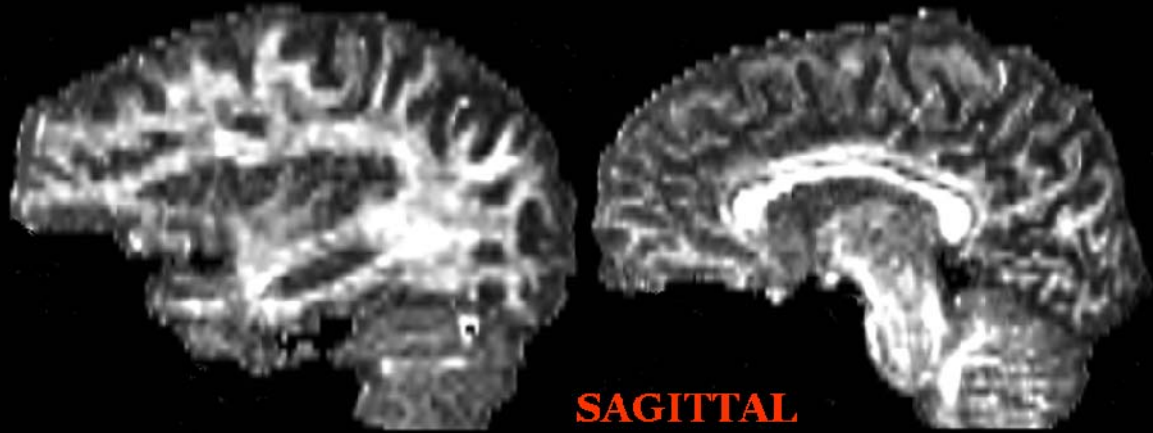


DIFFUSION TENSOR IMAGING

SCALAR MAPS (FRACTIONAL ANISOTROPY)

Fractional Anisotropy (FA) is a scalar measure of the degree of anisotropy in a given voxel. Anisotropy values are high in white matter, due to the presence of myelin. Anisotropy values are often used to assess white matter integrity.

FA values are between 0 (isotropic diffusion) and 1 (anisotropic diffusion).

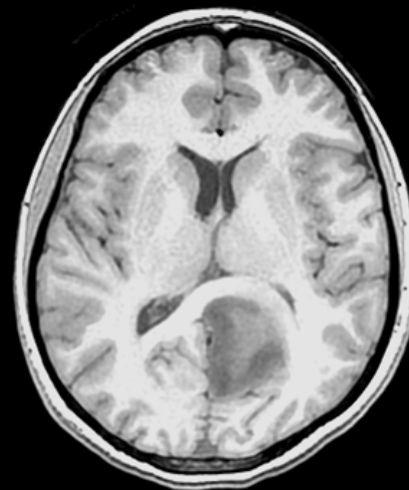


DIFFUSION TENSOR IMAGING

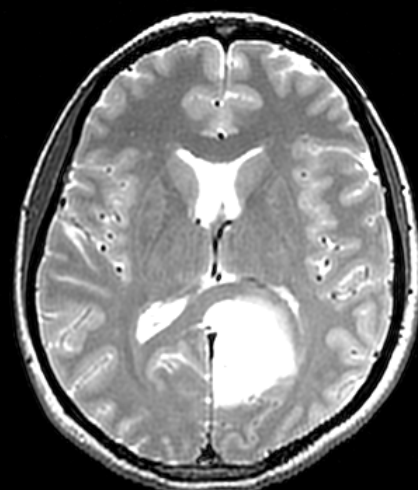WHITE MATTER PATHOLOGY AND SURGICAL PLANNING

White matter tracts of the corpus callosum and left corticospinal tract are deviated anteriorly and laterally by a low-grade glioma, WHO Grade II (seen clearly in the T1 and T2 images). The white matter tracts retain their normal anisotropy, and therefore are easily identified in the fiber orientation color map and the FA image. The trace image depicts the edema surrounding the lesion.

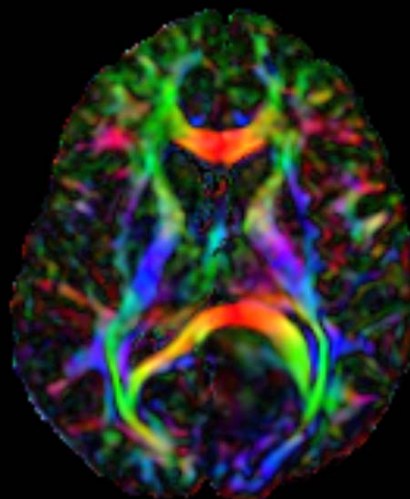
Note that the blue color of the corticospinal tract changes to a light shade of red, and the red color of the lateral portions of the corpus callosum changes to a shade of yellow as these structures deviate laterally.



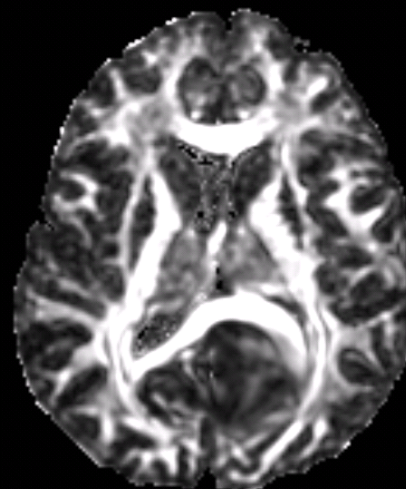
T1



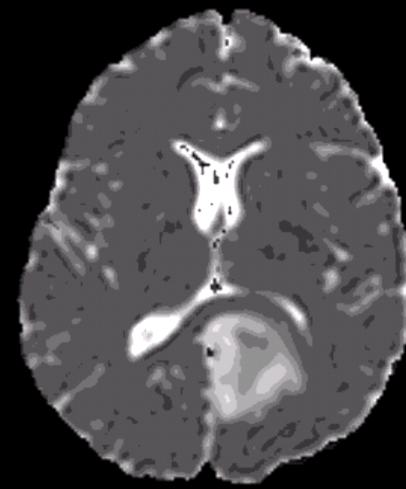
T2



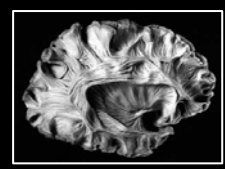
ORIENTATION



FA



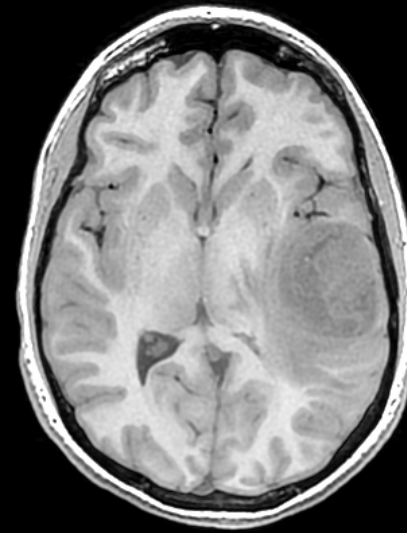
TRACE



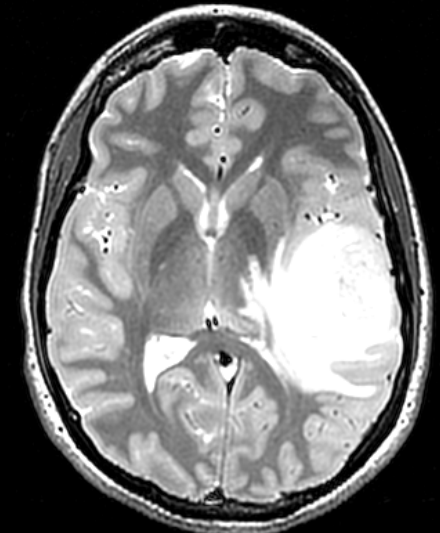
DIFFUSION TENSOR IMAGING

WHITE MATTER PATHOLOGY AND SURGICAL PLANNING

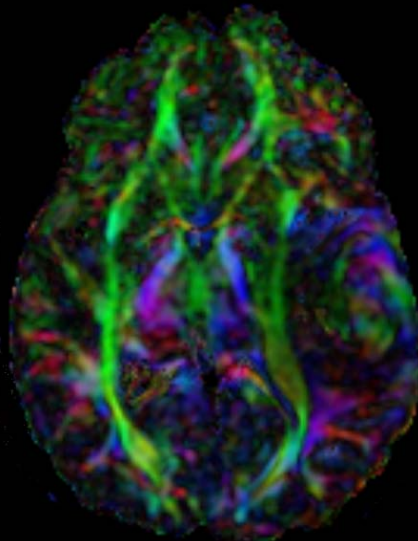
White matter tracts of the fronto-occipital fasciculus are damaged and deviated medially by a high-grade glioblastoma, WHO Grade IV. The infiltrating glioblastoma is characterized by both profoundly diminished anisotropy in the FA map, and abnormal color on the directional map for the fronto-occipital fasciculus, suggesting that the disruption of white matter fiber tract organization is severe and complex.



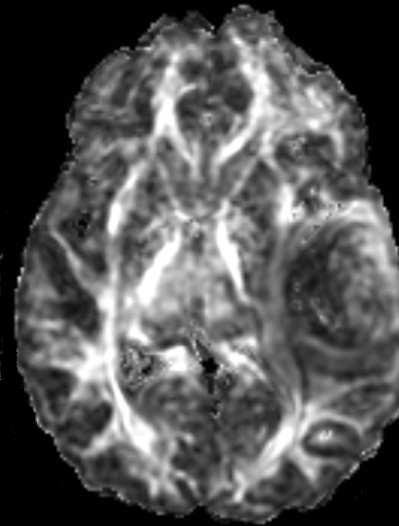
T1



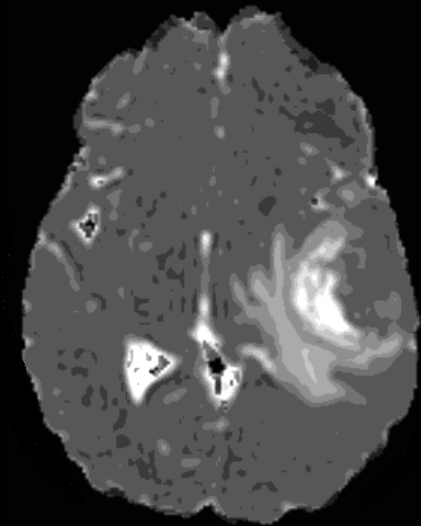
T2



ORIENTATION



FA



TRACE