

# *DTI Atlas Building – Santa Fe*

---

- Casey Goodlett, Guido Gerig

# Overview

- ◆ Algorithm [1]
- ◆ Inputs
- ◆ Geometry of Atlas Fibers
- ◆ Diffusion Statistics
- ◆ Results, Conclusions, and Thoughts

# *Inputs*

- ◆ Larger data set
- ◆ Image Data
  - ◆ Scanner resolution
  - ◆ no distortion correction

# *Preprocessing*

- ◆ Tensor Estimation – DTIPProcess from NeuroLib
  - ◆ Weighted Least Squares (3 iterations)
  - ◆ Background Threshold 350
  - ◆ Time: 3-4 minutes per
- ◆ FA/MD/Color FA computation using DTIPProcess
- ◆ Maximum eigenvalue image (sigma = 4.5 mm)
- ◆ ~minutes per-image, Xeon dual-core w/ 2GB (Memory is limiting factor for processing)

# Registration

- ◆ Average baseline image registered to T2 atlas
  - ◆ RView
  - ◆ Cross-Correlation (same modality different intensity ranges)
  - ◆ 3 resolution levels
- ◆ Affine registration used as initialization for fluid registration (Joshi, Davis) [2]
  - ◆ Multi-resolution (3 levels)
  - ◆ Runs in ~15 minutes on 8 core machine 64 GB RAM

# *Fiber Tracking*

- ◆ Computed on atlas tensor image
- ◆ ROIs redrawn in atlas based on sample ROIs
  - ◆ InsightSNAP 1.5.4 with FA and/or Color FA images
  - ◆ Arcuate drawn based on Susumu Mori's atlas
- ◆ FiberTracking 2.3.1 used with default parameters

# *Collection of Diffusion Statistics*

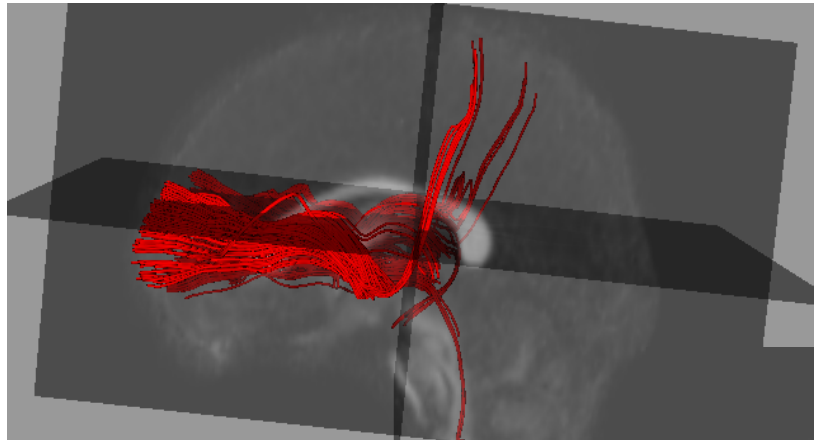
- ◆ FiberViewer 1.2.3 used for clustering/analysis
- ◆ Fiber process command line tool in DTIProcess
- ◆ For each point in atlas bundle lookup data from individual image
- ◆ For each bundle project collected data onto 1-d curve via arc-length parameterization. Median of data in cross-section
  - ◆ FA
  - ◆ MD

# *Analysis of Tract Statistics*

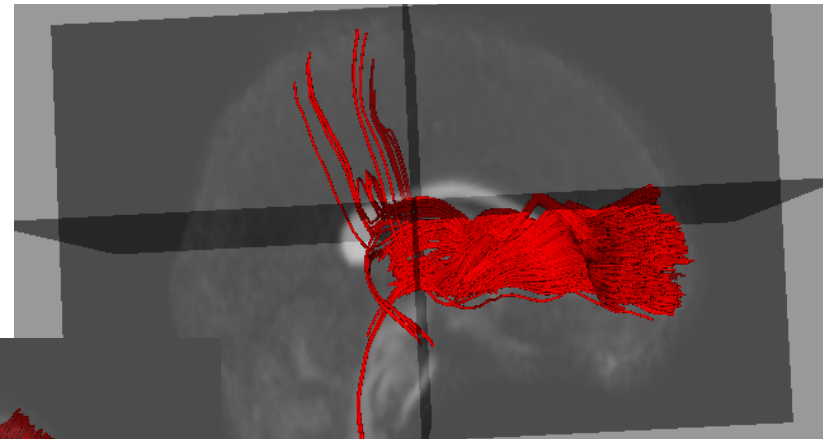
- ◆ FiberViewer used to reduce each individual fiber bundle to 1-d function (median statistic)
- ◆ Population (N images) collected into spreadsheet NxM (m == # of samples along tract)
- ◆ Analysis done using scipy, numpy
- ◆ Functional Data Analysis [3]
  - ◆ Smoothing
  - ◆ PCA
  - ◆ point-wise tests (multiple comparison correction)



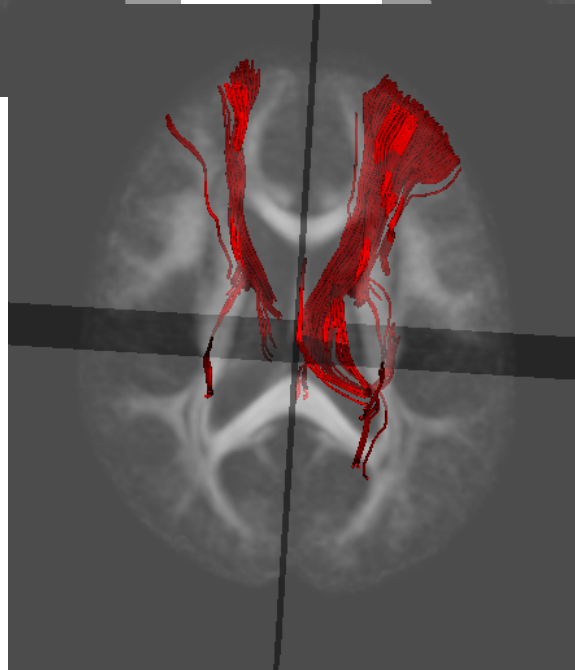
# *Internal Capsule*



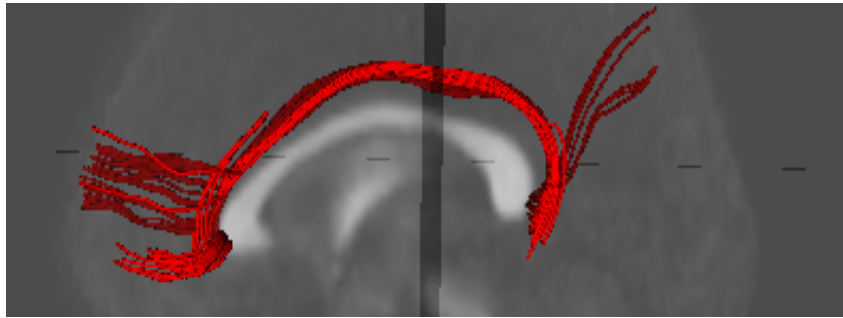
left



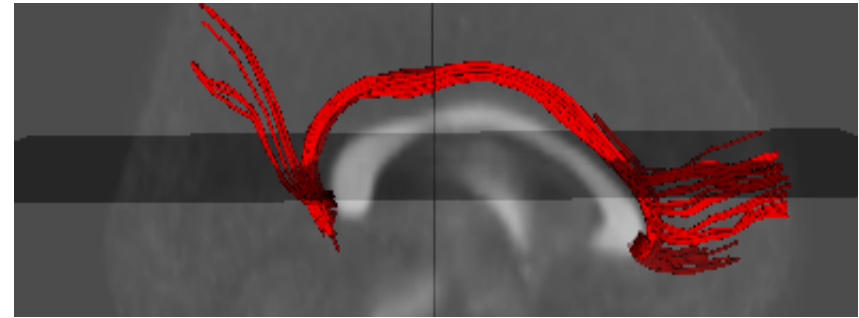
right



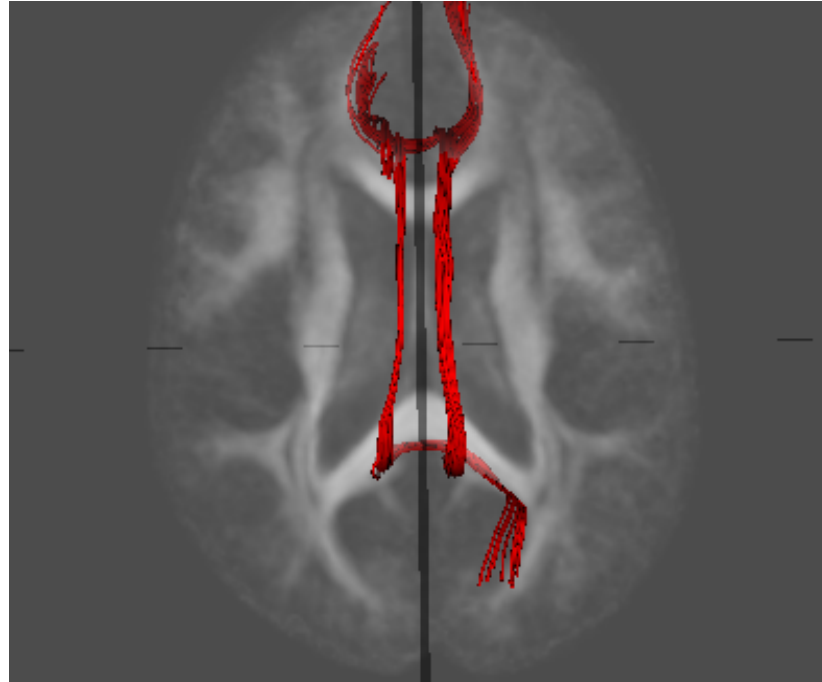
# *Cingulum*



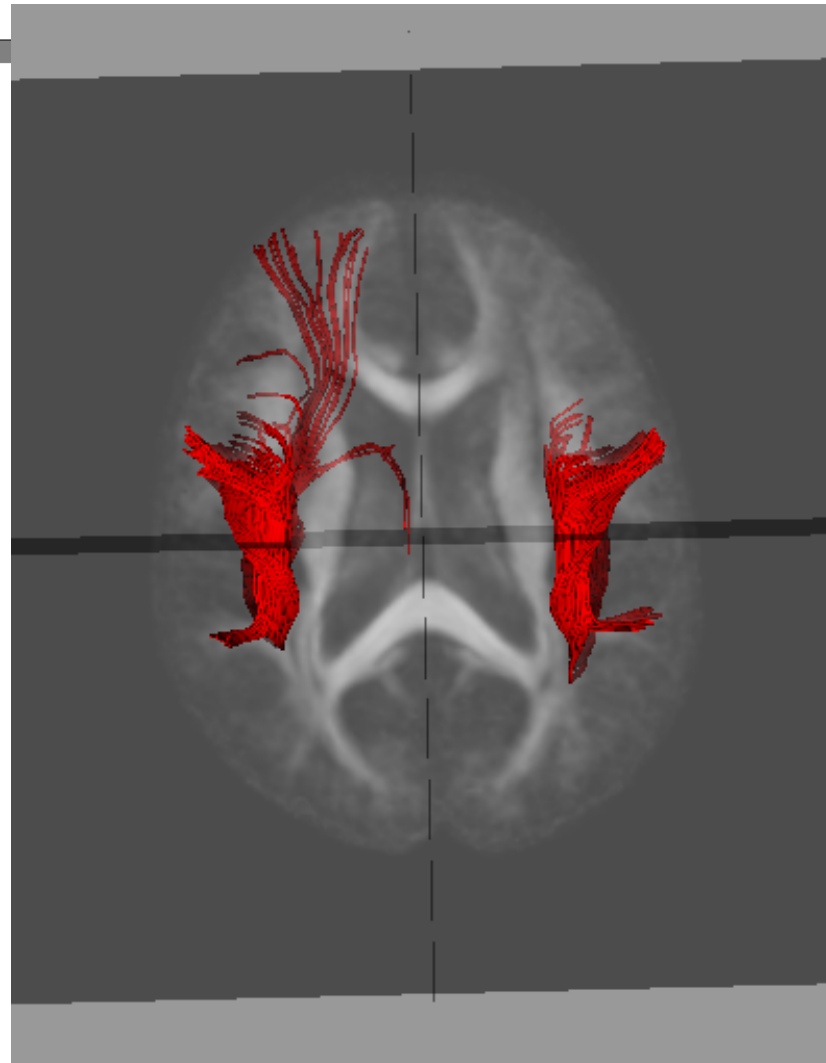
left



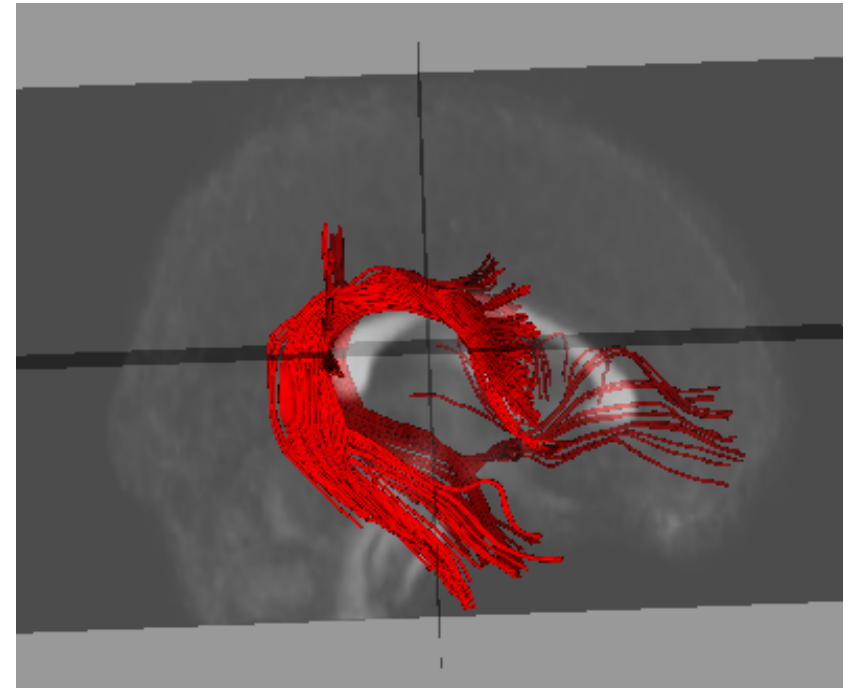
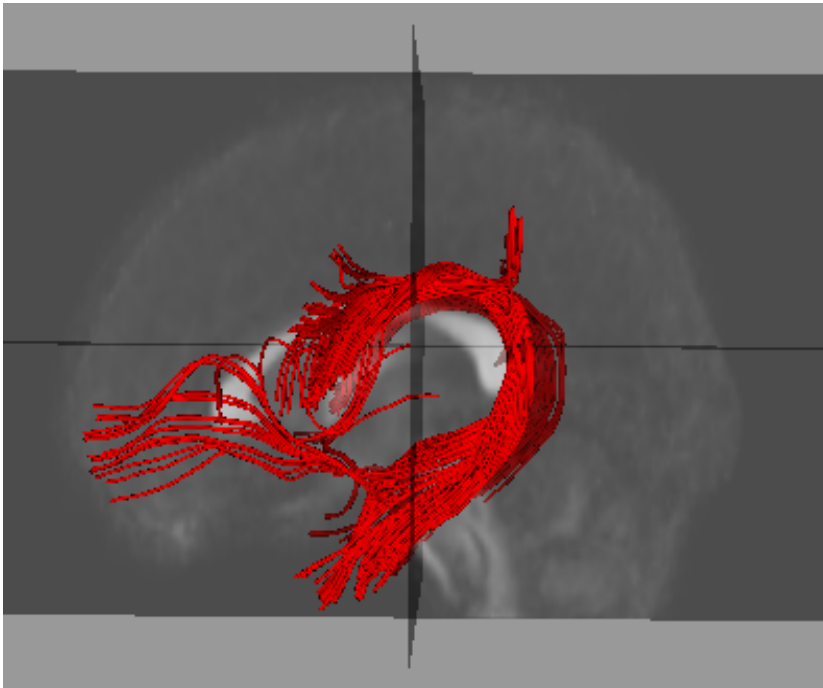
right



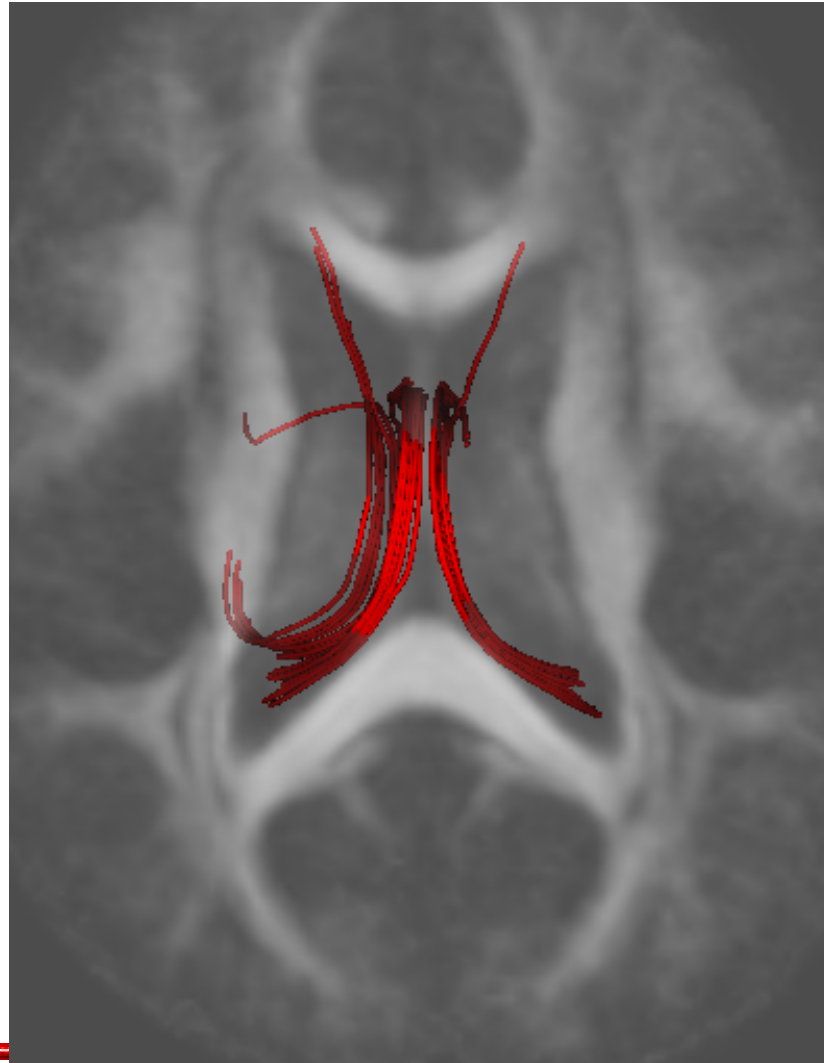
# *Arcuate*



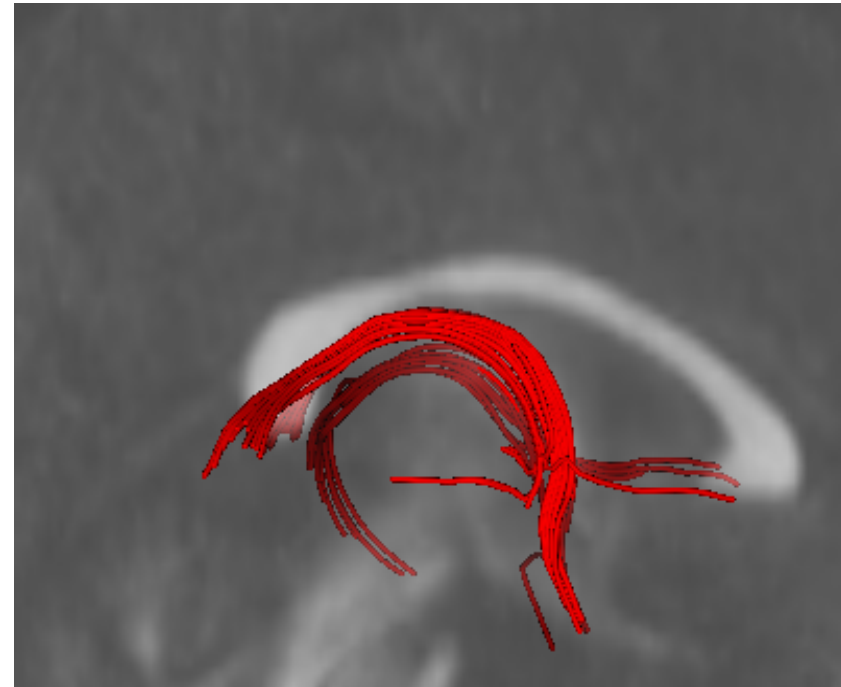
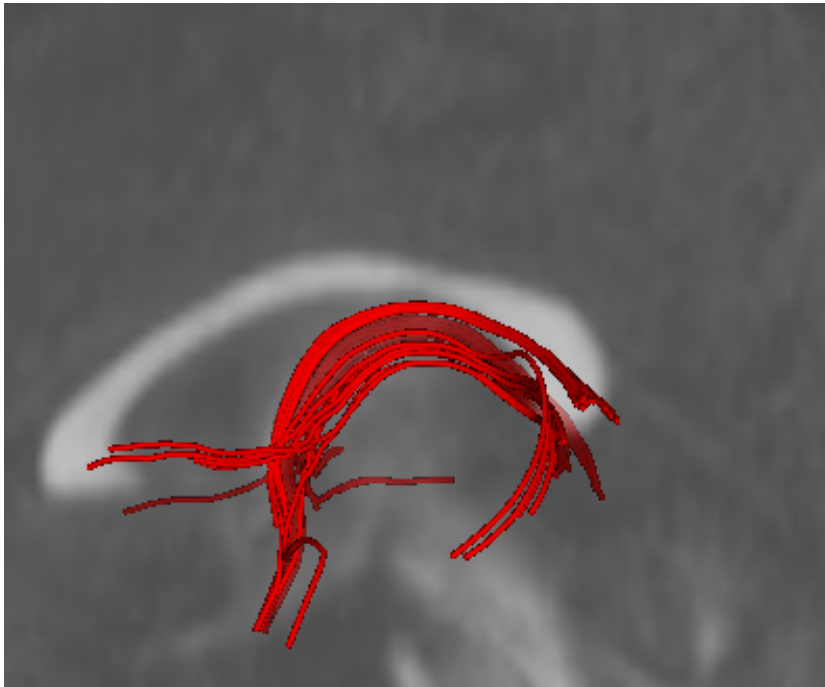
# *Arcuate*



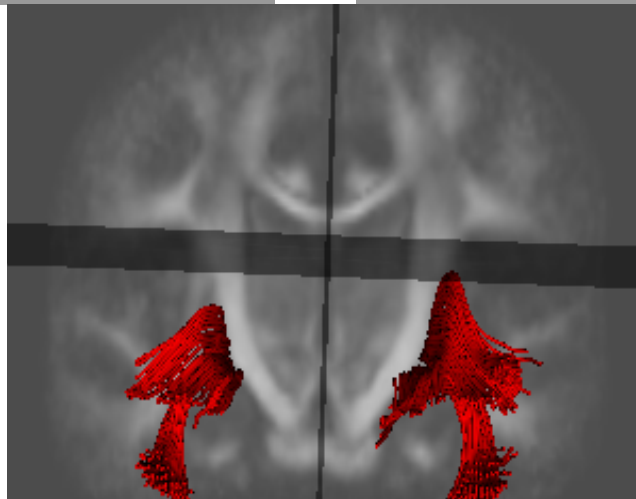
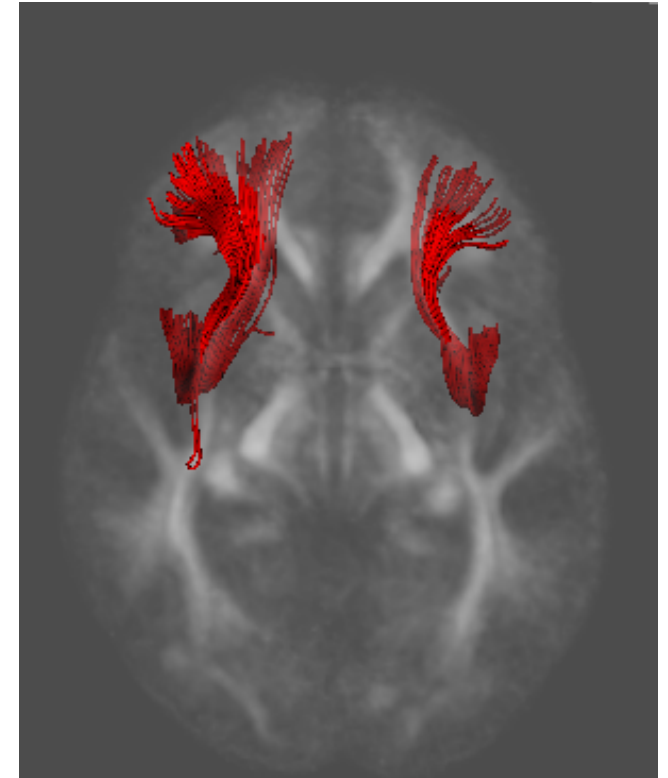
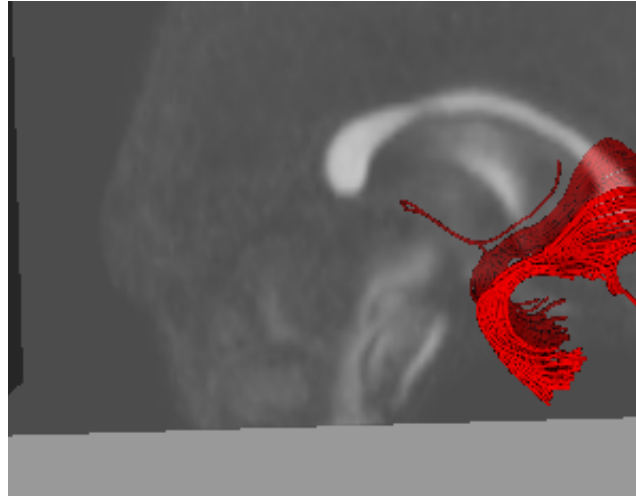
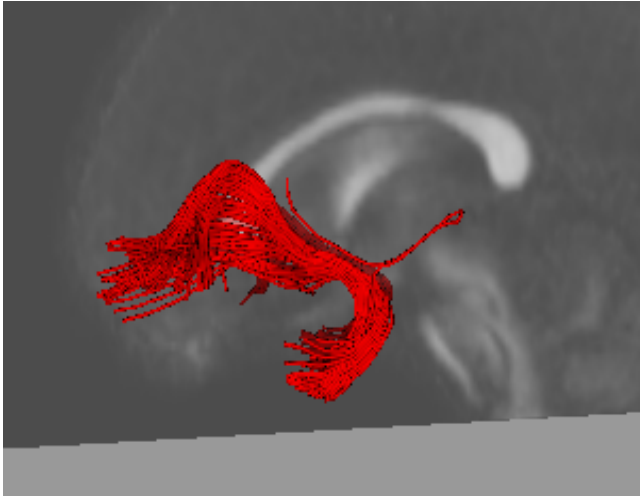
# *Fornix*



# *Fornix*

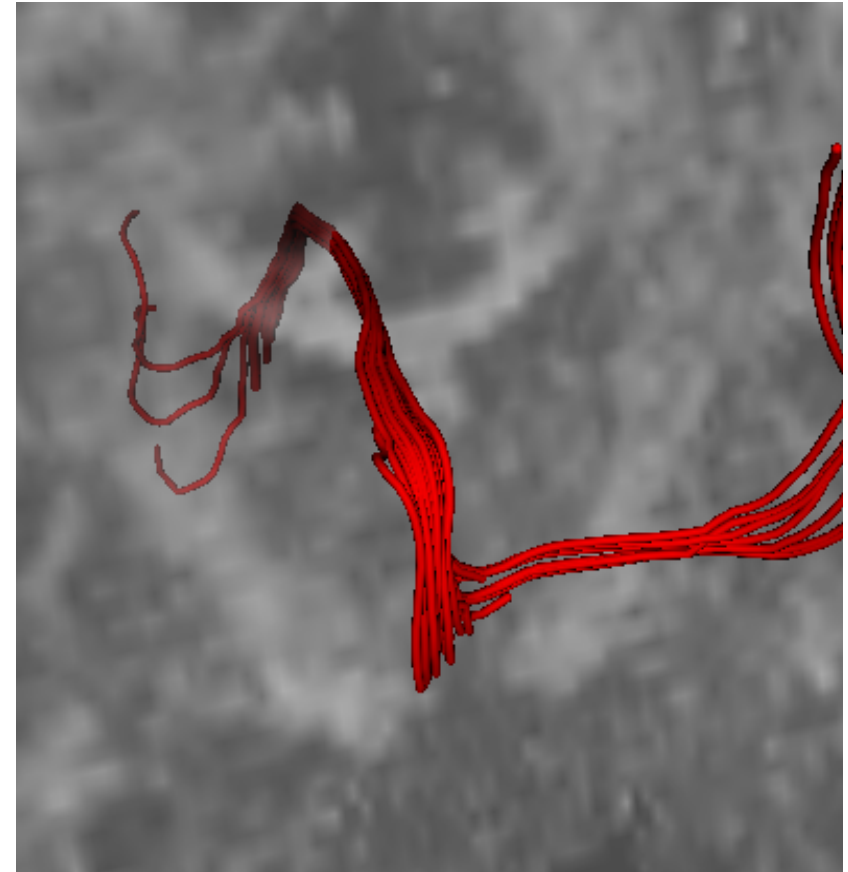
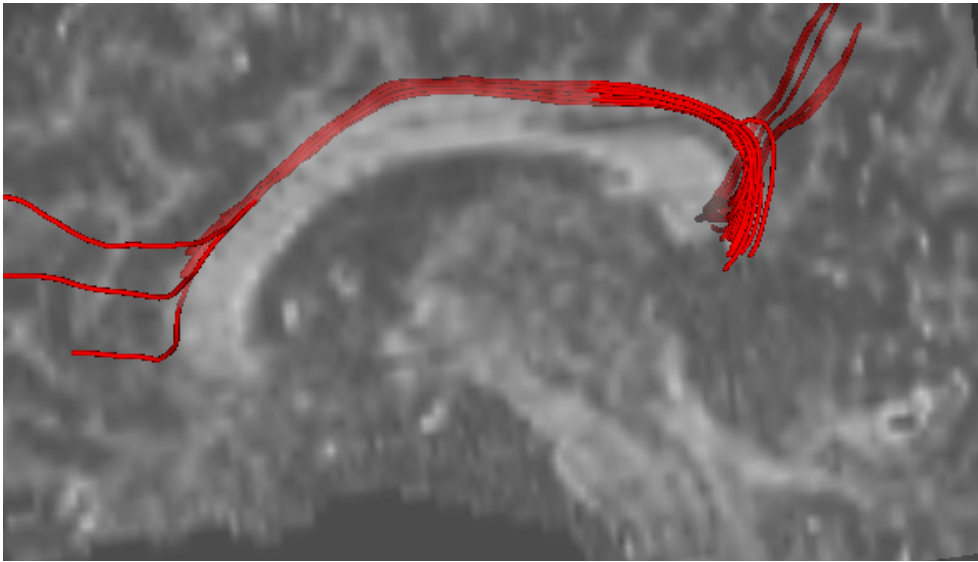


# *Uncinate*



# *Super(fast|imprecise) Quality Check of Atlas*

caseD00922

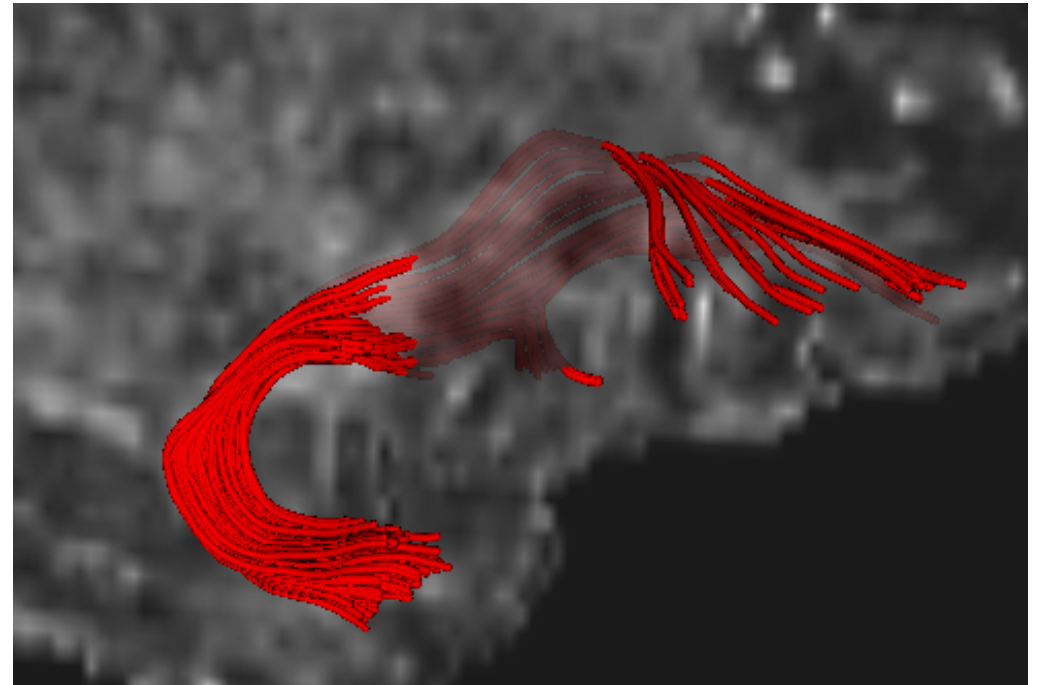



Top: Left cingulum bundle (Sagittal View)  
Right: Left cingulum bundle (Coronal View)



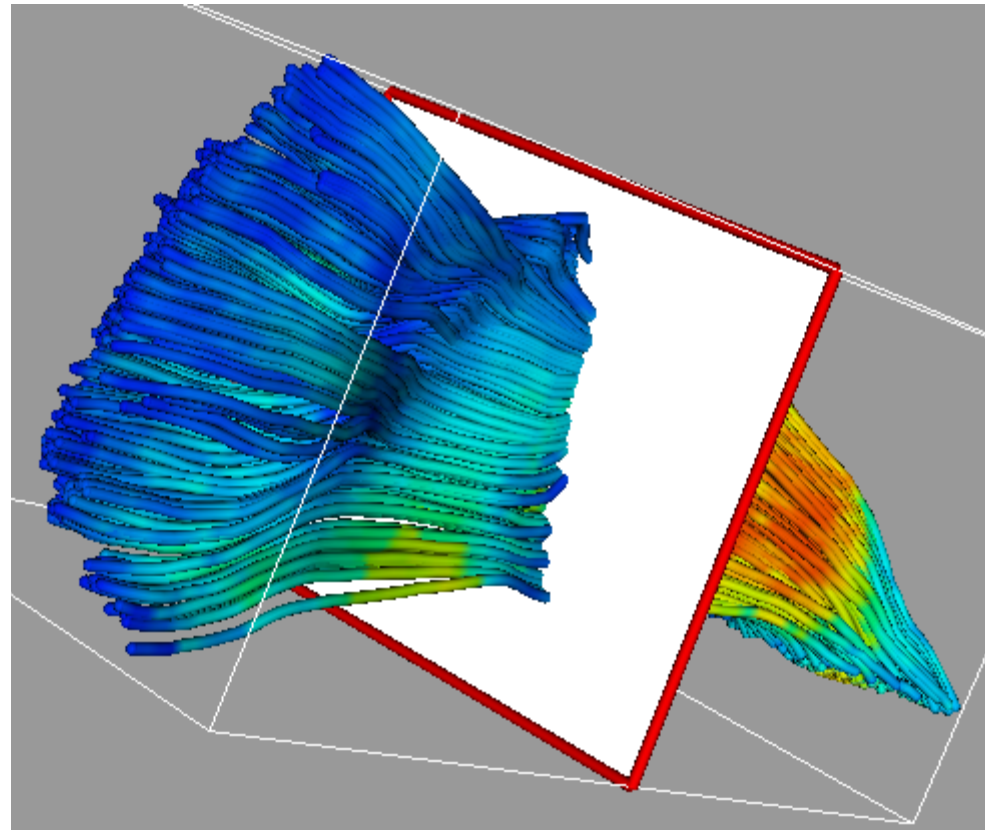
# *Super(fast|imprecise) Quality Check of Atlas*

caseD00939

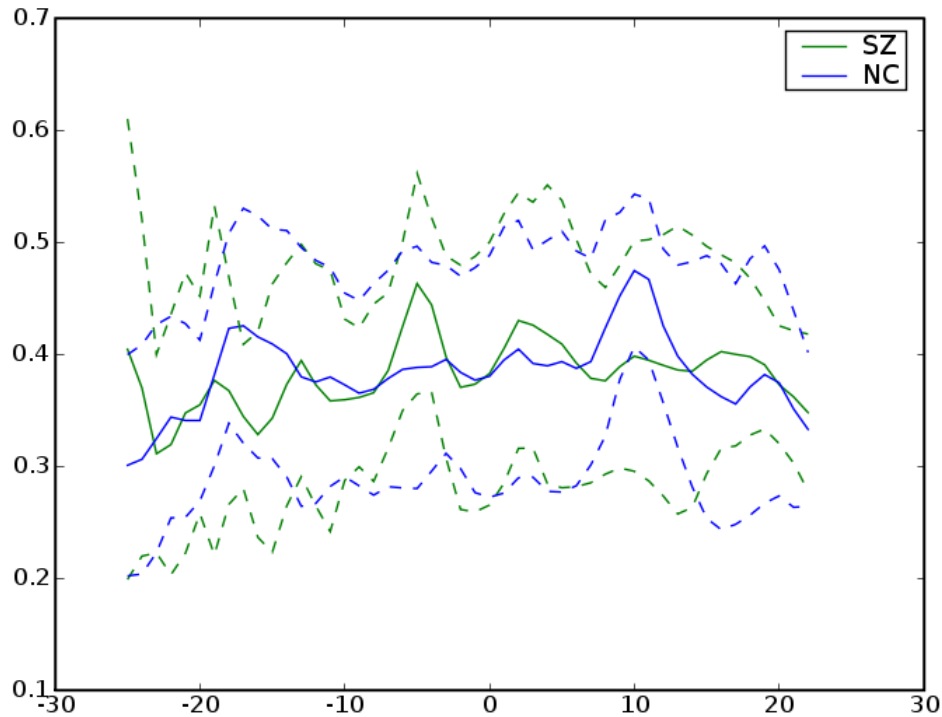


Left: Right Uncinate (from Anterior)  
Top: Right Uncinate (from Right)

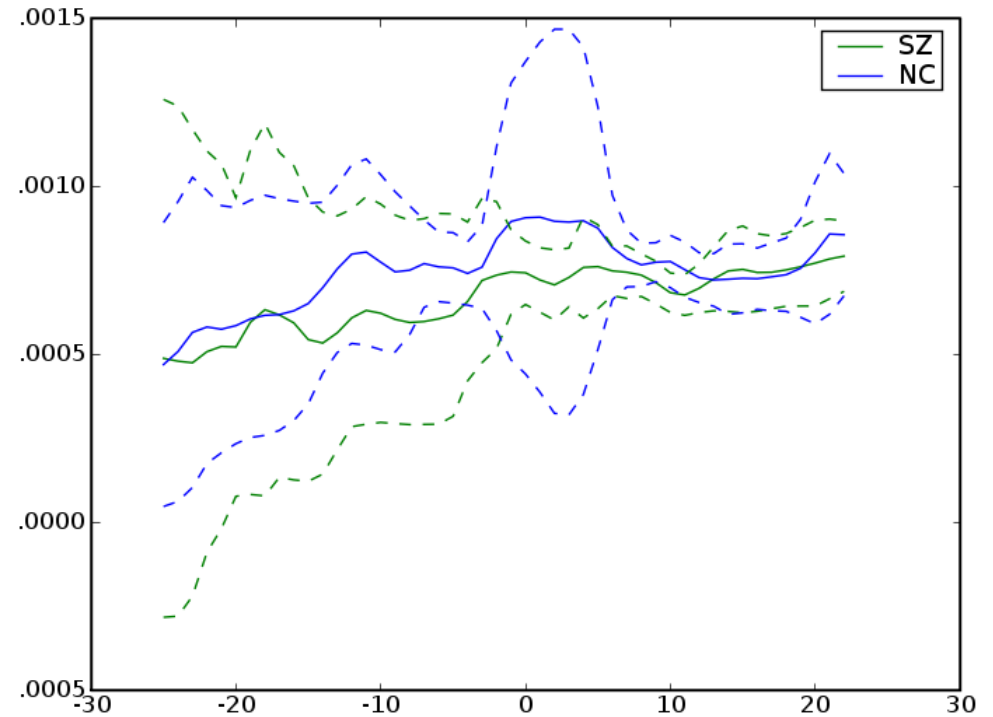
# *Left Internal Capsule*



# Left Internal Capsule

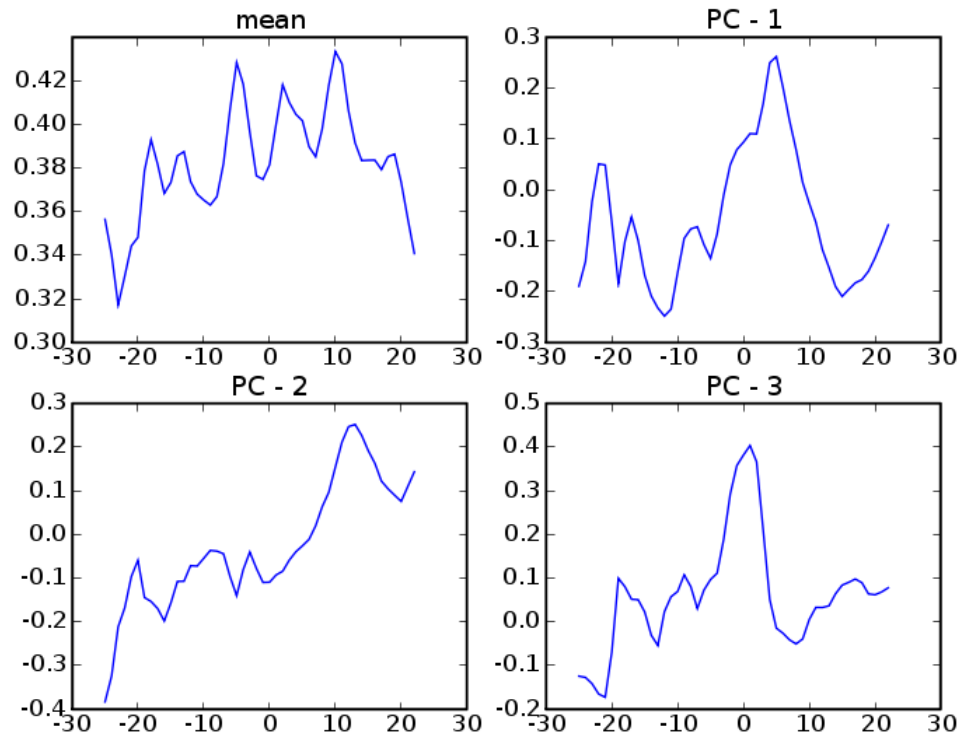


FA

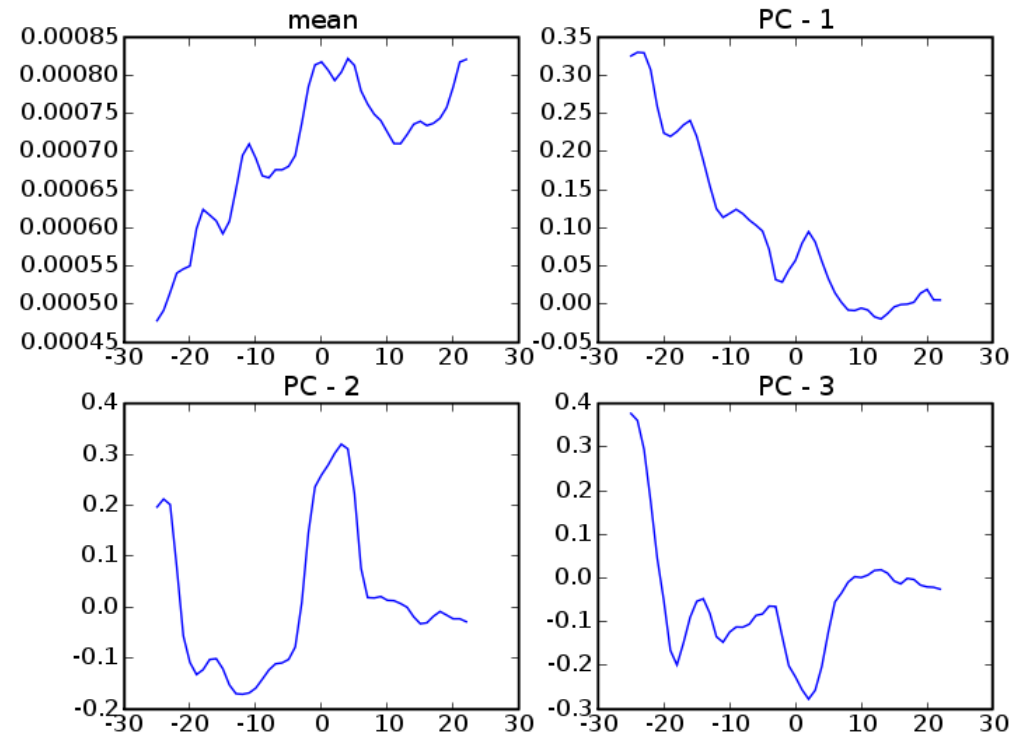


MD

# Left Internal Capsule

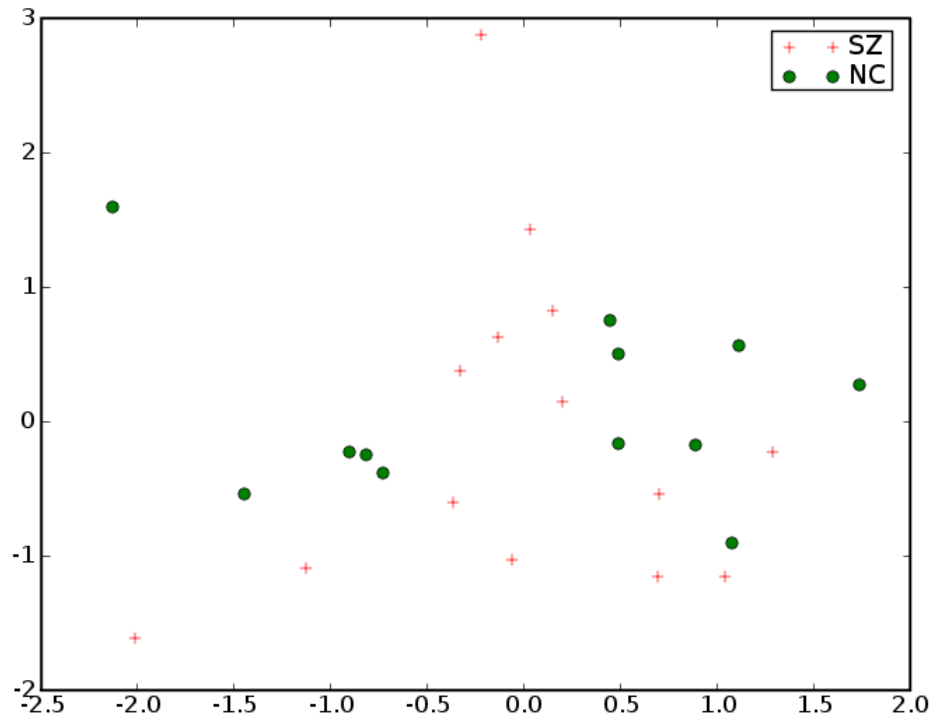


FA

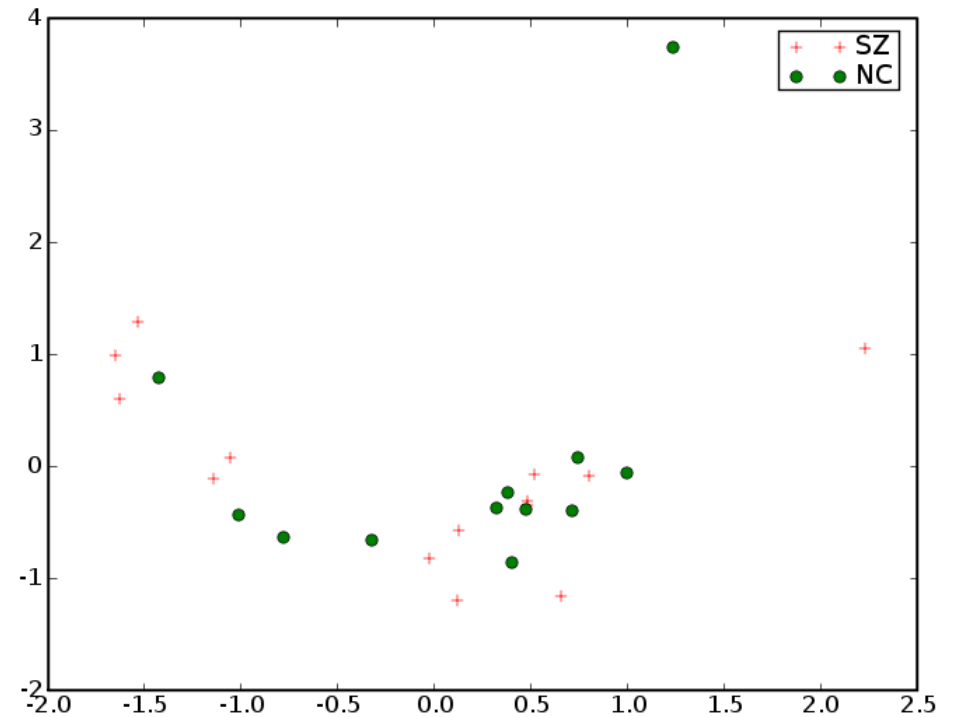


MD

# Left Internal Capsule




FA

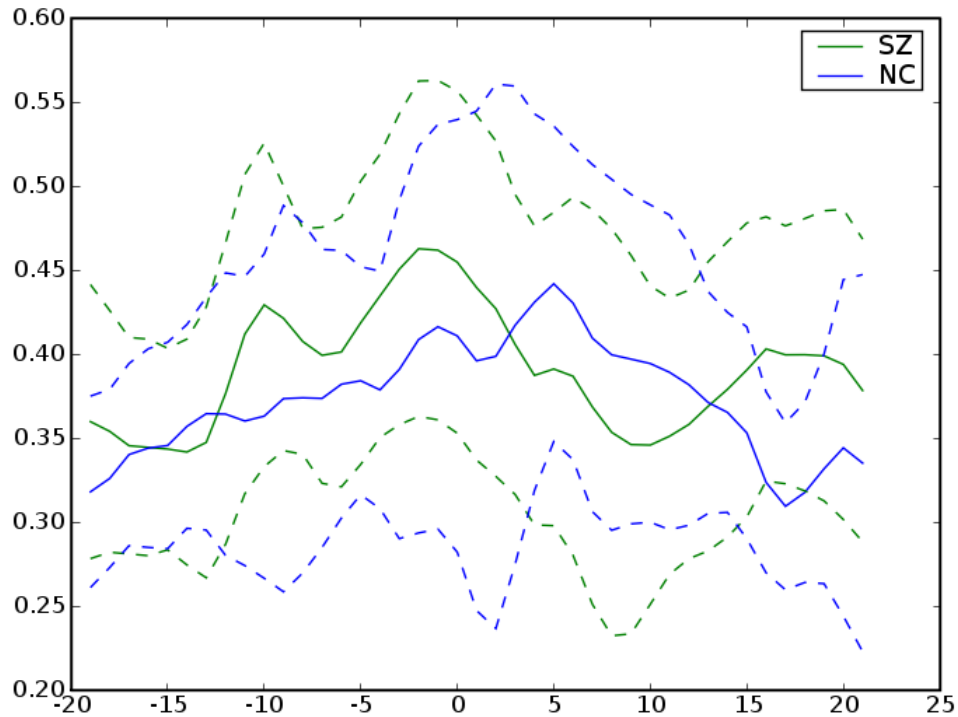


MD

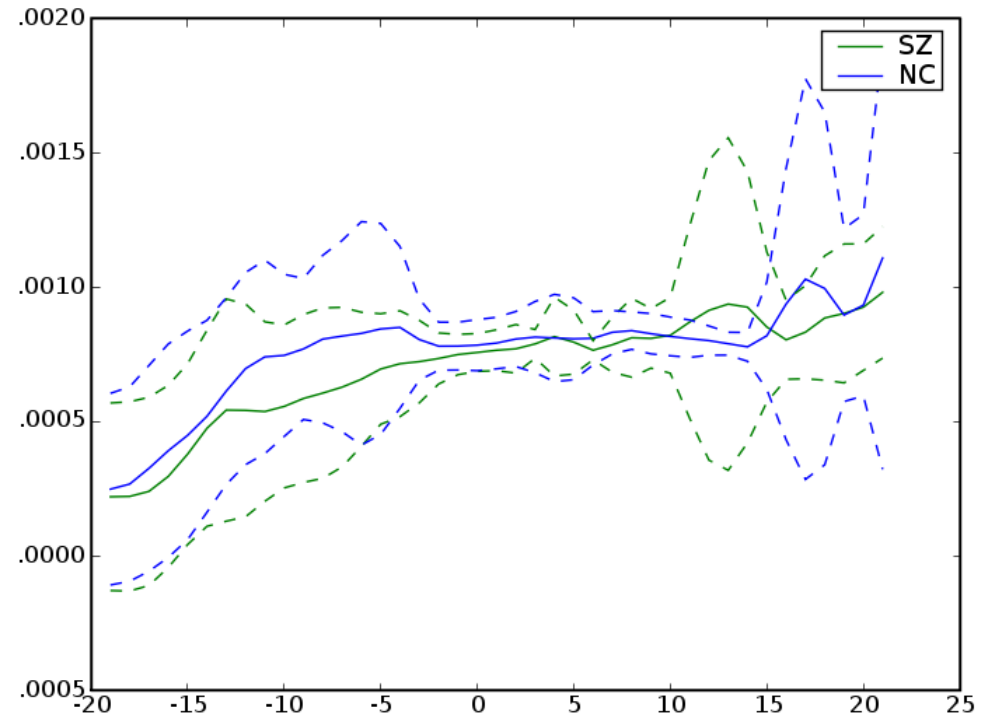
# *Right Internal Capsule*



# Right Internal Capsule

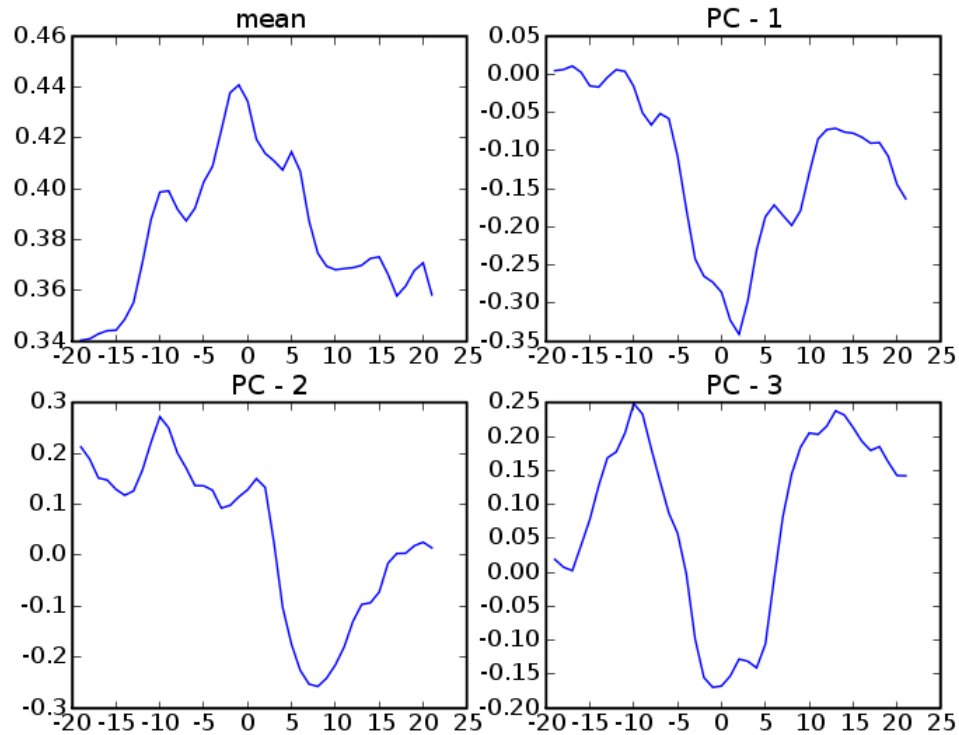


FA

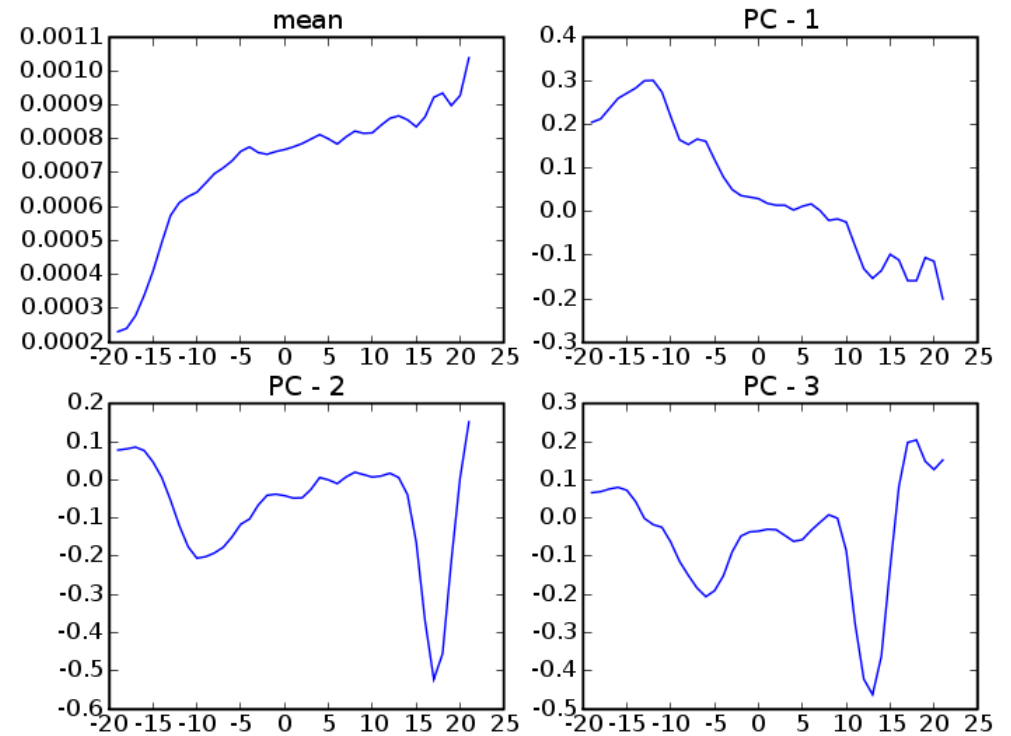


MD

# Right Internal Capsule



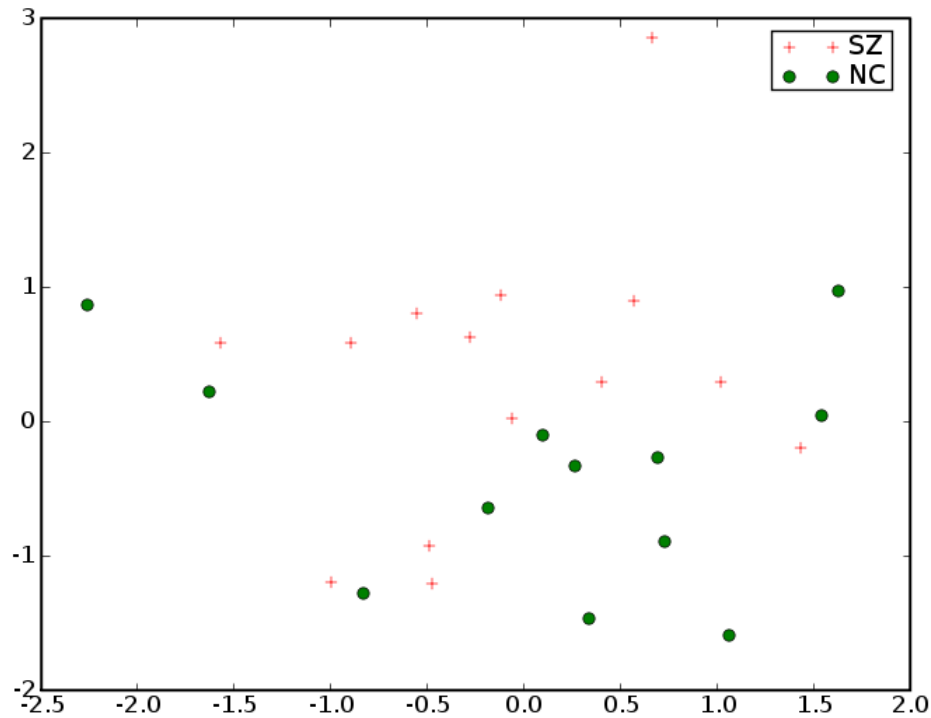
FA



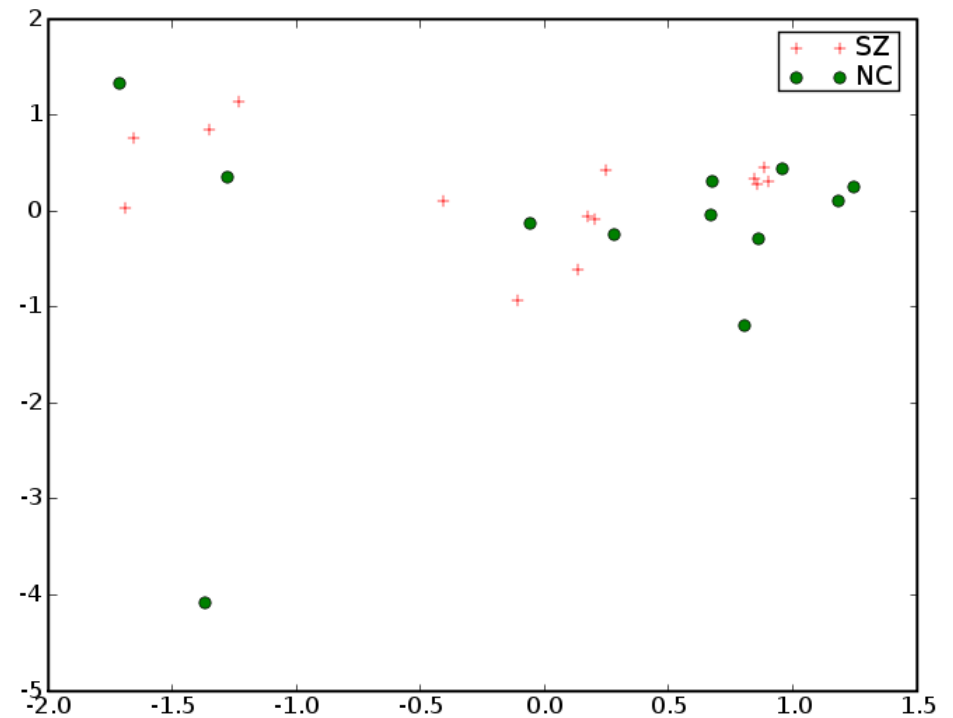
MD



# Right Internal Capsule

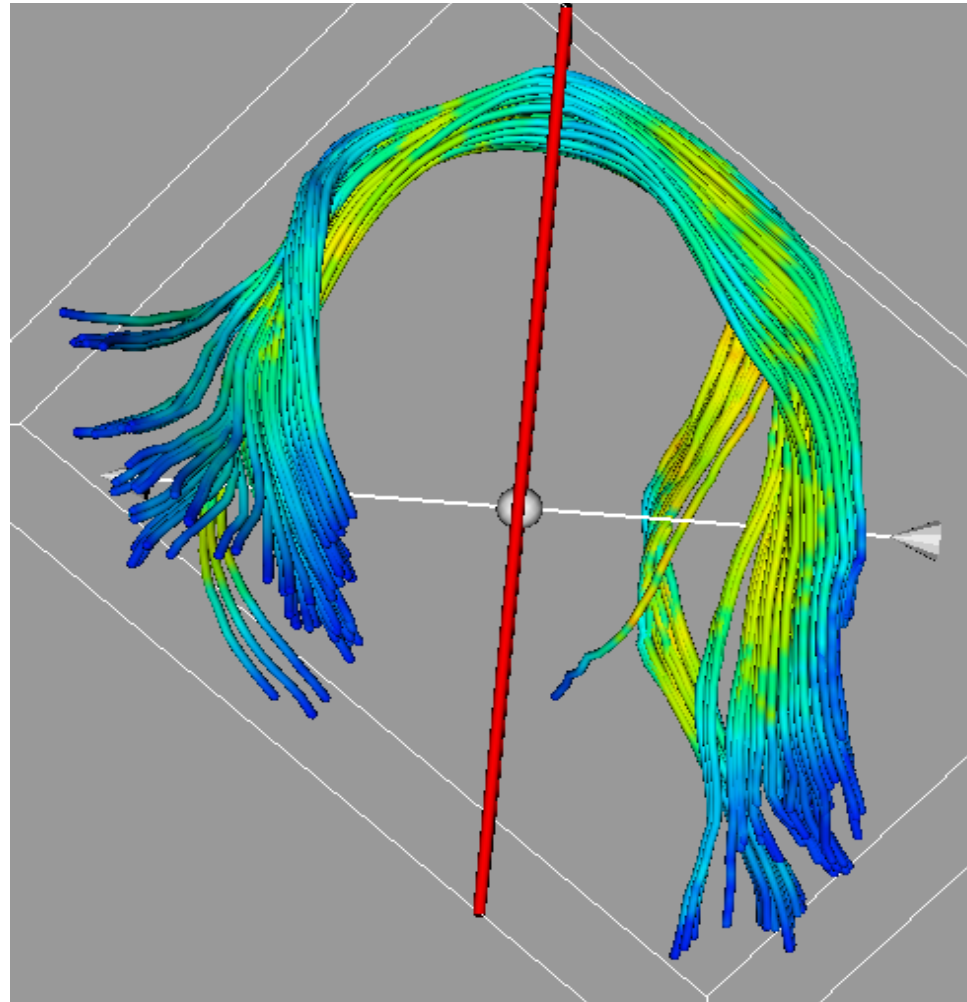


FA

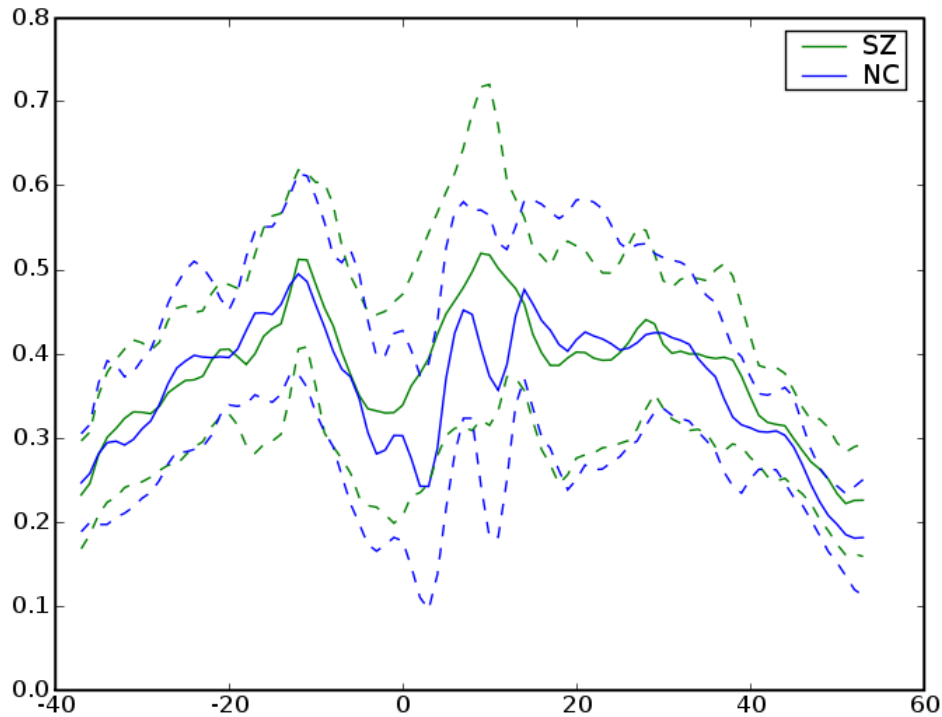


MD

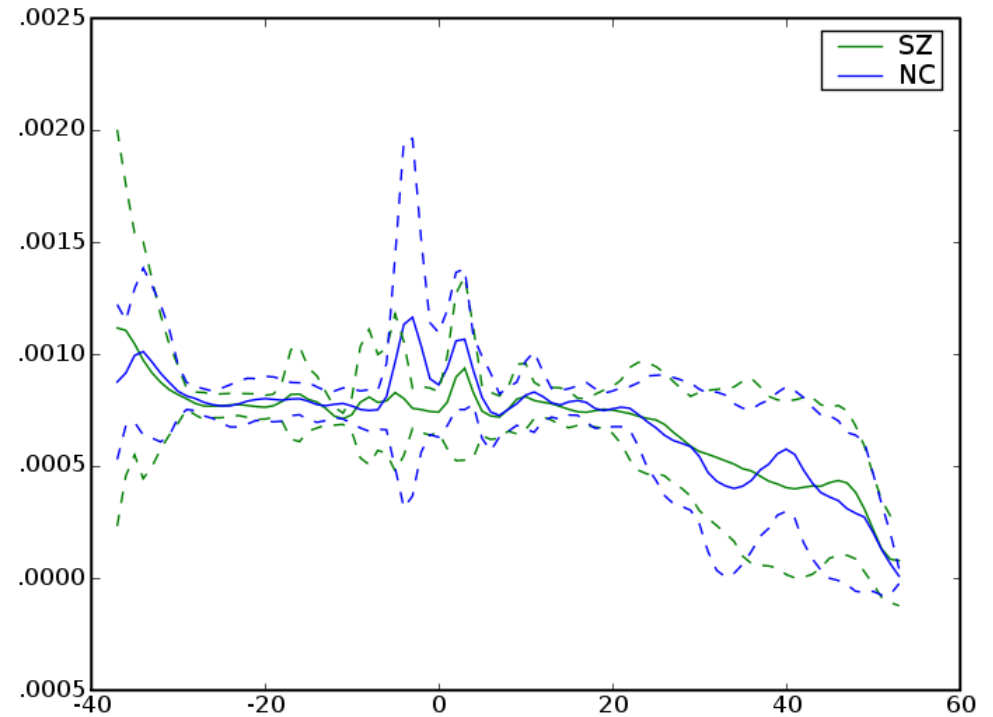
# Left Arcuate



# Left Arcuate

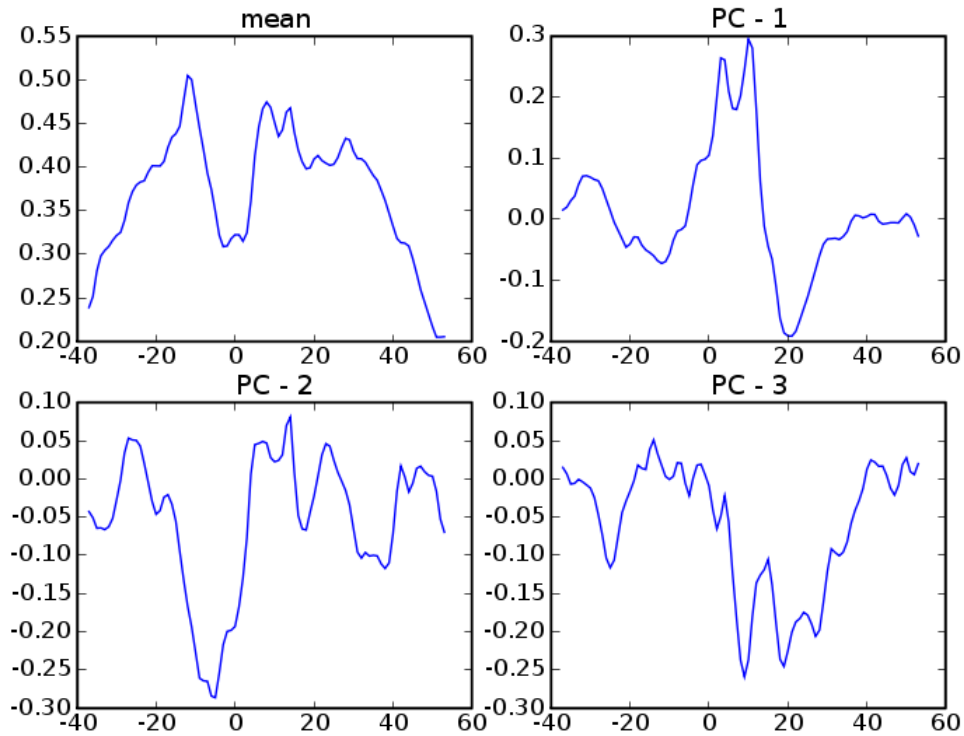


FA

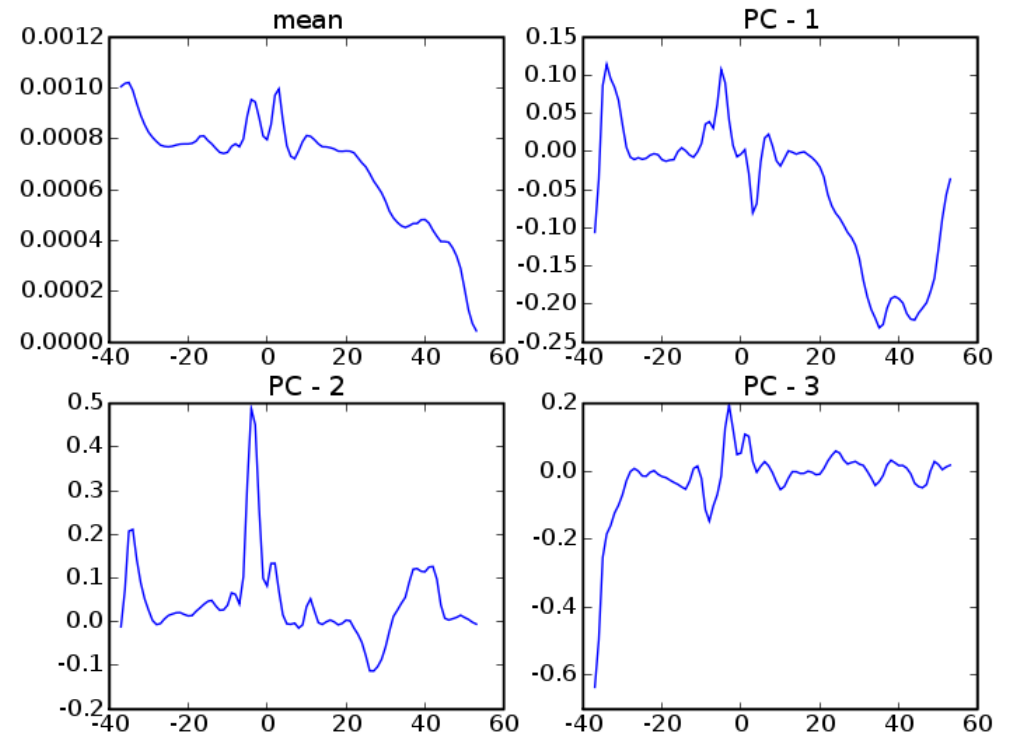


MD

# Left Arcuate

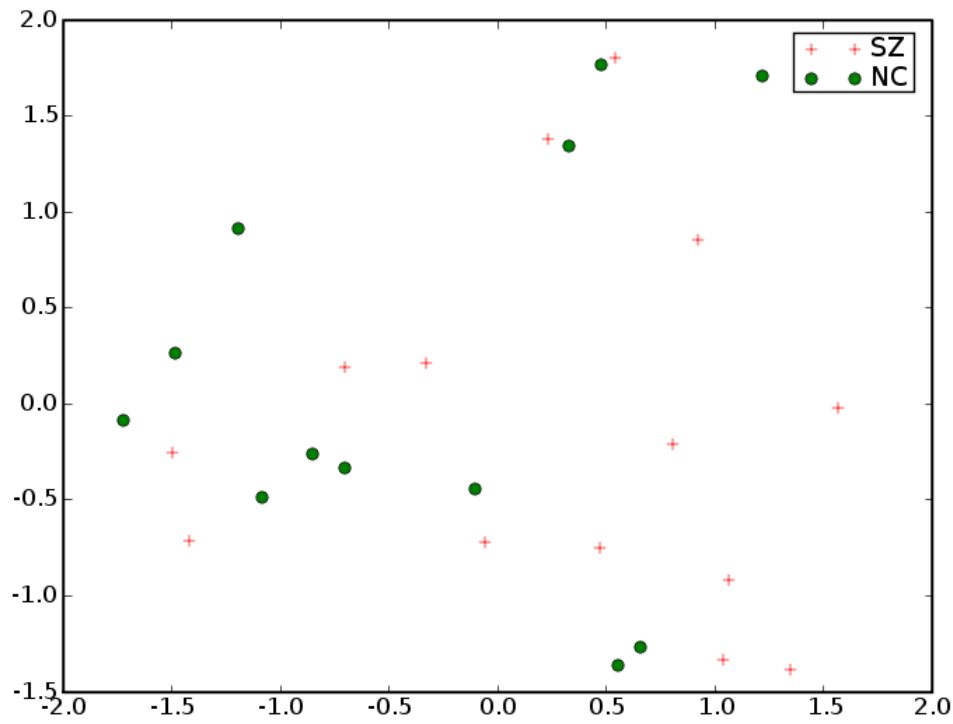


FA

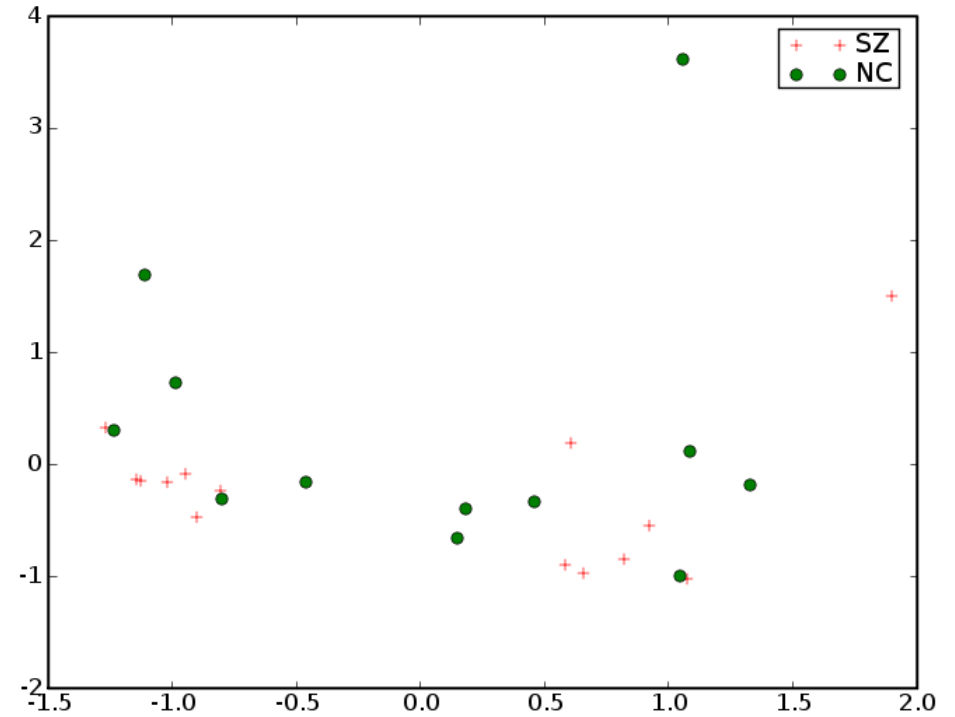


MD

# Left Arcuate



FA

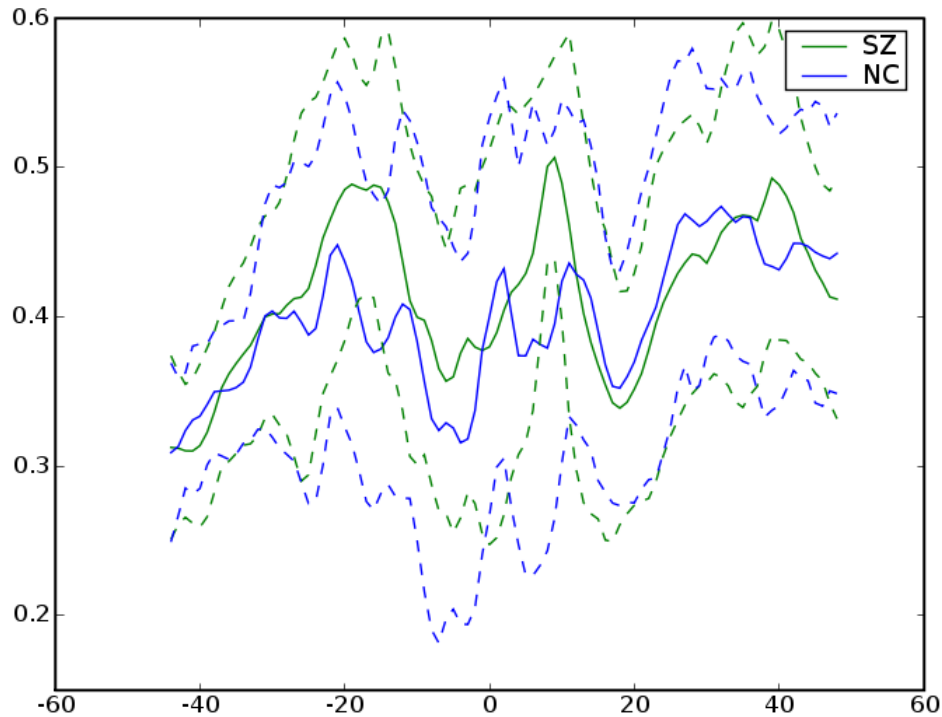


MD

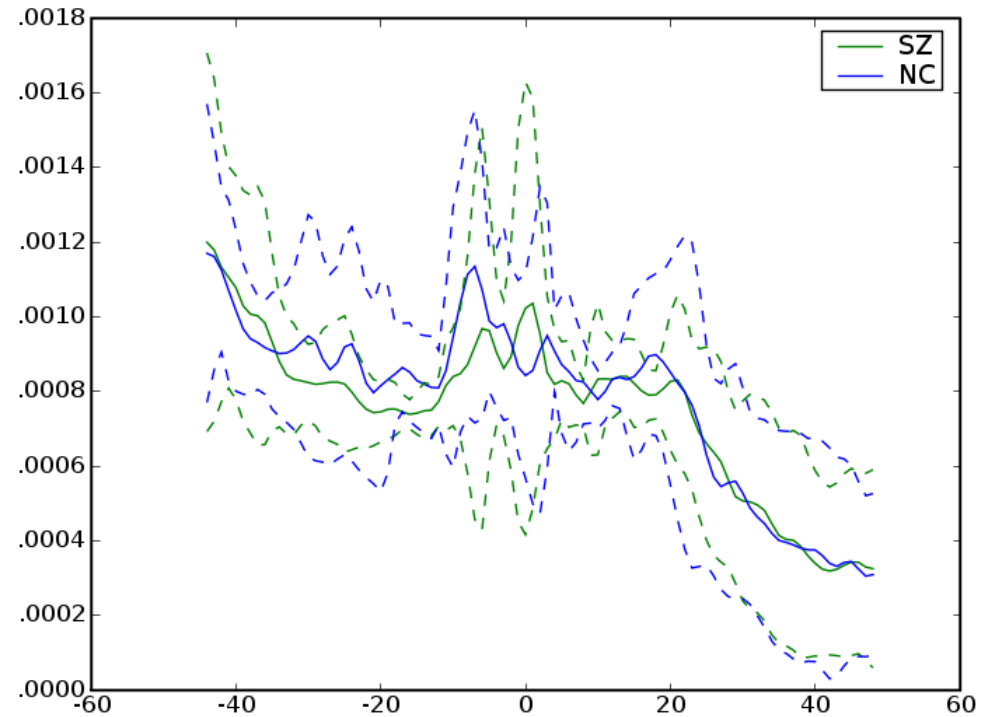
# *Right Arcuate*



# Right Arcuate

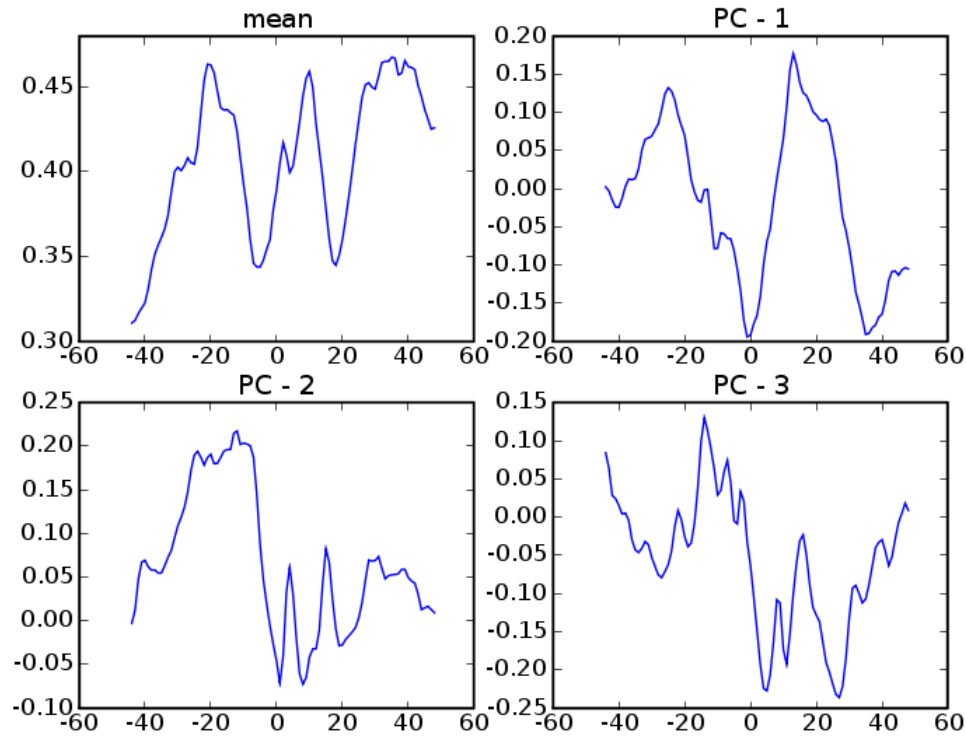


FA

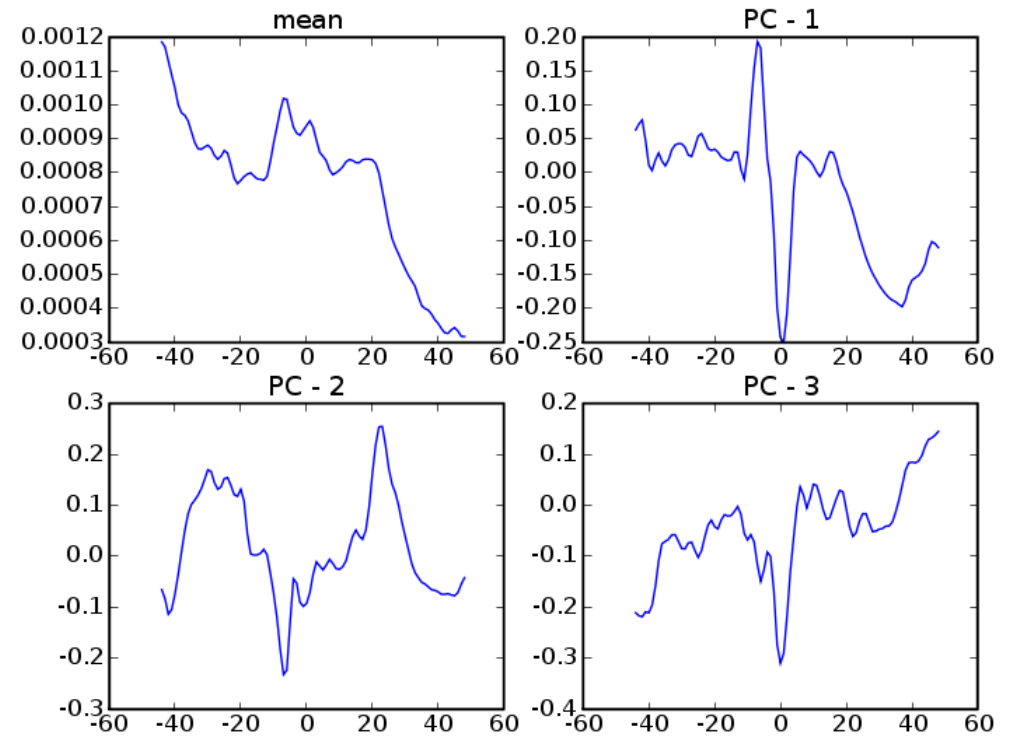


MD

# Right Arcuate



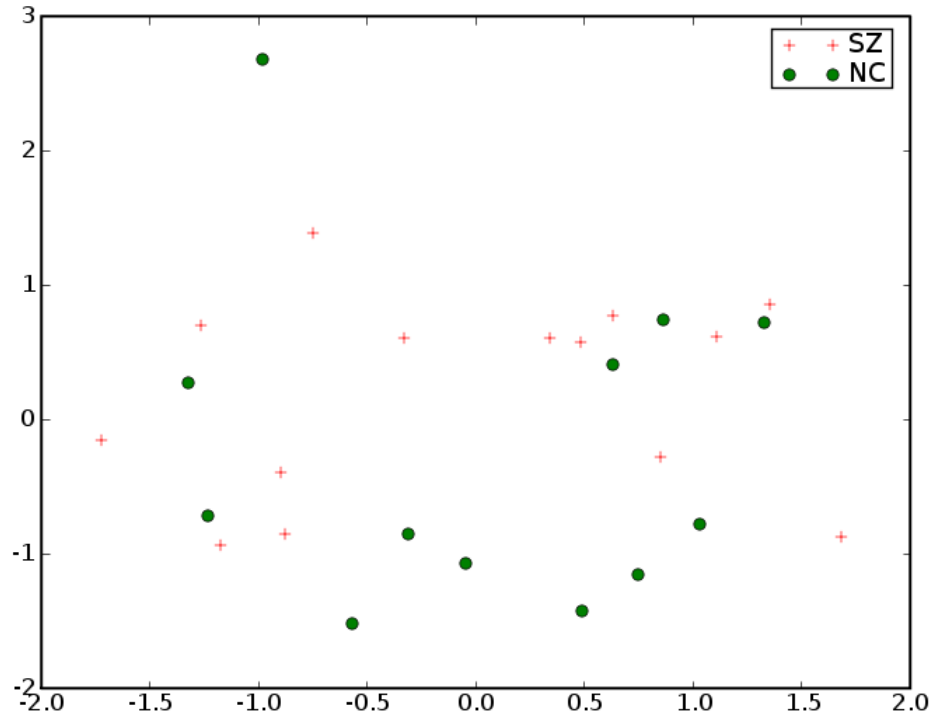
FA



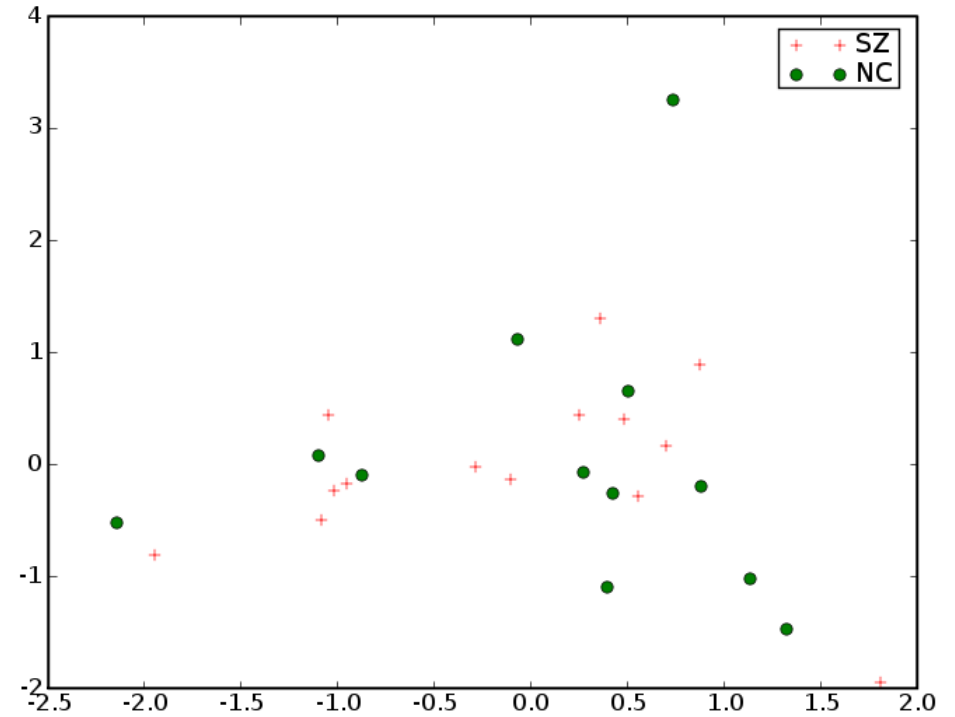
MD



# Right Arcuate

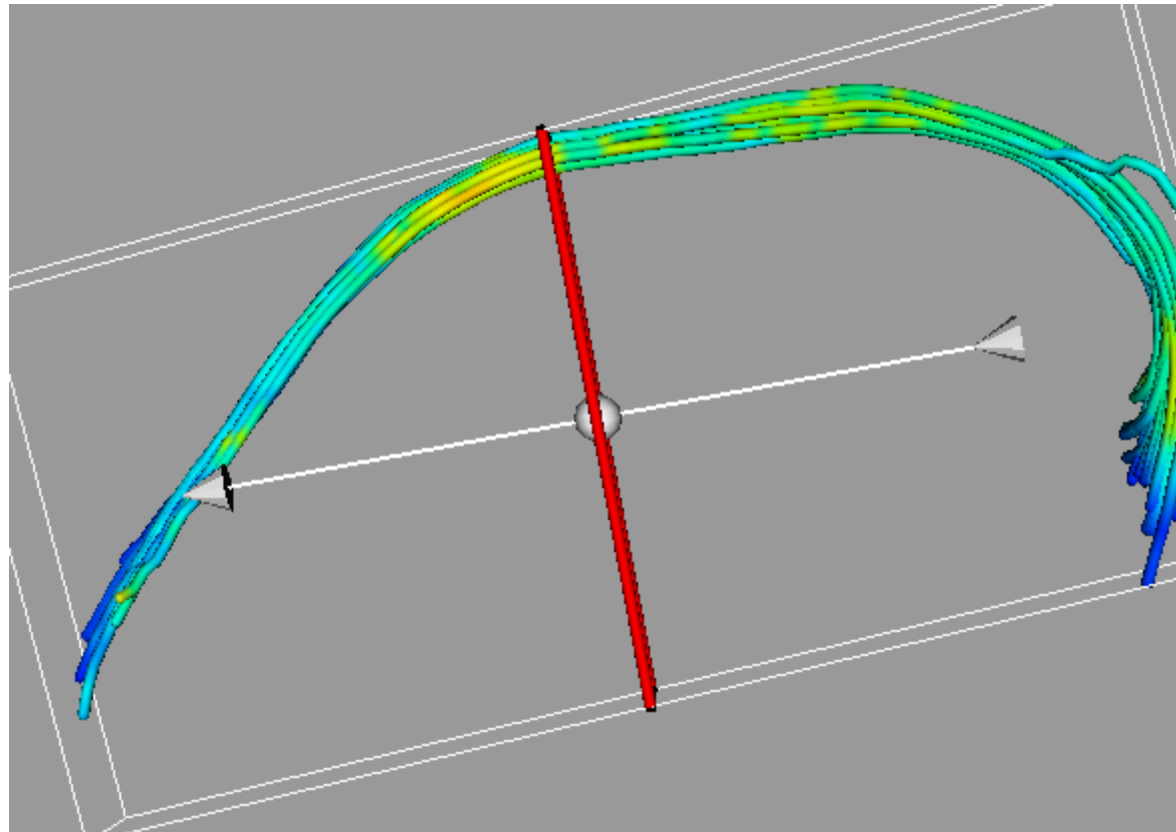


FA

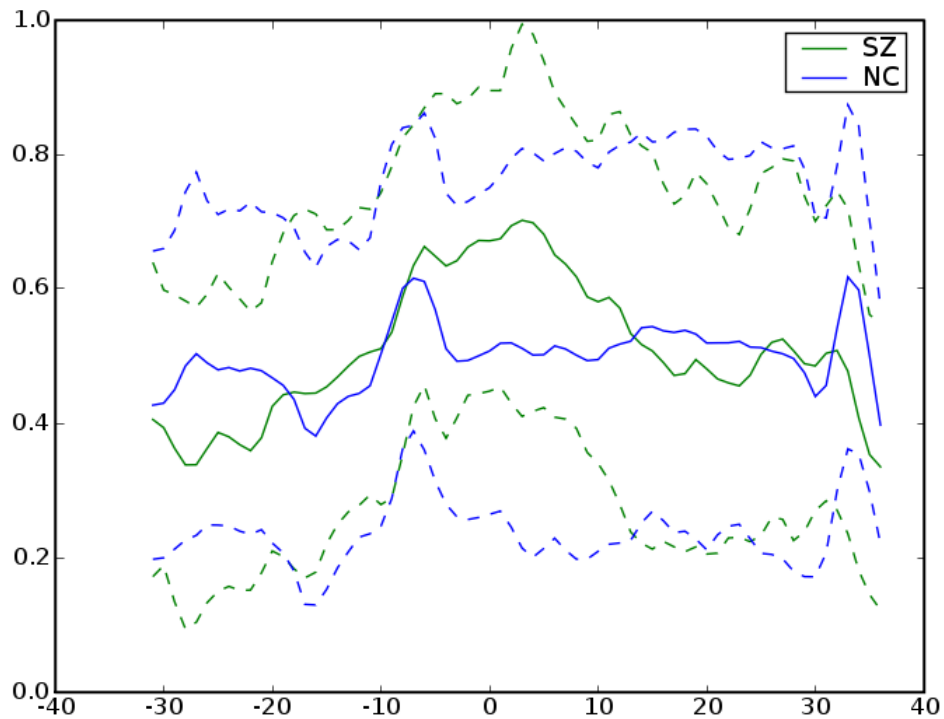


MD

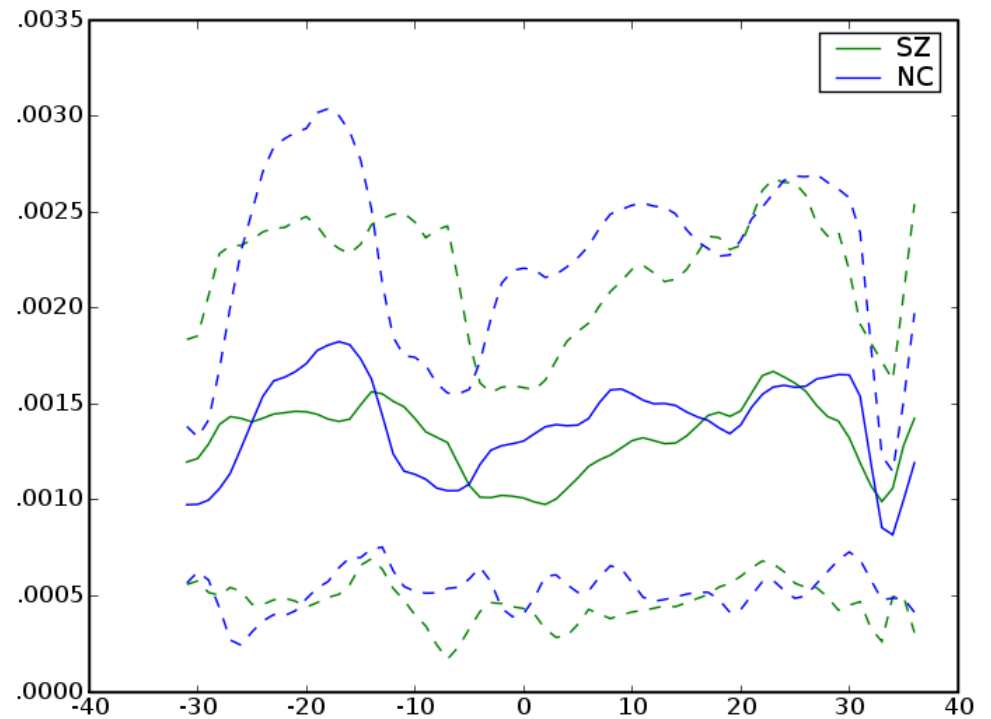
# *Left Cingulum*



# Left Cingulum

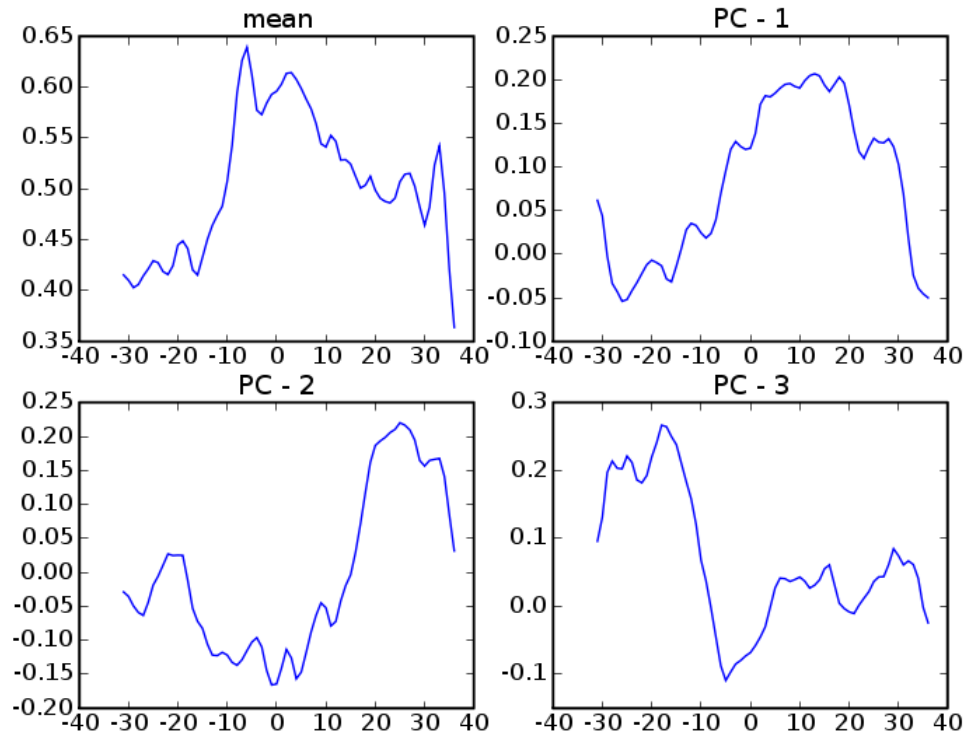


FA

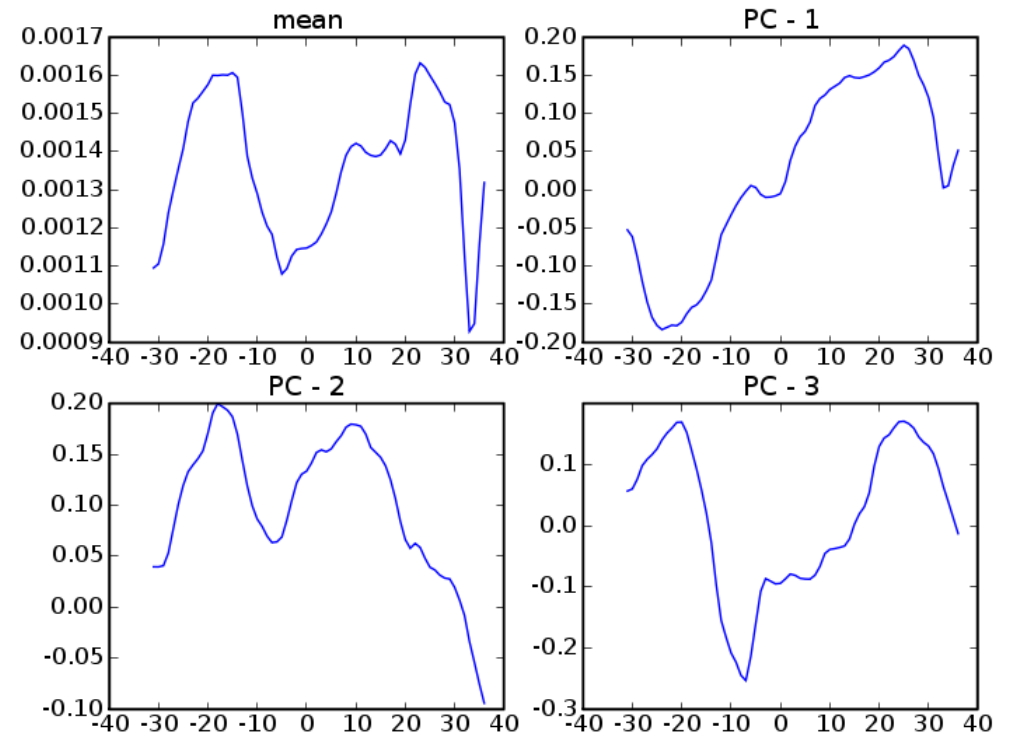


MD

# Left Cingulum

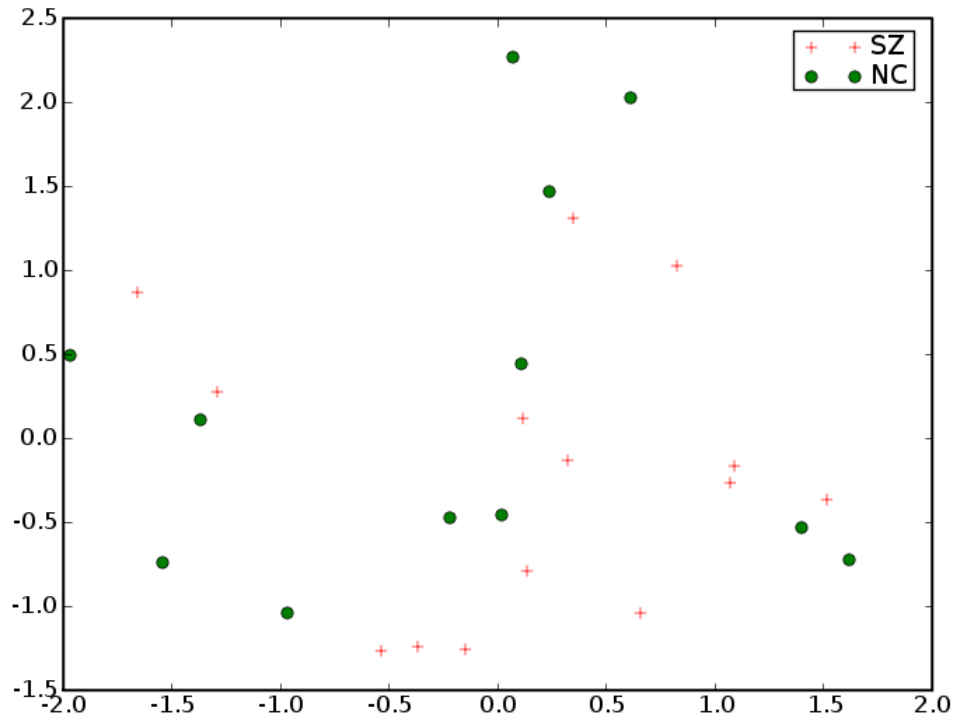


FA

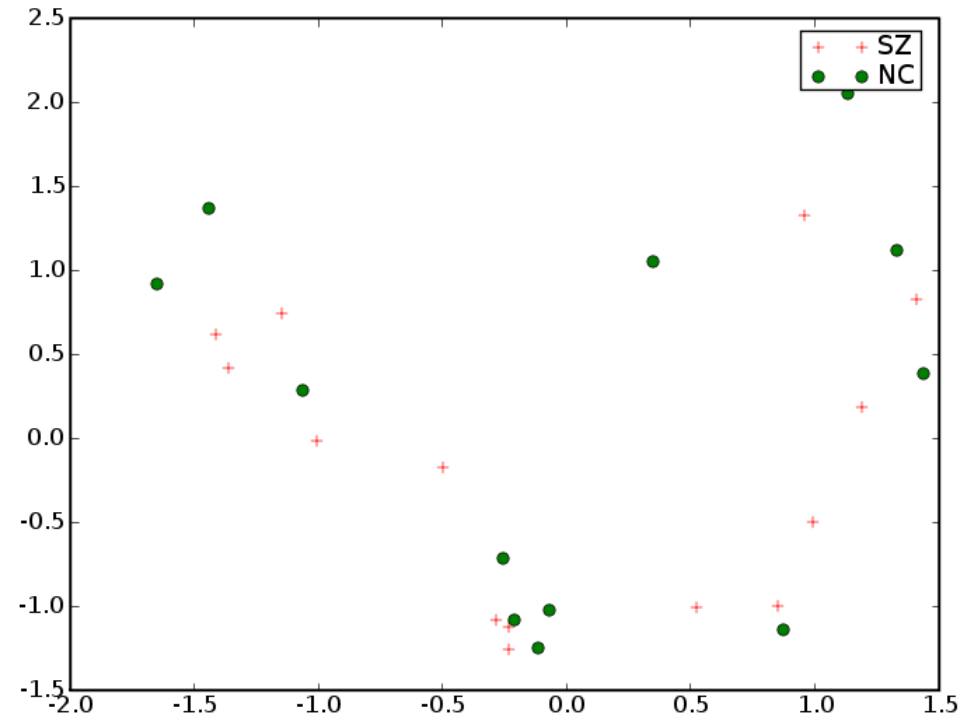


MD

# Left Cingulum

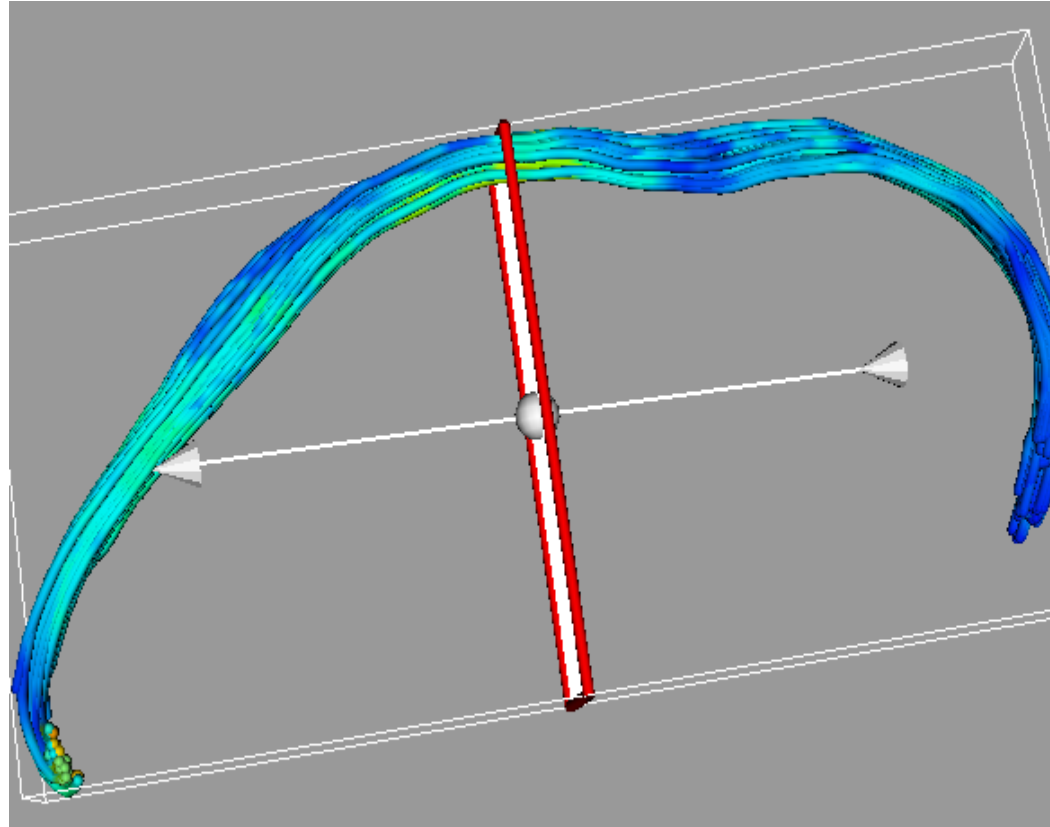


FA

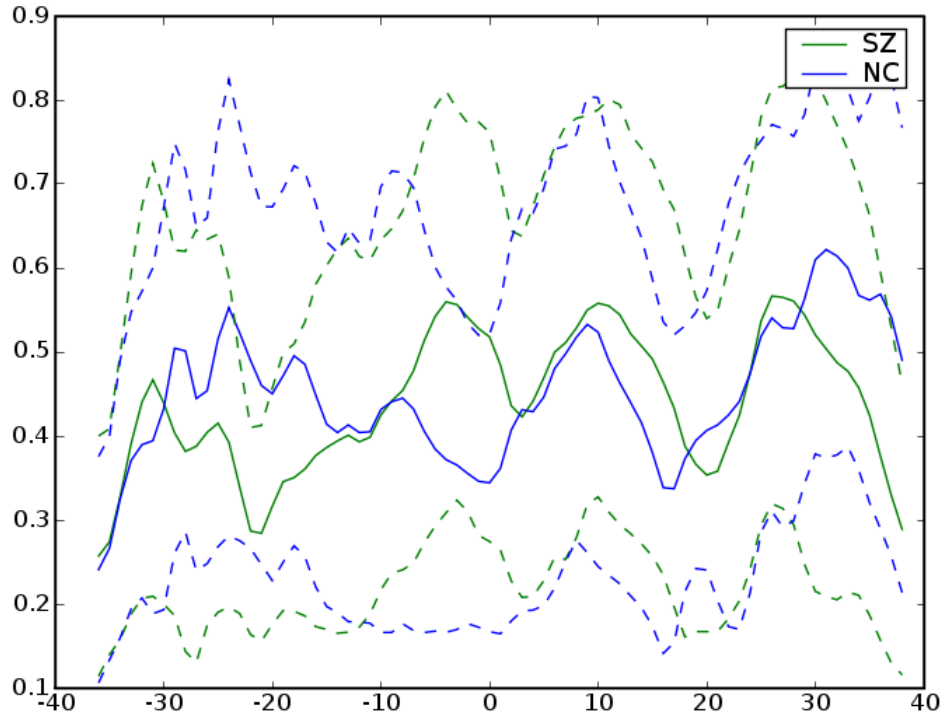


MD

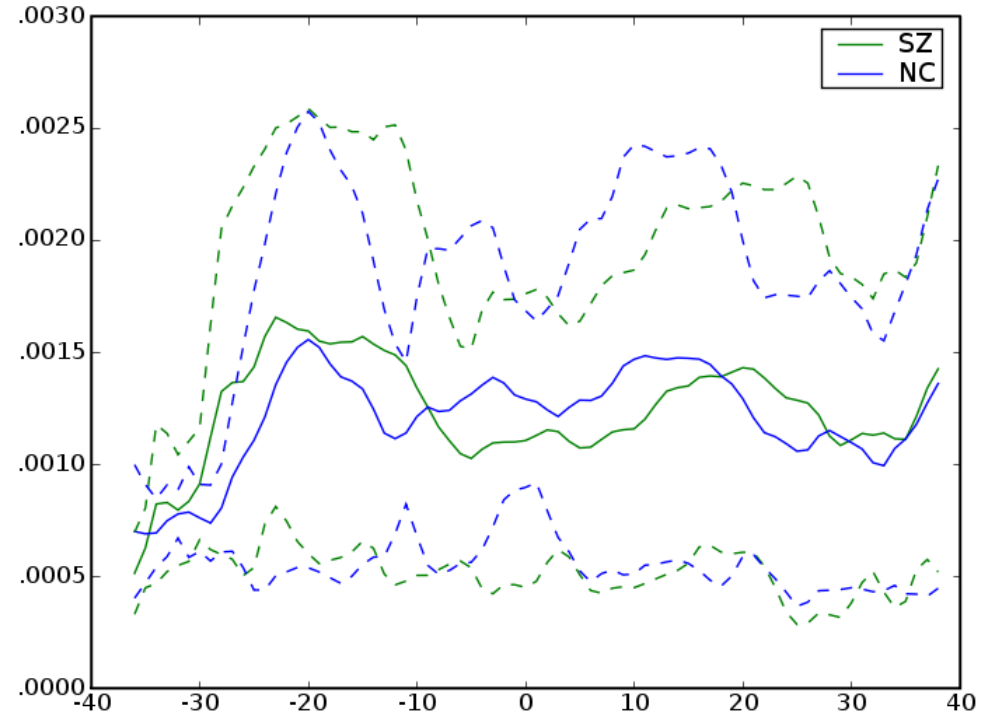
# *Right Cingulum*



# Right Cingulum

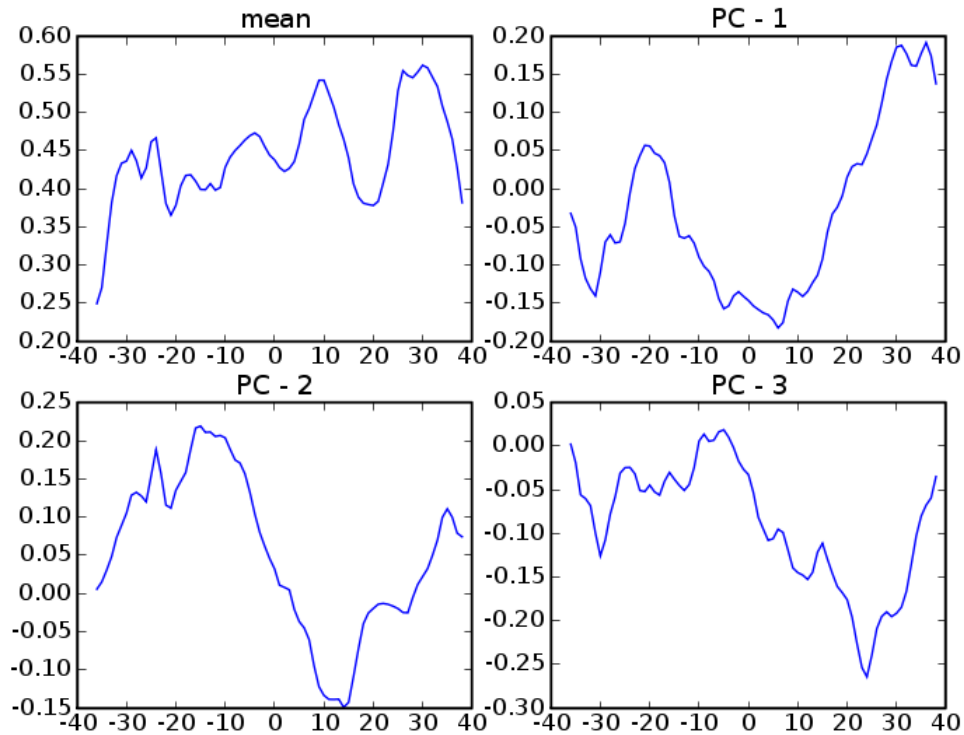


FA

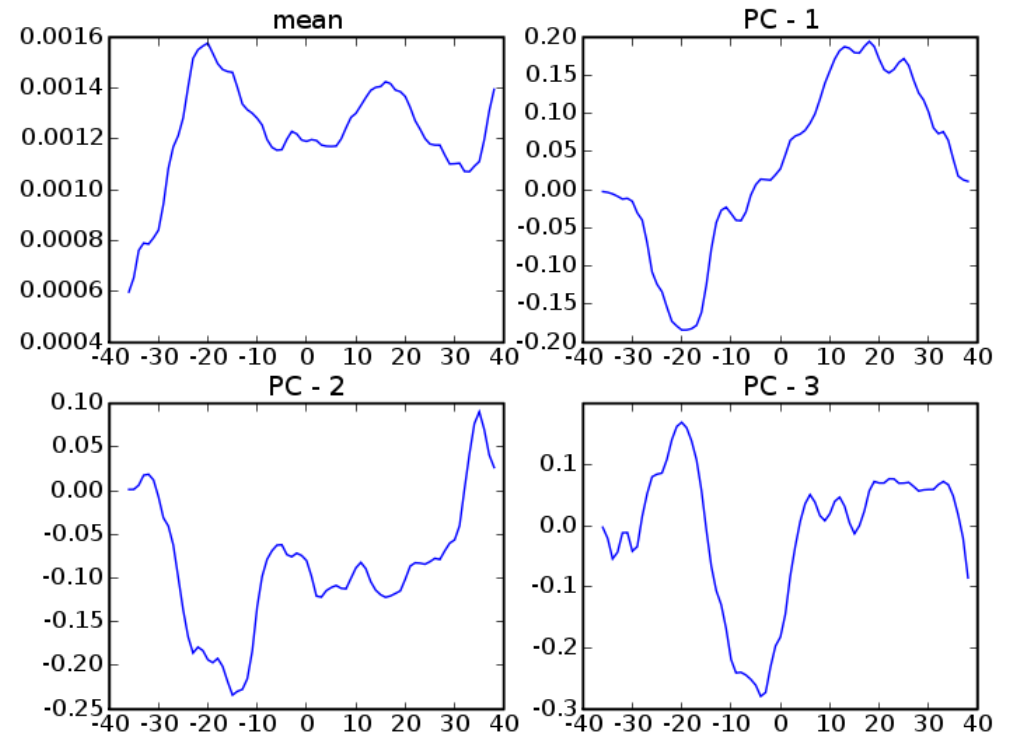


MD

# Right Cingulum



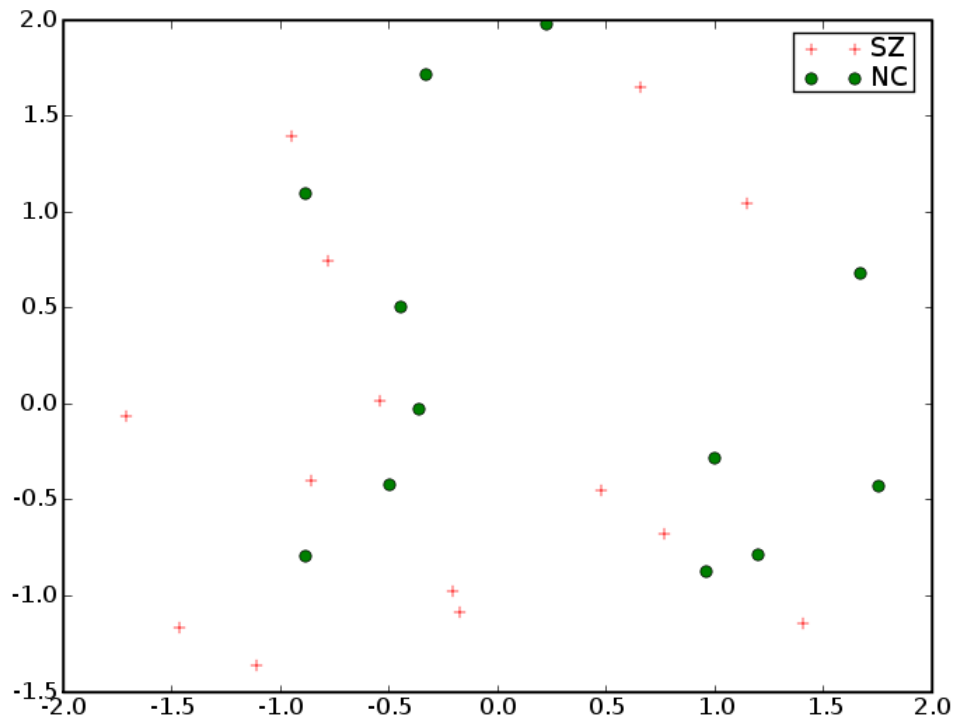
FA



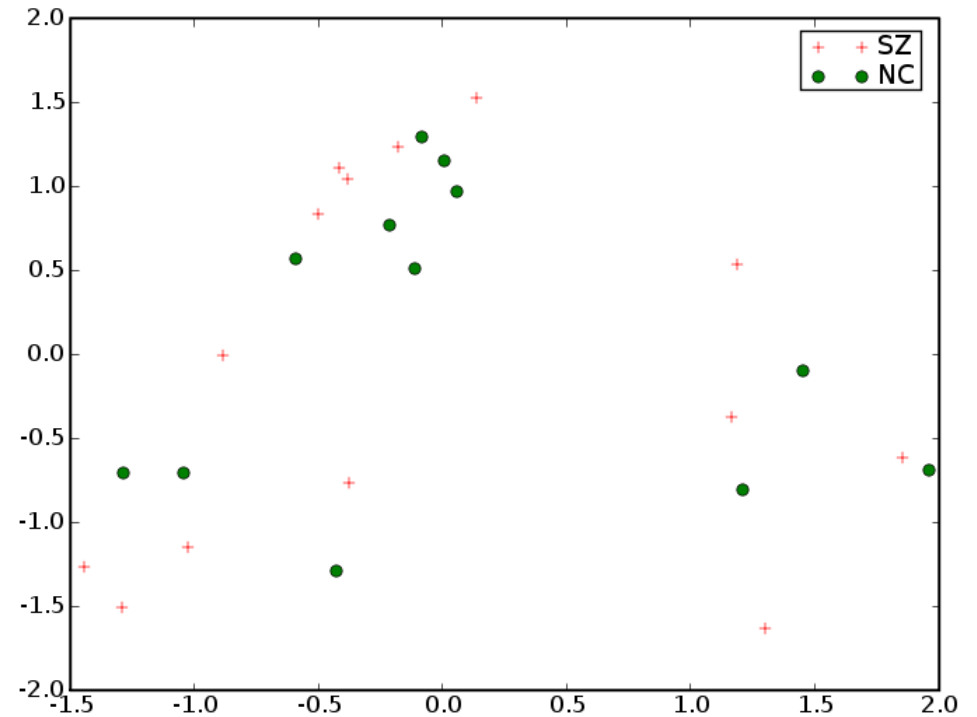
MD



# Right Cingulum

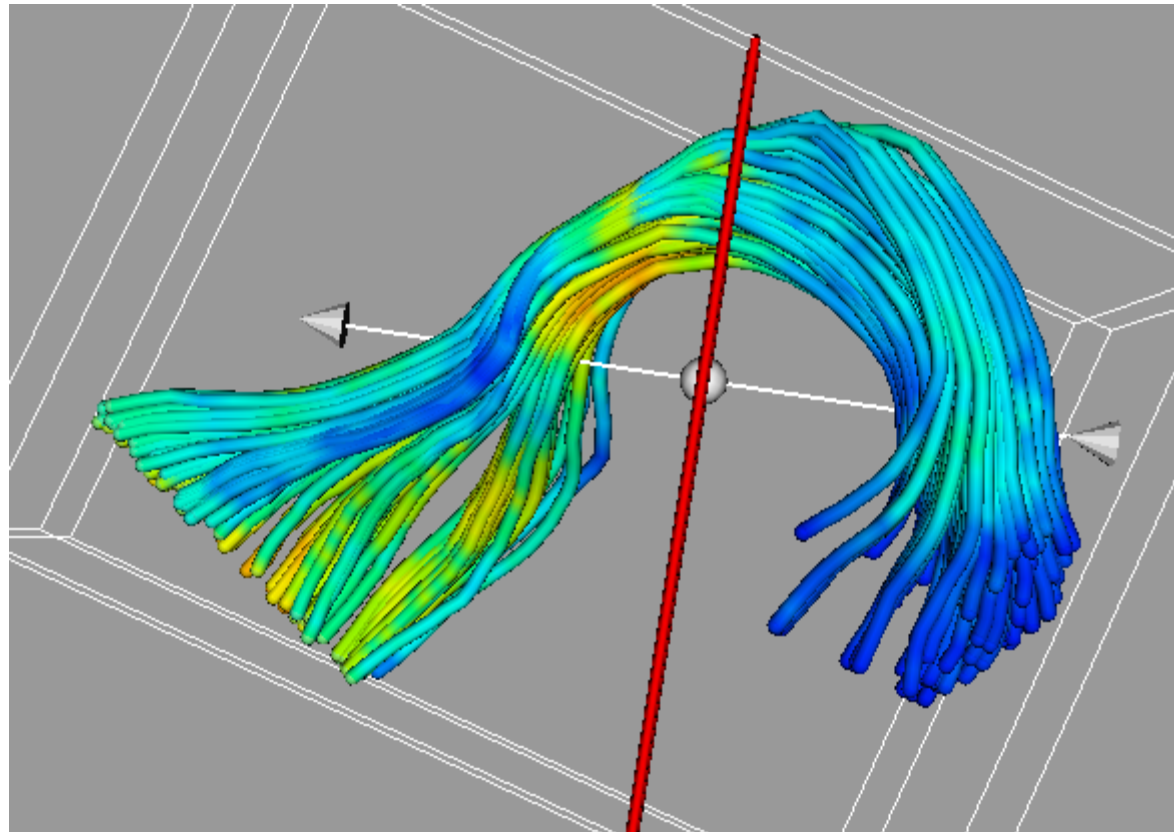


FA

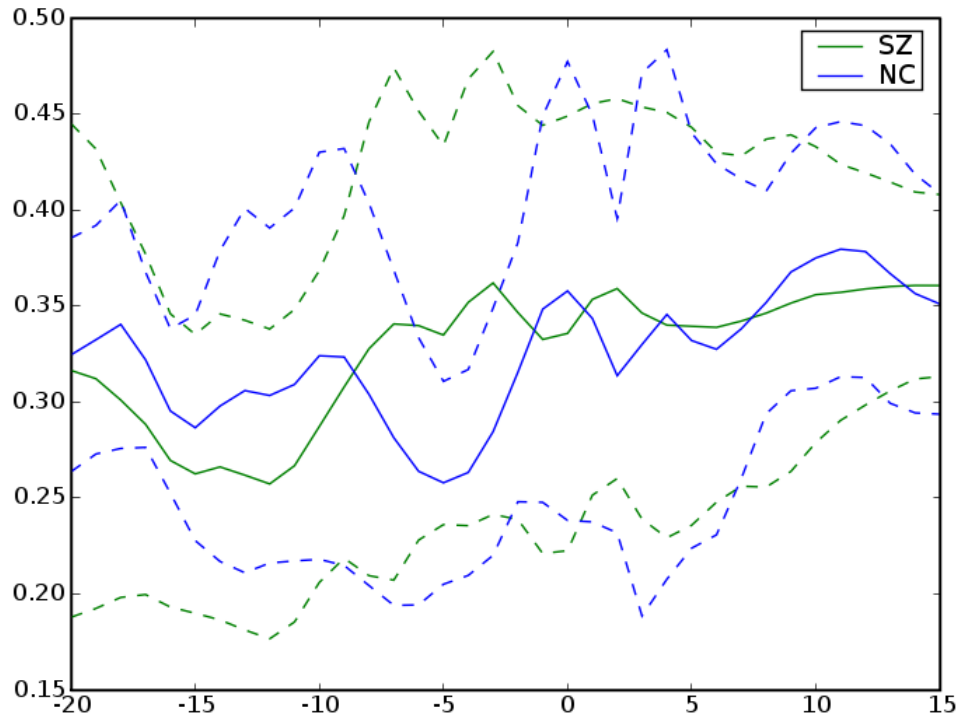


MD

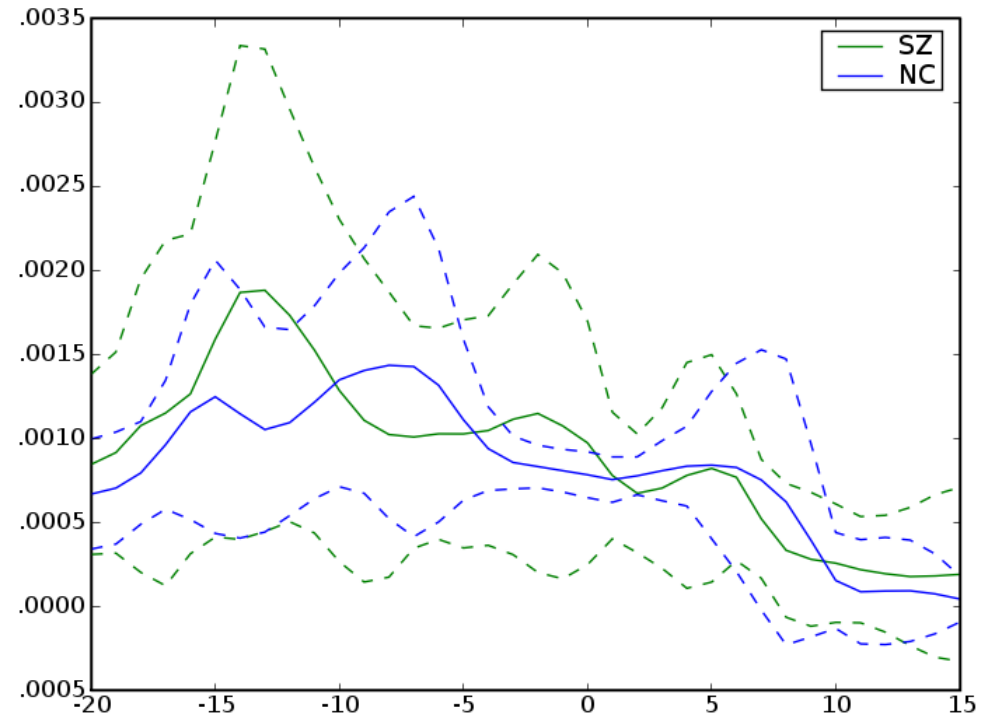
# *Left Uncinate*



# Left Uncinate

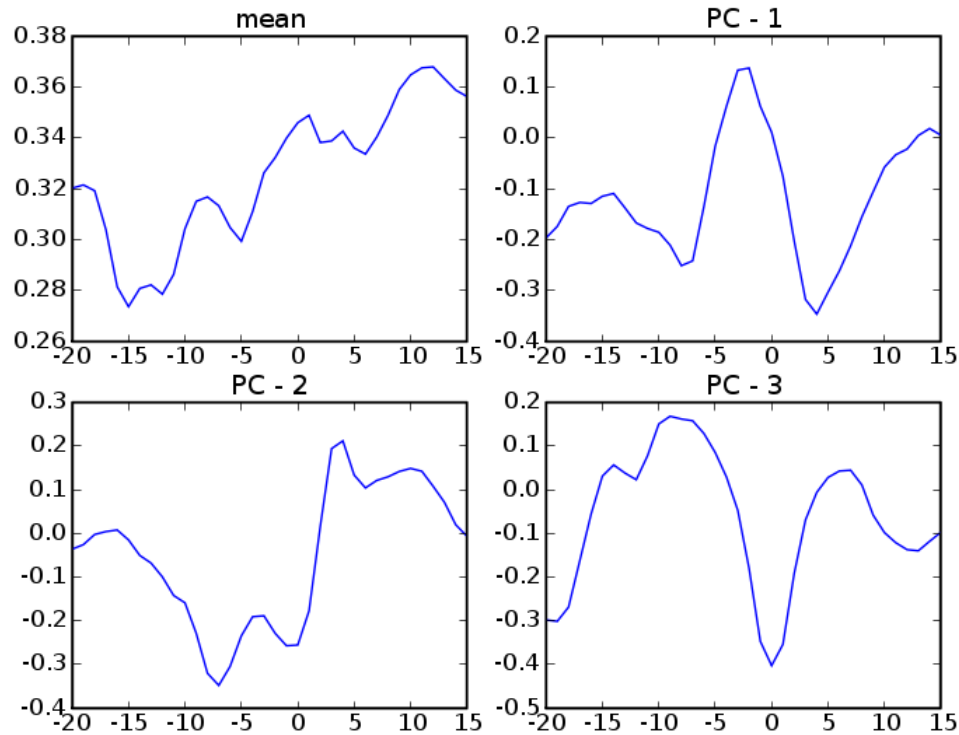


FA

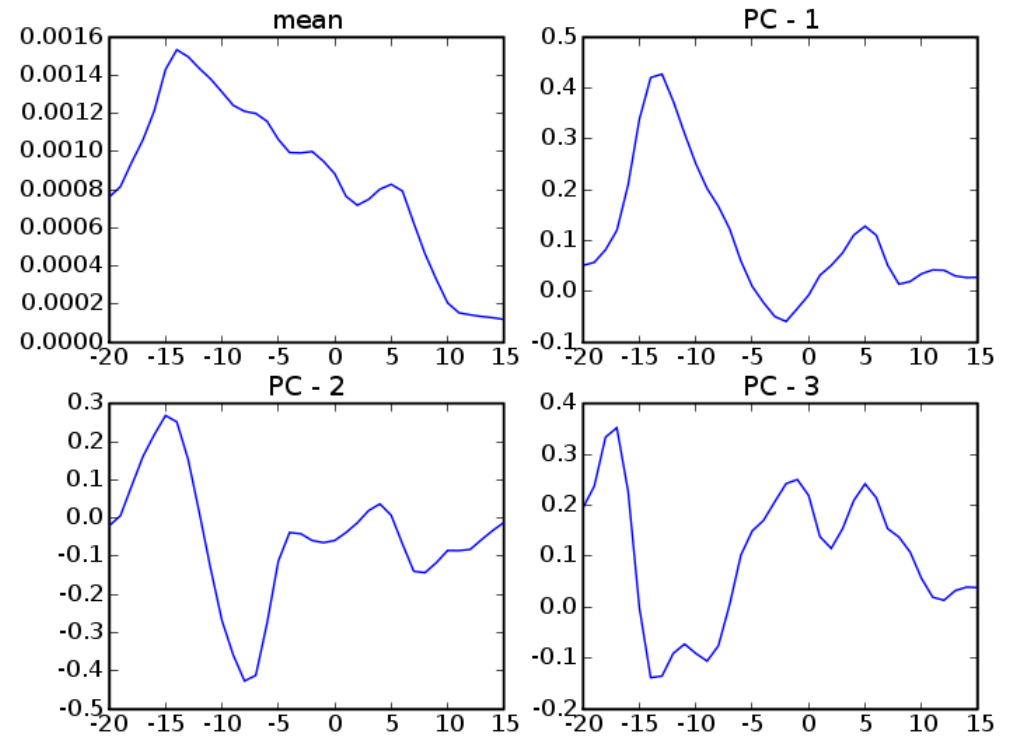


MD

# Left Uncinate

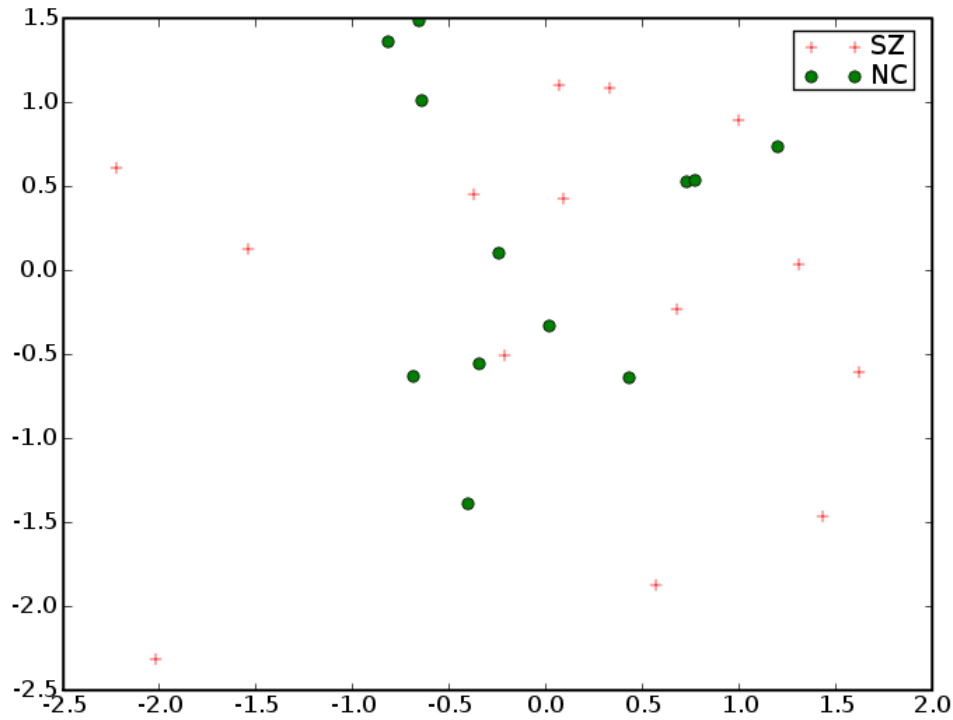


FA

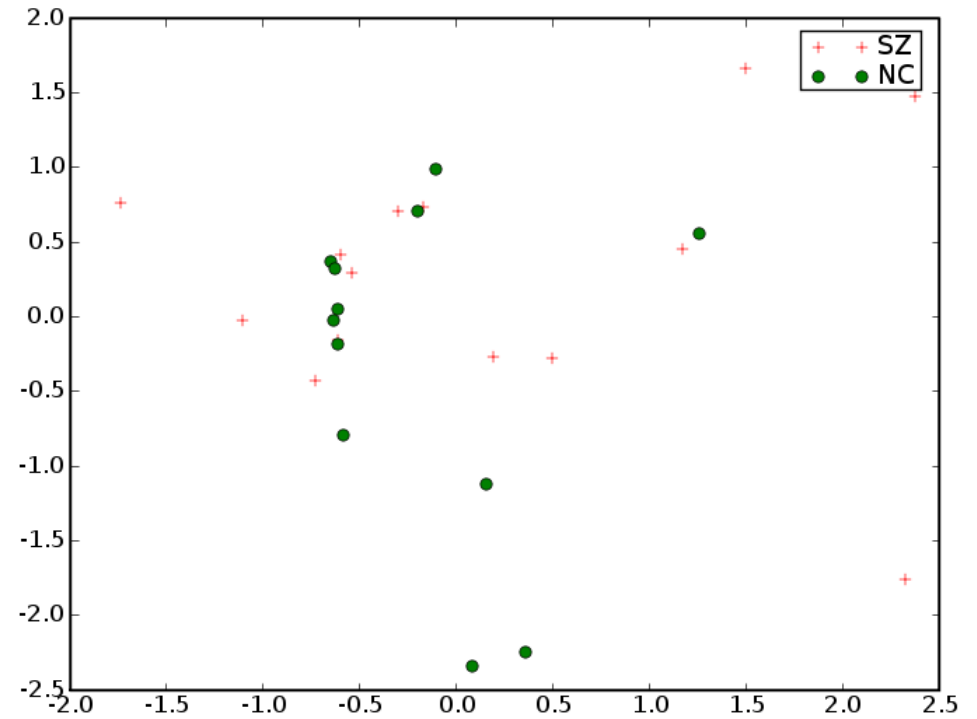


MD

# Left Uncinate

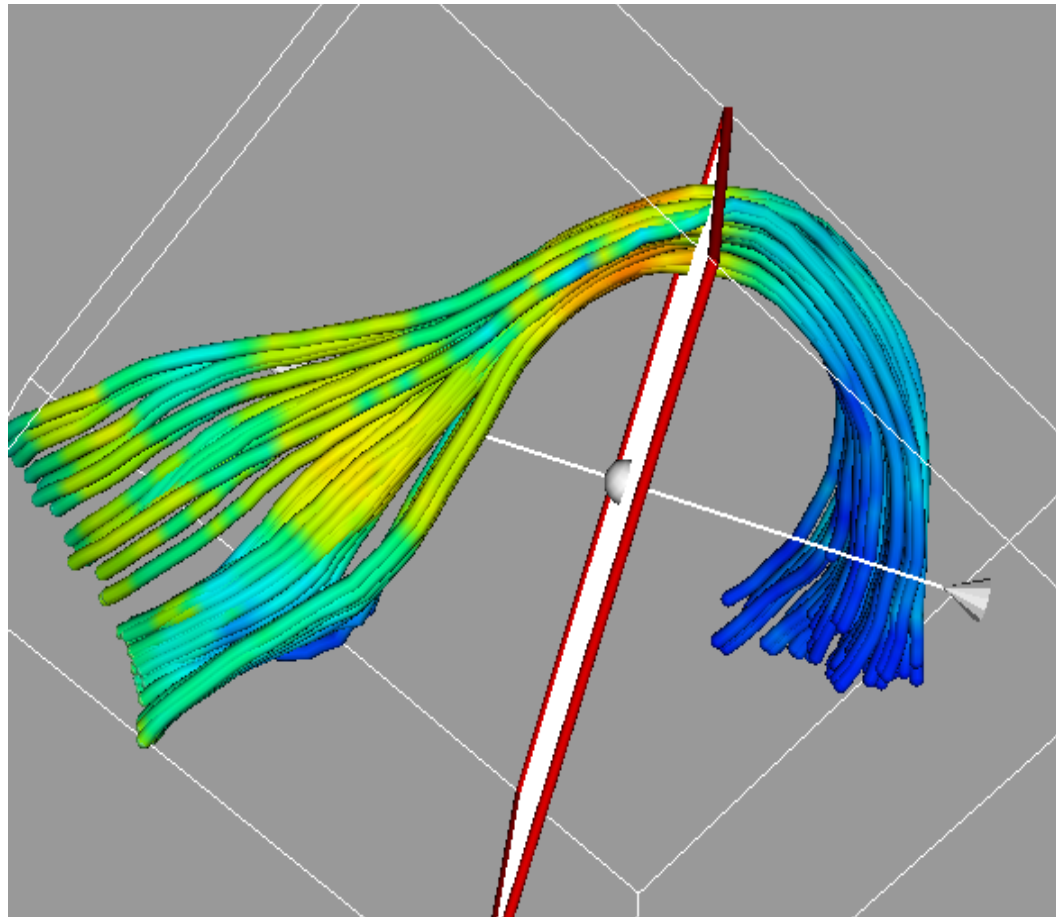


FA

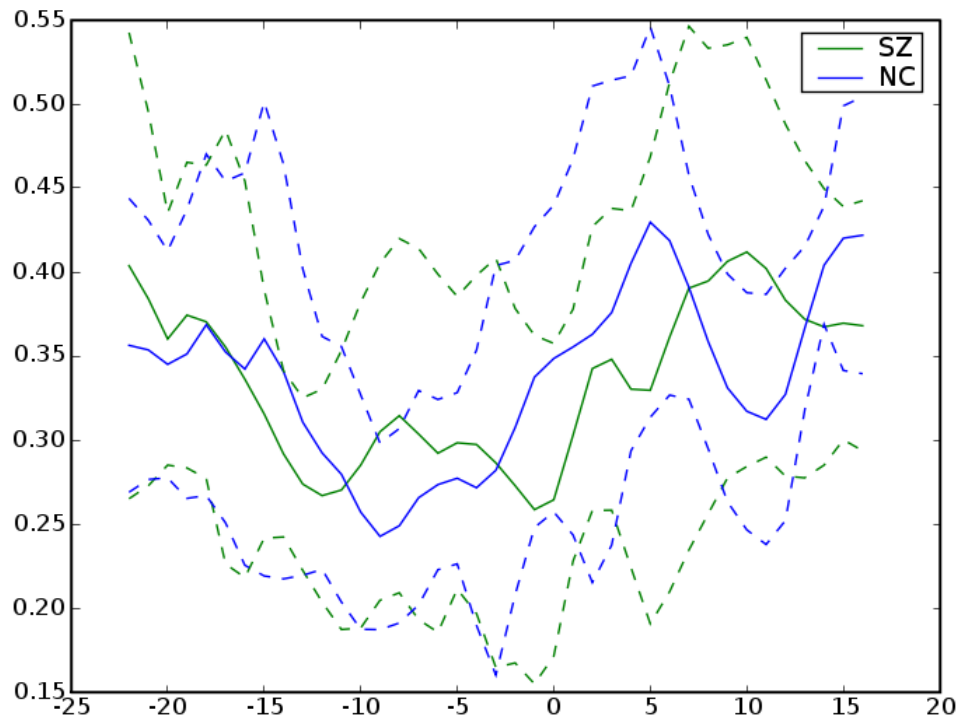


MD

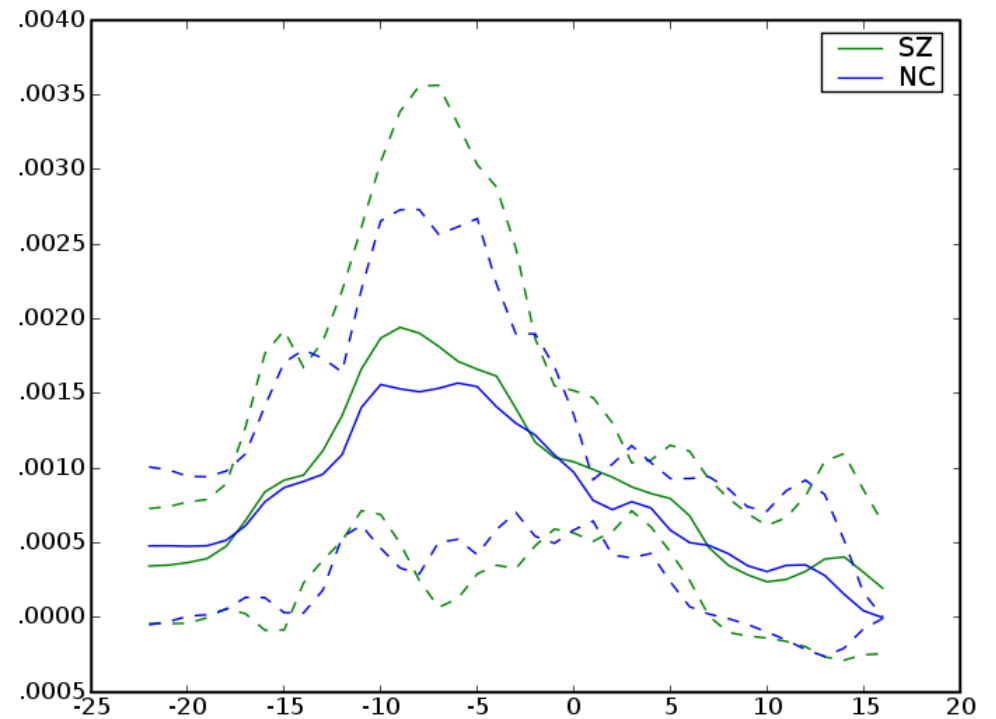
# *Right Uncinate*



# Right Uncinate

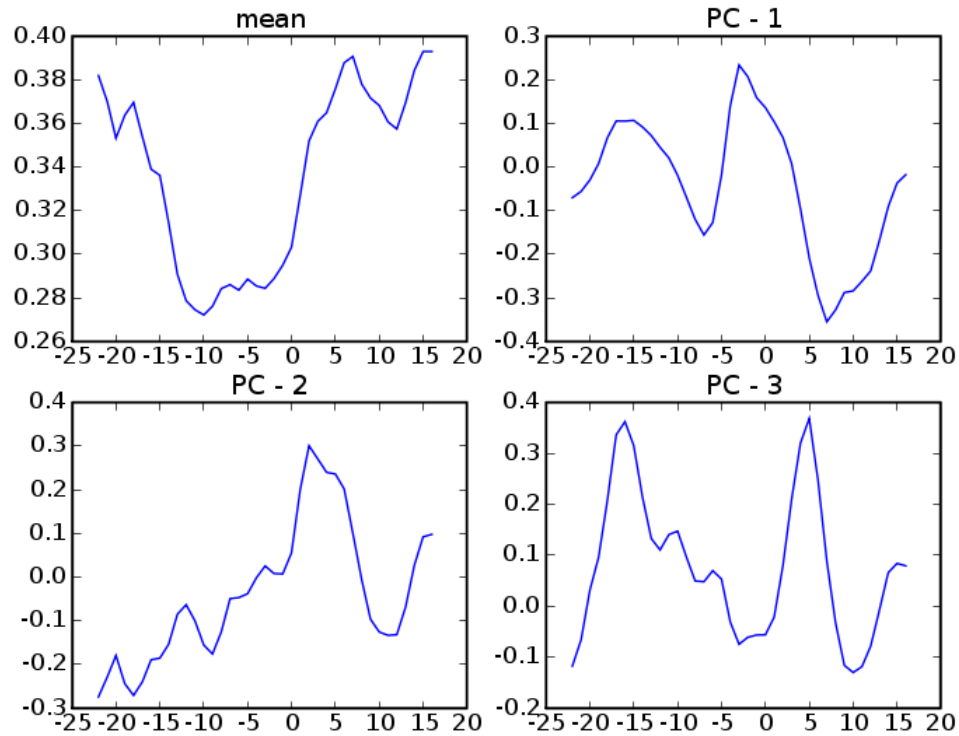


FA

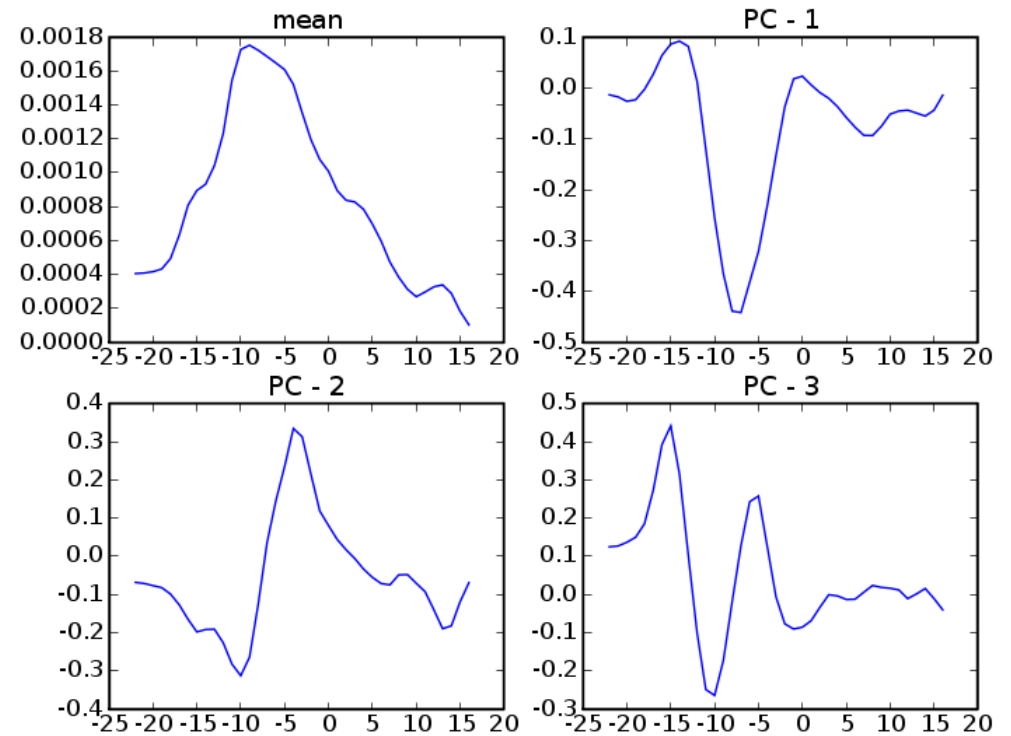


MD

# Right Uncinate



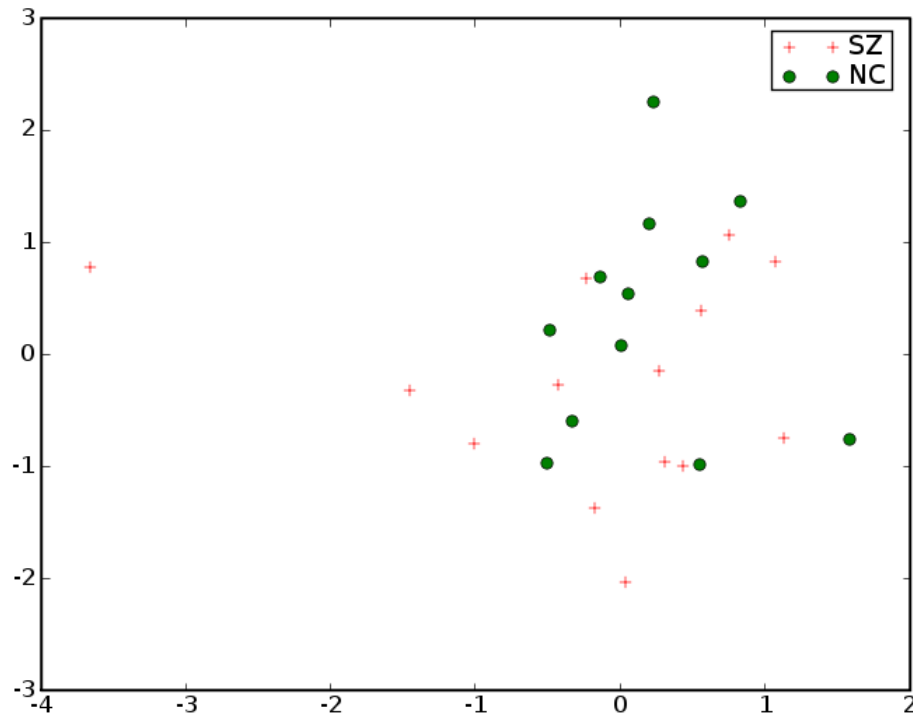
FA



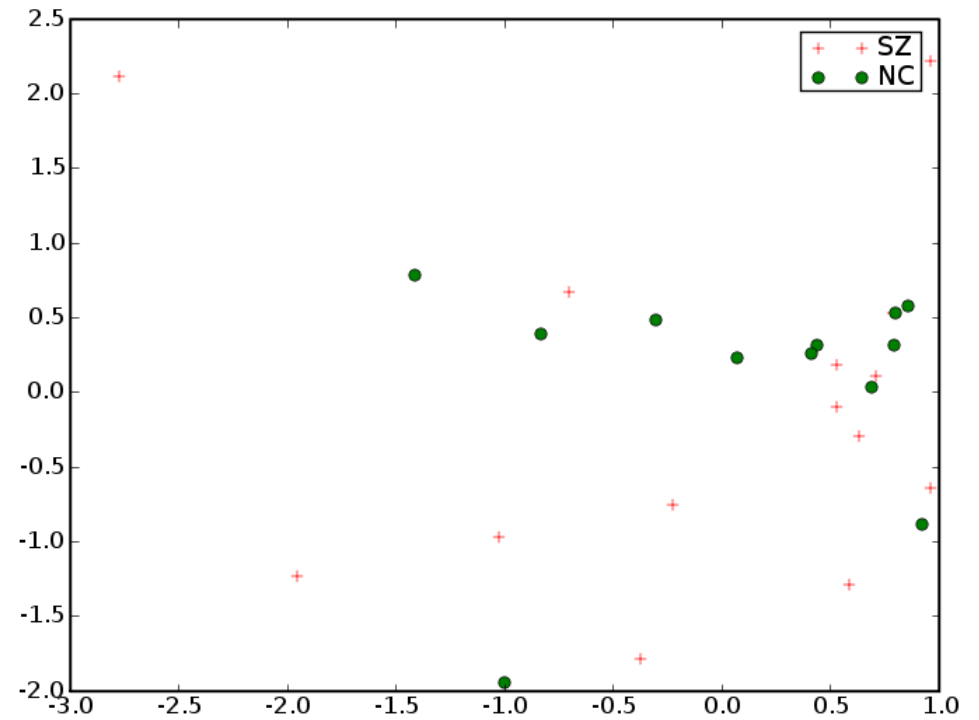
MD



# Right Uncinate



FA



MD

# Results

- ◆ Lateralization in Internal Capsule, Cingulum,
  - ◆ Possibly due to atlas procedure especially in cingulum
  - ◆ Possibly in original data especially in internal capsule
- ◆ No statistically significant diffusion differences
- ◆ We want to compare the atlas results with individual manual processing

# References

- [1] Improved correspondance for DTI population studies via unbiased atlas building. Casey Goodlett, Brad Davis, Remi Jean, Guido Gerig. MICCAI 2006.
- [2] Unbiased diffeomorphic atlas construction for computational anatomy. Sarang Joshi, Brad Davis, Matthieu Jomier, Guido Gerig. NeuroImage vol. 23 Supplement. pgs 151-160. 11/2004
- [3] Functional Data Analysis. Ramsay, J.O.; Silverman, B.W.