

Differences and Similarities in Insular and Temporal Pole MRI Gray Matter Volume Abnormalities in First-Episode Schizophrenia and Affective Psychosis

Kiyoto Kasai, MD; Martha E. Shenton, PhD; Dean F. Salisbury, PhD; Toshiaki Onitsuka, MD, PhD; Sarah K. Toner, BA; Deborah Yurgelun-Todd, PhD; Ron Kikinis, MD; Ferenc A. Jolesz, MD; Robert W. McCarley, MD

Context: Whether psychoses associated with schizophrenia and affective disorder represent manifestations of different disorders or the same disorder is an important but unresolved question in psychiatry. Results of previous volumetric magnetic resonance imaging investigations indicate that gray matter volume reductions in neocortical regions may be specific to schizophrenia.

Objective: To simultaneously evaluate multiple olfactocentric paralimbic regions, which play crucial roles in human emotion and motivation, in first-episode patients with schizophrenia and affective psychosis.

Design: A cross-sectional study using high-spatial resolution magnetic resonance imaging in patients with schizophrenia and affective psychosis at their first hospitalization.

Setting: Inpatient units at a private psychiatric hospital.

Participants: Fifty-three first-episode patients, 27 with schizophrenia and 26 with affective (mainly manic) psychosis, and 29 control subjects.

Main Outcome Measures: Using high-spatial resolu-

tion magnetic resonance imaging, the gray matter volumes of 2 olfactocentric paralimbic regions of interest, the insular cortex and the temporal pole, were evaluated.

Results: A bilateral volume reduction in insular cortex gray matter was specific to first-episode patients with schizophrenia. In contrast, both first-episode psychosis groups showed a volume reduction in left temporal pole gray matter and an absence of normal left-greater-than-right asymmetry. Region of interest correlations showed that only patients with schizophrenia lacked a positive correlation between left temporal pole and left anterior amygdala-hippocampal complex gray matter volumes, whereas both psychosis groups were similar in lacking normal positive correlations between left temporal pole and left anterior superior temporal gyrus gray matter volumes.

Conclusions: These partially different and partially similar patterns of structural abnormalities in olfactocentric paralimbic regions and their associated abnormalities in other temporolimbic regions may be important factors in the differential and common manifestations of the 2 psychoses.

Arch Gen Psychiatry. 2003;60:1069-1077

From the Clinical Neuroscience Division, Laboratory of Neuroscience, Department of Psychiatry, Boston Veterans Affairs Healthcare System, Brockton Division, Harvard Medical School, Brockton, Mass (Drs Kasai, Shenton, Salisbury, Onitsuka, and McCarley and Ms Toner); the Surgical Planning Laboratory, MRI Division, Brigham and Women's Hospital, and the Department of Radiology, Harvard Medical School, Boston, Mass (Drs Shenton, Kikinis, and Jolesz); and the Cognitive Neuroscience Laboratory (Dr Salisbury) and the Brain Imaging Center (Dr Yurgelun-Todd), McLean Hospital, Belmont, Mass.

A LONG-STANDING but unresolved question in psychiatry is the issue of similarities and differences in brain structure between affective disorder and schizophrenia,¹ and how each group differs from healthy individuals. Our group addressed this issue by performing a series of manually delineated region of interest (ROI) magnetic resonance imaging (MRI) studies of first-episode (first hospitalization) patients with schizophrenia or affective psychosis (mainly mania) compared with control subjects.²⁻⁶ The results indicated selectively smaller gray matter volumes in first-episode schizophrenia compared with first-episode affective psychosis for the superior temporal gyrus (STG)² and its subdivisions of Heschl gyri and planum tempo-

rale,⁴ the fusiform gyrus,⁶ and the prefrontal cortex.⁵ In contrast, volume reductions were reported in both first-episode psychosis groups in the hippocampus² and the subgenual cingulate cortex (trend-level change in schizophrenia).³ Based on these limited data, neocortical (often termed *isocortical*) areas may be differentially affected in schizophrenia,⁷ but less cytoarchitecturally complex cortical regions (eg, the allocortex) may be equally reduced in affective psychosis and schizophrenia.

The temporal pole and the insula thus far have not been evaluated simultaneously with manual ROIs in MRI studies of manic and schizophrenic psychosis, although these regions are of intrinsic interest to the basis of patients' symptoms of the disorders. These paralimbic re-

gions are involved in cognitive and emotional aspects of brain function,⁸ are strongly interconnected,⁹⁻¹¹ and include less phylogenetically complex cortices. Moreover, the insula and the temporal pole are major components of what Mesulam⁸ has termed the *paralimbic zone*, which also includes the cingulate cortex, the parahippocampal cortices, and the orbitofrontal cortex. Mesulam⁸ defined the paralimbic zone partly based on location, since it constitutes an “uninterrupted girdle surrounding the medial and basal aspects of the cerebral hemispheres” and partly based on architectonic grounds. Although MRI is not capable of resolving cortical architectonics, it can detect differences in gray matter volumes of ROIs whose cortical structure has been characterized by postmortem architectonic studies; such studies have characterized the paralimbic zone as consisting of a transition between a simple allocortex, such as the hippocampus, and a fully developed, 6-layer isocortex.¹² The 2 major cytoarchitectonic divisions of the paralimbic zone are “agranular” (periallocortex, no granule cell layers) and “dysgranular” (peri-isocortex, incomplete layer 2 or 4, but more like isocortex than allocortex).⁹

The insular cortex has a crucial role in the perception and modulation of sensory and autonomic information, including pain and visceral sensation.¹³ Parts of the insula are also involved in the control of speech articulation.¹⁴ The more periallocortical anterior insula (anterior to the boundary of the central insular sulcus¹⁵) is heavily connected with the periallocortical sector of the temporal pole, the orbitofrontal cortex, and the amygdala.⁹⁻¹¹ The more peri-isocortical (granular) posterior insula has dense reciprocal connections with the somatosensory association cortex.¹⁰ Crespo-Facorro et al¹⁶ reported reduced left insular cortex gray matter volume in first-episode patients with schizophrenia, and Goldstein et al¹⁷ reported a bilateral reduction of insular gray matter volume. Moreover, recent studies¹⁸⁻²¹ using voxel-based morphometry (VBM) consistently reported reduced gray matter volume in the insular region in schizophrenia.

The temporal pole, located in the anterior tip of the temporal lobe, has a crucial role in the retrieval of episodic and semantic memory^{22,23} and in the processing of familiar and emotional stimuli such as faces.^{24,25} Similar to the insula, the temporal pole shows gradual transitions in cytoarchitecture from allocortex to mesocortex and finally to isocortex.^{8,10} The medial agranular-dysgranular part (connected primarily with olfactory and insular cortices) plays a role in olfactory-gustatory-visceral function, whereas the ventral dysgranular part (connected with the visual association cortex) is related to visual function and the dorsolateral granular part (connected with the auditory association cortex in anterior STG) is related to auditory function.^{8,10} Gur et al²⁶ reported a significant reduction in bilateral temporal pole gray matter volume in men and women with first-episode and chronic schizophrenia. In addition, the results of a VBM study¹⁸ indicated a volume reduction in bilateral temporal pole gray matter in chronic schizophrenia.

Based on these factors of interest, and the absence of previous studies with direct and simultaneous com-

parisons of the MRI structure of insula and temporal pole regions of the paralimbic brain in schizophrenia and affective psychosis using anatomically defined ROIs, the present study used high-spatial resolution MRI and anatomically defined ROIs to evaluate gray matter volumes of the temporal pole and insula in first-episode samples of schizophrenia and affective psychosis (mainly manic) and in controls. Voxel-based MRI morphometry is a potentially useful technology, but its results remain unvalidated and at times at odds with manual ROIs, as data from a recent study²⁷ suggest. Our focus on first-episode patients mitigated potential confounds of chronicity of illness and the effects of chronic treatment.

METHODS

PARTICIPANTS

Participating in the study were 53 first-episode patients with psychosis, 27 with schizophrenia (4 women) and 26 (5 women) with affective psychosis, and 29 control subjects (5 women). The affective psychosis patient group (all psychotic) included 24 patients with bipolar disorder in a manic phase and 2 with major depressive (unipolar) disorder. The statistical conclusions reported herein remained the same after the exclusion of women and when only patients with manic affective psychosis were included. Patients were recruited from the inpatient units at McLean Hospital, a private psychiatric hospital affiliated with Harvard Medical School. Control subjects were recruited through newspaper advertisements. After a complete description of the study was provided, written informed consent was obtained from all participants.

The protocols for diagnosis and clinical evaluations have previously been described in detail.^{2-6,28} Briefly, patients and controls were aged 18 to 55 years, had an estimated IQ greater than 75, were right-handed (via the Edinburgh Inventory²⁹), and had a negative history of seizures, head trauma with loss of consciousness, neurologic disorder, and any lifetime history of alcohol or other drug dependence. Control subjects were screened using the *Structured Clinical Interview for DSM-III-R, Non-Patient Edition*³⁰ by trained interviewers (D.F.S. and M.E.S.). No control subject had an Axis I or Axis II psychiatric disorder or a first-degree relative with an Axis I psychiatric disorder.

The same trained interviewers (D.F.S. and M.E.S.) diagnosed patients based on the *DSM-IV* criteria using the *Structured Clinical Interview for DSM-III-R*³¹ and information from the medical records. All diagnoses were confirmed on reinterview a minimum of 6 months after the initial hospitalization. Consistent with the literature,^{2-6,28,32,33} *first episode* was operationally defined as the first psychiatric hospitalization. Median duration of psychotropic medication use before MRI was short (**Table 1**). At the time of the first scan, patients were variously receiving no medication (2 schizophrenic and 4 affective psychosis patients), neuroleptics (typical [9 schizophrenic and 13 affective psychosis patients], atypical [12 schizophrenic and 7 affective psychosis patients], or both [3 schizophrenic and 2 affective psychosis patients]), or mood stabilizers (lithium carbonate [3 schizophrenic and 9 affective psychosis patients]), and the typical or atypical neuroleptic status for 1 schizophrenic patient was unknown owing to enrollment in a separate double-masked olanzapine/haloperidol crossover protocol.

Clinical evaluations (Table 1) included each item and 4 syndrome factors³⁴ of the Brief Psychiatric Rating Scale³⁵; the Mini-Mental State Examination³⁶; the information, digits forward, and digits backward subscales of the Wechsler Adult In-

Table 1. Demographic and Clinical Characteristics of the Study Groups*

Variable	Schizophrenic Patients (n = 27)	Affective Psychosis Patients (n = 26)	Control Subjects (n = 29)	F or t Value	df†	P Value
Age [range], y	5.2 (7.0) [18-41]	23.2 (5.0) [18-41]	24.6 (4.4) [18-35]	0.95	2,79	.39
Sex, M/F, No.	23/4	21/5	24/5	NA	NA	NA
Handedness‡	0.8 (0.2)	0.7 (0.2)	0.8 (0.2)	1.82	2,77	.17
SES§	3.4 (1.4)	2.4 (1.2)	2.2 (0.9)	8.79	2,79	<.001
Parental SES	1.9 (0.7)	1.3 (0.6)	1.6 (0.9)	3.56	2,79	.03
MMSE score	28.2 (2.4)	28.9 (1.3)	29.0 (1.2)	1.87	2,77	.16
WAIS-R score						
Information	11.6 (3.1)	12.8 (2.7)	12.2 (2.3)	1.33	2,76	.27
+ Digits forward¶	8.9 (2.5)	9.2 (2.2)	10.5 (2.3)	3.62	2,75	.03
Digits backward	6.5 (2.9)	7.0 (2.5)	8.1 (2.5)	2.70	2,75	.07
GAS score	35.9 (9.1)	42.1 (9.2)	NA	-0.90	50	.37
Total BPRS score	40.8 (12.7)	33.4 (7.6)	NA	1.39	50	.17
Medication dose (CPZ equiv), mg/d	279 (370)	209 (171)	NA	0.88	50	.38
Age first medicated [range], y	25.2 (7.0) [17-41]	22.7 (5.0) [17-40]	NA	1.42	49	.16
Duration of medication use, median (range), mo	1 (0-24)	0 (0-60)	NA	NA	NA	NA

Abbreviations: BPRS, Brief Psychiatric Rating Scale; CPZ equiv, chlorpromazine equivalent; GAS, Global Assessment Scale; MMSE, Mini-Mental State Examination; NA, not applicable; SES, socioeconomic status; WAIS-R, Wechsler Adult Intelligence Scale-Revised.

*Data are given as mean (SD) except where noted otherwise.

†The *dfs* differ among variables owing to unavailability of data for some participants.

‡Assessed using the Edinburgh Inventory,²⁹ with right-handedness being greater than 0.

§Assessed using the Hollingshead scale,³⁹ with higher scores indicating lower SES. Schizophrenic patients showed a significantly lower SES than affective psychosis patients and control subjects (Tukey honestly significant difference tests, $P < .01$).

||Schizophrenic patients showed a significantly lower parental SES than affective psychosis patients (Tukey honestly significant difference tests, $P < .05$).

¶Schizophrenic patients showed significantly lower scores than control subjects (Tukey honestly significant difference tests, $P < .05$).

telligence Scale-Revised³⁷; and the Global Assessment Scale.³⁸ Groups were not significantly different in age, sex, handedness, Mini-Mental State Examination scores, or Wechsler Adult Intelligence Scale-Revised information and digits backward scores, whereas schizophrenic patients showed significantly lower Wechsler Adult Intelligence Scale-Revised digits forward scores than control subjects. Global Assessment Scale scores, total Brief Psychiatric Rating Scale scores, medication dose, and age at first medication use were not different between the 2 psychosis groups. Schizophrenic patients showed a significantly lower socioeconomic status (SES)³⁹ than affective patients and control subjects. Schizophrenic patients also showed a significantly lower parental SES than affective patients, although the absolute difference was less than 1 SES class (difference, 0.6). Results of Mann-Whitney tests showed that schizophrenic patients had significantly higher scores on the emotional withdrawal ($Z = -2.03$; $P = .04$), suspiciousness ($Z = -2.28$; $P = .02$), hallucinatory behavior ($Z = -1.95$; $P = .05$), and blunted affect ($Z = -2.07$; $P = .04$) items than did affective psychosis patients, whereas affective psychosis patients had higher scores on the grandiosity item ($Z = -3.22$; $P = .001$) than did schizophrenic patients, consistent with the expected clinical symptom profiles.

MRI ACQUISITION AND PROCESSING

Magnetic resonance images were acquired using a 1.5-T scanner (General Electric Medical Systems, Milwaukee, Wis). The MRI acquisition protocol and the postprocessing of images have been described in detail elsewhere.⁴⁰ Briefly, a 1.5-mm-thick coronal series of contiguous spoiled gradient-recalled acquisition in the steady state (SPGR) images (repetition time, 35 milliseconds; echo time, 5 milliseconds; and voxel dimensions, $0.9375 \times 0.9375 \times 1.5$ mm) was used for delineating and measuring paralimbic regions. Second, an axial series of contiguous double-echo (proton-density and T2-weighted) images (repetition time, 3000 milliseconds; echo time, 30 and 80 millise-

conds; and voxel dimensions, $0.9375 \times 0.9375 \times 3.0$ mm) was acquired. An anisotropic diffusion filter ($k = 13$ for SPGR and 90 for proton-density and T2-weighted images, iteration = 3)⁴¹ was applied to the images to reduce noise before processing each set of scans. The intensity information from the SPGR and T2-weighted images was then used in a fully automated segmentation program to classify tissue into gray matter, white matter, and cerebrospinal fluid and to evaluate total intracranial contents (ICCs). An iterative expectation-maximization algorithm initially estimated image intensity inhomogeneities, applied intensity corrections based on these estimates, and then classified tissue based on the same set of signal intensity parameters for all participants (ie, the same segmentation map was used for all cases).⁴² Images were aligned using the line between the anterior and posterior commissures and the sagittal sulcus to correct head tilt, and they were also resampled to make voxels isotropic (sides measured, 0.9375 mm).⁴

REGIONS OF INTEREST

The insular cortex and the temporal pole ROIs were outlined manually on a workstation by individuals without knowledge of the diagnosis (**Figure 1**). The drawing of ROIs was mainly performed in the coronal plane, although we found it essential to draw on axial and sagittal planes for cases in which the borders were ambiguous on coronal slices.

For the delineation of insular cortex gray matter, we used the same criteria as Crespo-Facorro et al.^{16,43} The dorsal and ventral borders of the insular cortex were clearly defined by the superior and inferior circular insular sulci. Fusion of the superior and inferior circular insular sulci within the fundus of the Sylvian fissure was considered the posterior boundary of the insula. Since the inferior circular insular sulcus does not extend rostral to the limen insulae, the orbitoinsular sulcus was considered the inferior boundary between the anterior insular cortex and the adjacent orbitofrontal cortex. Fusion of the superior circular insular sulcus and the orbitoinsular sulcus within

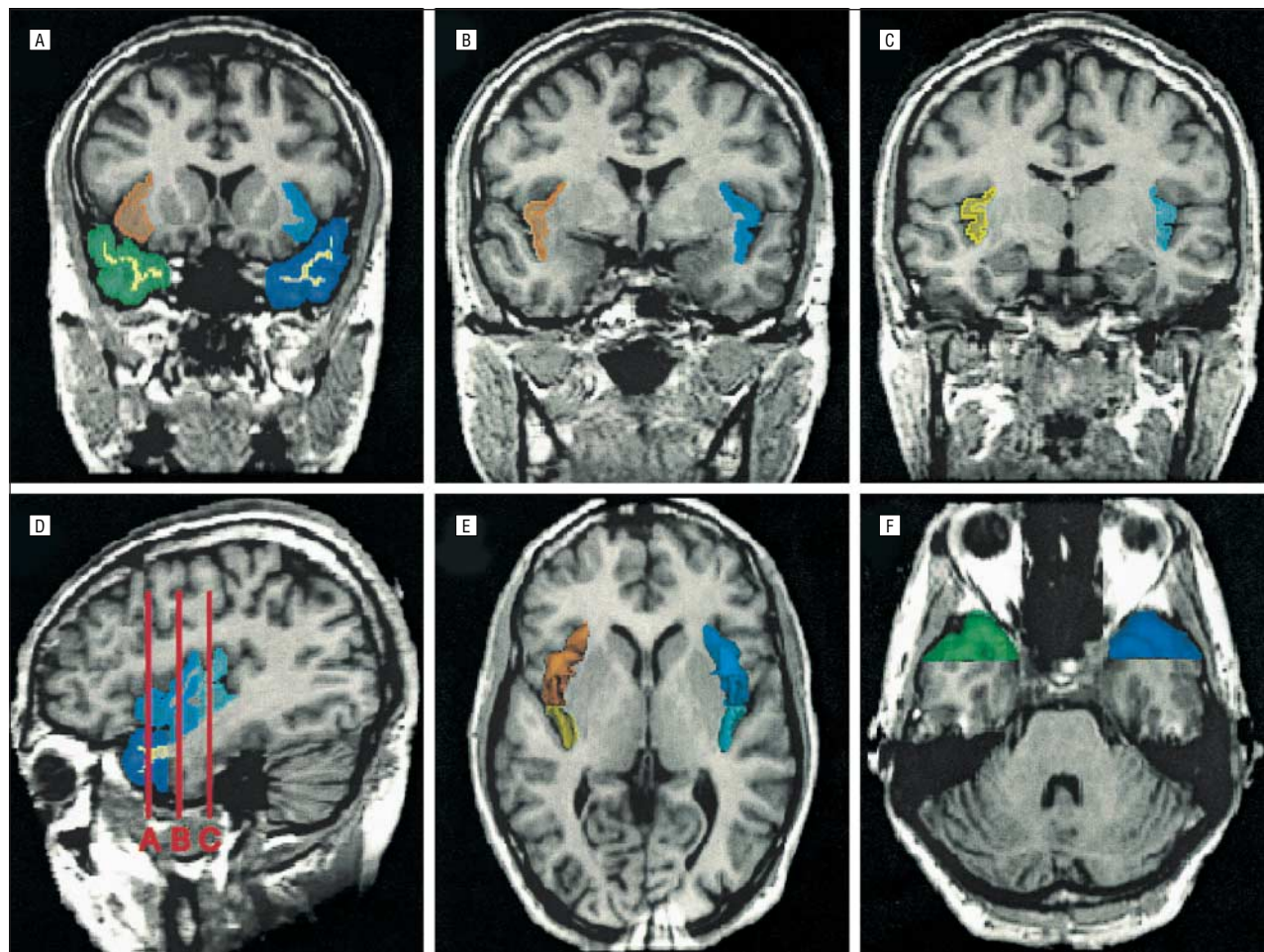


Figure 1. Two- and 3-dimensional images of paralimbic regions of interest based on magnetic resonance imaging data from a control subject. The gray matter of the anterior insular cortex is colored blue on subject left and orange on subject right. The gray matter of the posterior insular cortex is colored light blue on subject left and yellow on subject right. The white matter of the bilateral temporal pole is colored ivory. The gray matter of the temporal pole is colored purple on subject left and green on subject right. A, B, and C, Delineation of the paralimbic regions of interest on coronal slices: A shows the rostral part of the anterior insular cortex adjacent to the orbital cortex and the temporal pole; B, the caudal portion of the anterior insular cortex; and C, the middle portion of the posterior insular cortex. D, Sagittal view of the insular cortex and the temporal pole in the left hemisphere. The coronal lines A, B, and C correspond to the planes of panels A, B, and C, respectively. E and F, Three-dimensional reconstruction of insular cortex (E) and temporal pole (F) gray matter superimposed on the axial plane.

the frontal operculum was the anterior boundary of the insula. When, although rare (6 [7%] of 82 cases), neither the inferior circular insular sulcus nor the orbitoinsular sulcus could be clearly seen in a certain coronal slice, the most ventrolateral point of the insula was chosen as the inferior boundary. The lateral border was the cerebrospinal fluid, and the medial border was the white matter separating the insular gray matter and the claustrum. As the central insular sulcus anatomically divides the insular cortex into anterior and posterior portions,¹⁵ and these 2 subdivisions have differential cytoarchitectonics and connections with other structures, we sought to evaluate the anterior and posterior subdivisions separately, which Crespo-Facorro et al^{16,43} did not do. However, the central insular sulcus was not clearly delineated for all slices on either plane. Thus, we had to seek an alternative landmark for the boundary. The anterior boundary of the posterior insula was defined reliably as 1 slice caudal to the appearance of mammillary bodies. Although the central insular sulcus runs diagonally to the coronal plane, the sagittal view indicated that the anterior and posterior subdivisions included most of the sulcally defined anterior and posterior insula, respectively.

For the delineation of the temporal pole, we used the same criteria as Kim et al⁴⁴ and Crespo-Facorro et al,⁴³ which are similar to those of Gur et al.²⁶ The posterior border of the temporal

pole was defined as the coronal plane where there was no frontotemporal junction. The lateral, medial, superior, and inferior boundaries were defined simply by the natural limits of the temporal lobe, and the anterior boundary was the rostral end of the temporal lobe tissue adjacent to the sphenoid bone.

For interrater reliability, 3 raters (K.K., T.O., and S. De-meo for the insular cortex and K.K., T.O., and S.K.T. for the temporal pole), masked to group membership, independently drew ROIs. Ten cases were selected at random, and the raters edited every other slice. The intraclass correlation coefficients were 0.95 and 0.96 for left and right anterior insular gray matter, 0.95 and 0.96 for left and right posterior insular gray matter, 0.99 and 0.98 for left and right temporal pole gray matter, and 0.99 and 0.99 for left and right temporal pole white matter, respectively.

STATISTICAL ANALYSIS

Group Differences in ROI Volume

We evaluated group differences in ROIs using relative volume ([absolute ROI volume/ICCs] × 100) as the dependent variable for statistical measures; groups did not significantly differ in ICC volume (**Table 2**). The statistical conclusions re-

Table 2. Absolute and Relative Volumes of Insular Cortex Gray Matter

Region and Volume Type	Schizophrenic Patients (n = 27)		Affective Psychosis Patients (n = 26)		Control Subjects (n = 29)		1-Factor ANCOVA†			
	Mean (SD)	Effect Size*	Mean (SD)	Effect Size	Mean (SD)	Effect Size	Group Effect		Post hoc Tests	
		(95% CI†)		(95% CI†)		(95% CI†)	F _{2,78}	P Value	Group Comparison	P Value
Intracranial content, mL	1469 (114)	NA	1490 (159)	NA	1510 (162)	NA	0.47	.63	NA	NA
Left anterior insular gray matter										
Absolute, mL	4.49 (0.55)	NA	5.22 (0.59)	NA	5.24 (0.64)	NA	NA	NA	NA	NA
Relative, %	0.31 (0.03)	1.05 (-0.06, -0.02)	0.35 (0.03)	-0.05 (-0.02, 0.02)	0.35 (0.04)	NA	13.5	<.001	sz<aff = con	<.001
Right anterior insular gray matter										
Absolute, mL	4.81 (0.66)	NA	5.29 (0.60)	NA	5.34 (0.76)	NA	NA	NA	NA	NA
Relative, %	0.33 (0.04)	0.56 (-0.05, -0.01)	0.36 (0.03)	0.00 (-0.02, 0.02)	0.36 (0.05)	NA	4.13	.02	sz<aff = con	<.05
Left posterior insular gray matter										
Absolute, mL	2.32 (0.55)	NA	2.63 (0.58)	NA	2.66 (0.52)	NA	NA	NA	NA	NA
Relative, %	0.16 (0.03)	0.65 (-0.04, 0.00)	0.18 (0.03)	-0.01 (-0.02, 0.02)	0.18 (0.03)	NA	3.88	.02	sz<aff = con	<.07
Right posterior insular gray matter										
Absolute, mL	1.97 (0.46)	NA	2.29 (0.38)	NA	2.35 (0.45)	NA	NA	NA	NA	NA
Relative, %	0.13 (0.03)	0.84 (-0.04, -0.01)	0.15 (0.02)	0.06 (-0.01, 0.01)	0.16 (0.03)	NA	6.43	.003	sz<aff = con	<.05

Abbreviations: aff, affective psychosis patients; ANCOVA, analysis of covariance; CI, confidence interval; con, control subjects; NA, not applicable; sz, schizophrenic patients.

*Calculated based on relative volume.

†The 95% CI of the difference between the patient group and the control group. Calculated based on relative volume.

‡Parental socioeconomic status was used as the covariate. Tukey honestly significant difference tests were used for post hoc tests. The results reported herein are based on relative volumes. Using absolute volume as the dependent variable and intracranial content as the covariate did not alter the statistical conclusions.

ported herein remained the same when we used analysis of covariance (ANCOVA), with absolute volume as the dependent variable and ICC as the covariate. For group comparison of the insular cortex, a repeated-measures ANCOVA was performed, with group (schizophrenic, affective, or control) as the between-subjects factor and subdivision (anterior or posterior) and side (left or right) as the within-subjects factors. For group comparison of the temporal pole, a repeated-measures ANCOVA was performed, with group as the between-subjects factor and tissue (gray matter or white matter) and side as the within-subjects factors. As the schizophrenia group showed a slightly but statistically significantly lower parental SES than the affective psychosis group, parental SES was used as the covariate for all ANCOVAs.

Correlation With Clinical Measures

Spearman ρ was used in an exploratory analysis of the correlations between the volumes of each ROI and clinical measures for both psychosis groups. For determining statistical significance, a Bonferroni correction for multiple correlations (8 ROIs \times 28 clinical measures \times 2 groups = 448 correlations) was used.

Correlation Among ROIs

First, Pearson product-moment correlation coefficients were calculated in the analyses of the relationships among volumes of paralimbic ROIs and previously reported gray matter volumes of temporolimbic structures in control subjects. Based on anatomic connectivity, we hypothesized that in control subjects there would be significant positive correlations among gray matter volumes of the temporal pole, anterior insula, anterior amygdala-hippocampal complex (mostly amygdala), and anterior STG for each hemisphere. We considered $P \leq .05$ to be statistically significant because of our

hypothesis-driven approach, and we conservatively used 2-tailed tests. However, we also computed Bonferroni corrections for multiple correlations (10 correlations, hence level for significance was $P \leq .005$). These corrections did not alter the statistical conclusions because all significant results were $P \leq .001$. The values reported herein were those based on absolute volumes, but the correlations were also significant for relative volumes.

We then tested whether there were any alterations in the positive normal relationships between ROI volumes in the psychosis groups using the Fisher Z transformation. For the latter analyses, we report data based on absolute volumes and, again, consider $P \leq .05$ as the significance level (all reported values were also significant at $P \leq .05$ using relative volumes).

RESULTS

Age, SES, parental SES, age of first medication use, duration of medication use, dose of medication, and ICC volume did not correlate with any of the ROI volumes for any group.

GROUP COMPARISONS OF INSULAR CORTEX VOLUME

Groups were significantly different in overall insular gray matter volume ($F_{2,78} = 18.7$; $P < .001$). The anterior subdivision showed larger volumes than the posterior subdivision for all groups ($F_{1,78} = 216$; $P < .001$). There was no hemispheric difference in overall volume ($F_{1,78} = 1.01$; $P = .32$), but a significant subdivision \times side interaction ($F_{1,78} = 9.10$; $P = .003$) indicated that the hemispheric lateralization differed for each subdivision for all groups. A separate analysis for each subdivision showed no asym-

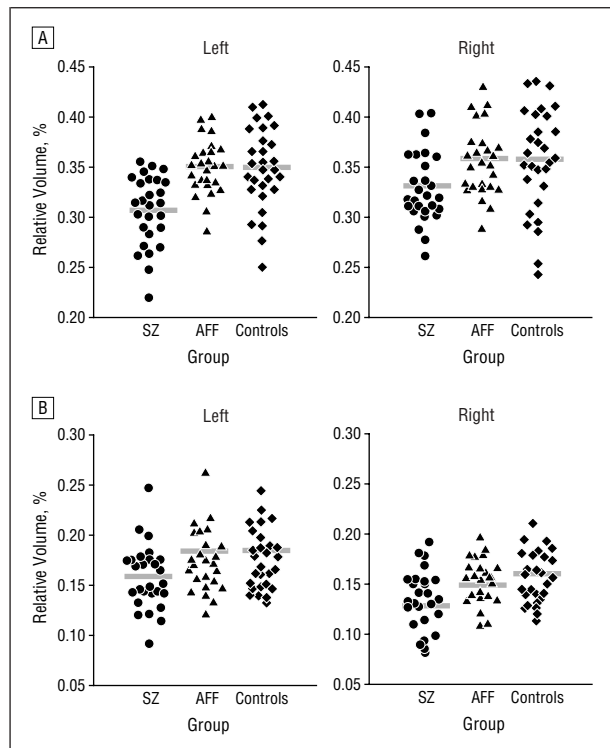


Figure 2. Relative gray matter volumes of the anterior (A) and posterior (B) insular cortex subregions in first-episode patients with schizophrenia (SZ) (n=27), first-episode patients with affective psychosis (AFF) (n=26), and control subjects (n=29). Horizontal lines indicate means.

metry in the anterior subdivision ($F_{1,78}=2.64$; $P=.11$) but a significant left-larger-than-right asymmetry in the posterior subdivision ($F_{1,78}=9.89$; $P=.002$) for all groups.

The lack of a group \times subdivision ($F_{2,78}=0.816$; $P=.45$), group \times side ($F_{2,78}=1.31$; $P=.28$), or group \times subdivision \times side ($F_{2,78}=1.29$; $P=.28$) interaction indicated that group differences were not localized to a particular subregion (**Figure 2**). To investigate the main effect of group on insular gray matter volume, we next compared each pair of groups. The results revealed that overall insular gray matter volume was significantly smaller in patients with schizophrenia compared with patients with affective psychosis ($F_{1,50}=38.1$; $P<.001$) and control subjects ($F_{1,53}=24.3$; $P<.001$), whereas there were no significant differences between patients with affective psychosis and the control group ($F_{1,52}=0.005$; $P=.95$).

GROUP COMPARISONS OF TEMPORAL POLE VOLUME

Groups were significantly different in overall temporal pole volume ($F_{2,78}=3.15$; $P=.048$) (**Table 3**). Gray matter volume was larger than white matter volume for all groups ($F_{1,78}=882$; $P<.001$). There was no hemispheric difference in overall temporal pole volume ($F_{1,78}=1.07$; $P=.30$). Significant group \times tissue ($F_{2,78}=6.20$; $P=.003$), group \times side ($F_{2,78}=7.21$; $P=.001$), and group \times tissue \times side ($F_{2,78}=12.9$; $P<.001$) interactions indicated that group differences were

Table 3. Absolute and Relative Volumes of Temporal Pole Gray and White Matter

Region and Volume Type	Schizophrenic Patients (n = 27)		Affective Psychosis Patients (n = 26)		Control Subjects (n = 29)		Group Comparison†			
	Mean (SD)	Effect Size* (95% CI†)	Mean (SD)	Effect Size (95% CI†)	Mean (SD)	Effect Size	Group Effect		Post hoc Tests	
							F	P Value	Group Comparison	P Value
Temporal Pole Gray Matter										
Left										
Absolute, mL	8.28 (1.36)	NA	8.84 (1.45)	NA	9.95 (1.39)	NA	NA	NA	NA	NA
Relative, %	0.56 (0.09)	1.19 (-0.14, -0.05)	0.59 (0.08)	0.84 (-0.11, -0.02)	0.66 (0.08)	NA	9.87	<.001	sz = aff < con	<.01
Right										
Absolute, mL	8.23 (1.53)	NA	8.73 (1.57)	NA	8.90 (1.20)	NA	NA	NA	NA	NA
Relative, %	0.56 (0.10)	0.39 (-0.08, -0.02)	0.59 (0.08)	0.09 (-0.05, 0.04)	0.59 (0.08)	NA	0.86	.43	NA	NA
Laterality Index, %§	0.40 (5.59)	1.14 (-7.88, -2.43)	0.66 (5.33)	1.08 (-7.57, -2.23)	5.56 (4.54)	NA	8.94	<.001	sz = aff < con	<.005
Temporal Pole White Matter										
Left										
Absolute, mL	1.27 (0.39)	NA	1.35 (0.40)	NA	1.42 (0.50)	NA	NA	NA	NA	NA
Relative, %	0.09 (0.03)	0.24 (-0.02, 0.01)	0.09 (0.02)	0.12 (-0.02, 0.01)	0.09 (0.03)	NA	0.55	.58	NA	NA
Right										
Absolute, mL	1.28 (0.43)	NA	1.31 (0.46)	NA	1.31 (0.45)	NA	NA	NA	NA	NA
Relative, %	0.09 (0.03)	-0.01 (-0.02, 0.02)	0.09 (0.03)	-0.01 (-0.01, 0.02)	0.09 (0.03)	NA	0.043	.96	NA	NA

Abbreviations: aff, affective psychosis patients; CI, confidence interval; con, control subjects; NA, not applicable; sz, schizophrenic patients.

*Calculated based on relative volume.

†The 95% CI of the difference between the patient group and the control group. Calculated based on relative volume.

‡One-factor analyses of covariance with parental socioeconomic status as the covariate were used except for the laterality index of temporal pole gray matter volume, for which 1-factor analysis of variance was used. The df was 2,78 for 1-factor analyses of covariance and 2,79 for the 1-factor analysis of variance. Tukey honestly significant difference tests were used for post hoc tests. The results reported herein are based on relative volumes. Using absolute volume as the dependent variable and intracranial content as the covariate did not alter the statistical conclusions.

§Calculated by the following formula: $100 \times [(gray\ matter\ volume\ of\ the\ left\ temporal\ pole) - (that\ of\ the\ right)] / (left + right)$.

confined to a particular tissue on one side. We thus next evaluated group differences separately for each tissue type.

For temporal pole white matter, groups were not significantly different in volume ($F_{2,78}=0.129$; $P=.88$), and group differences were not focal to 1 hemisphere (group \times side interaction: $F_{2,78}=0.943$; $P=.39$) (**Figure 3**). In contrast, groups were significantly different in gray matter volume of the temporal pole ($F_{2,78}=4.41$; $P=.02$), and this effect differed between hemispheres (group \times side interaction: $F_{2,78}=10.1$; $P<.001$). The follow-up 1-factor ANCOVA showed that group differences were present in the left temporal pole gray matter volume ($F_{2,78}=9.87$; $P<.001$) but not in the right temporal pole gray matter ($F_{2,78}=0.86$; $P=.43$). Results of post hoc Tukey honestly significant difference tests indicated that patients with schizophrenia ($P<.001$) and those with affective psychosis ($P=.009$) had a significantly smaller left temporal pole gray matter volume than control subjects, with no significant difference between the 2 psychosis groups ($P=.43$). In addition, given a significant group \times side interaction for temporal pole gray matter, we further evaluated group differences in the hemispheric asymmetry of temporal pole gray matter. A separate analysis for each group showed that control subjects had a significant left-larger-than-right asymmetry in the temporal lobe gray matter volume ($F_{1,27}=12.0$; $P=.002$), whereas hemispheric difference was not evident for the schizophrenia ($F_{1,25}=2.35$; $P=.14$) or affective psychosis ($F_{1,24}=1.87$; $P=.18$) groups. The comparison of the laterality index (calculated by the following formula: $100 \times [\text{left} - \text{right}] / [\text{left} + \text{right}]$) also showed that groups were significantly different in the laterality of temporal pole gray matter ($F_{2,79}=8.94$; $P<.001$), with the control group showing statistically significantly greater leftward lateralization than the 2 psychosis groups (Tukey honestly significant difference tests, $P<.005$).

CORRELATIONS BETWEEN ROI VOLUMES AND CLINICAL MEASURES

In both patient groups, ROI volumes were not significantly associated with total or factor scores on the Brief Psychiatric Rating Scale, any Brief Psychiatric Rating Scale item, the Mini-Mental State Examination, subscales of the Wechsler Adult Intelligence Scale–Revised, or the Global Assessment Scale (all ρ values were between -0.361 and $+0.374$ [$P \geq .06$ for all]).

CORRELATIONS AMONG ROIS

In control subjects, we found a significant relationship between gray matter volumes of the left temporal pole and the left anterior STG ($R=0.918$; $P<.001$) and between the left temporal pole and the left anterior amygdala-hippocampal complex ($R=0.758$; $P<.001$). Schizophrenic patients lacked a significant correlation between left temporal pole and left anterior amygdala-hippocampal complex gray matter volumes; this was significantly different from affective psychosis ($Z=-2.16$; $P=.04$) and control subjects ($Z=-2.76$; $P=.006$), who showed significant correlations. In contrast, schizophrenic ($Z=-4.35$; $P<.001$) and affective

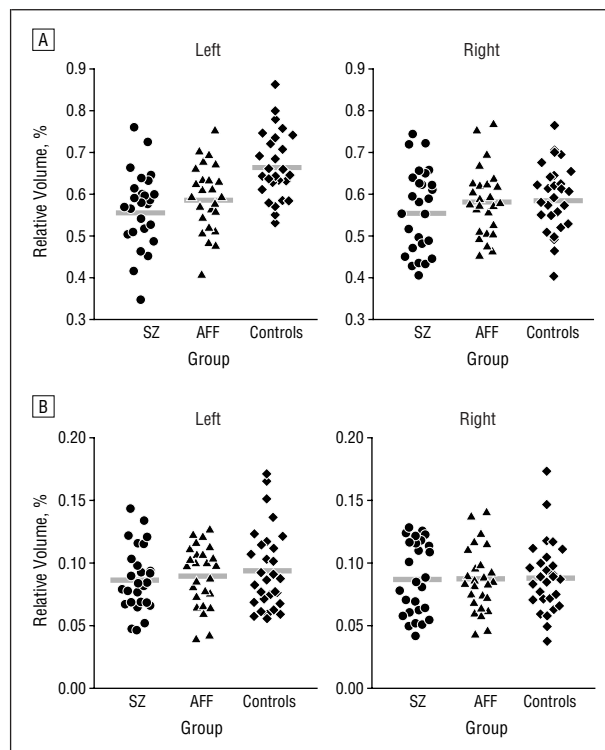


Figure 3. Relative volumes of temporal pole gray (A) and white (B) matter in first-episode patients with schizophrenia (SZ) ($n=27$), first-episode patients with affective psychosis (AFF) ($n=26$), and control subjects ($n=29$). Horizontal lines indicate means.

psychosis ($Z=-3.89$; $P<.001$) patients lacked a significant correlation between left temporal pole and left anterior STG gray matter volumes; this was significantly different from control subjects, who showed a significant correlation.

COMMENT

To our knowledge, this study is the first to directly compare volumes of multiple olfactocentric paralimbic regions between first-episode patients with schizophrenia or affective psychosis and controls. Bilateral insular cortex gray matter volumes were significantly reduced in first-episode patients with schizophrenia compared with first-episode patients with affective psychosis and control subjects. In contrast, first-episode patients with schizophrenia and those with affective psychosis showed a significant volume reduction in left temporal pole gray matter and an absence of normal left-greater-than-right temporal pole asymmetry. There were similarities and differences between the 2 psychoses in the relationship of the left temporal pole to other temporolimbic structures.

As further discussed in the following paragraphs, these results lend support to the tentative hypothesis that MRI gray matter abnormalities common to both psychoses tend to be in regions associated with the processing of emotion (such as the temporal pole), whereas regions not so closely linked to emotion processing (such as the insula) and linked to more purely sensory processing seem to be more specific to schizophrenia.

We thus conclude that in our study, insular cortex gray matter volume reduction was specific to first-episode schizophrenia. Moreover, this study found no abnormal lateralization in the insular cortex for either the anterior or posterior subdivisions, thus indicating widespread gray matter volume reduction in the insular region in schizophrenic patients at first hospitalization. Reduced functional MRI signals during a verbal fluency task⁴⁵ and reduced positron emission tomography activations during a recognition task of a novel word list⁴⁶ and during the experience of unpleasant odors⁴⁷ have been observed in the insular cortex in patients with schizophrenia. In addition, a study⁴⁸ of 2 patients with insular lesions observed that the resection of the lesions cured partial seizures with somatic and visceral hallucinations, further suggesting the importance of these regions to this symptom.

Left temporal pole reduction was common to schizophrenia and affective psychosis. Our finding of temporal pole gray matter volume reduction in first-episode schizophrenia replicates previous in vivo anatomically defined,²⁶ voxel-based,¹⁸ and postmortem⁴⁹ morphometric studies in schizophrenia, although our study reported left-lateralized reduction, whereas the previous studies reported bilateral reduction. The finding of common volume reduction to the 2 psychoses is also similar to the previous finding of left posterior amygdala-hippocampal complex volume reduction in first-episode patients with schizophrenia and affective psychosis and to the finding³ of a significant subgenual cingulate cortex volume reduction in patients with family history-positive psychotic affective disorder and a trend toward a significant reduction in patients with schizophrenia.

Our results bear on the important questions of whether schizophrenia is a disorder of particular isocortical regions⁷ or whether the schizophrenic and affective psychoses are clearly differentiated by the cytoarchitectonics of affected cortical areas. Our results suggest that anterior (more allocortical) and posterior (more isocortical) insulae were selectively reduced in schizophrenia, whereas volume reductions in the temporal pole (mixture of allocortical and isocortical sectors) are common to both psychoses.

Thus, schizophrenia does not seem to be strictly limited to a category of one type of affected cortex, although the trend is for schizophrenia to show a pattern of more selective abnormality (vs affective psychosis) in the isocortex (for review of affected areas, see McCarley et al⁵⁰ and Shenton et al⁵¹).

Abnormalities in affective psychosis, with reductions in temporal pole, amygdala-hippocampus, and the emotion-processing region of cingulate cortex (subgenual cortex), may reflect a pattern of abnormalities in cortical regions important for the processing of emotions and for giving emotional valence to memories rather than reflecting a strict architectonic differentiation. In schizophrenia, these regions also may be affected, but what is apparently unique to schizophrenic psychosis is the involvement of the primary sensory processing cortex (eg, Heschl gyri in the auditory system and the insular cortex for visceral sensation) and cortex specialized for other functions, such as for language production and speech articulation (eg, the planum temporale and the anterior insula).

The absence of a positive correlation between left temporal pole and left anterior amygdala-hippocampal complex gray matter volumes in the schizophrenia group suggests that in contrast to affective psychosis, parts of this emotion-related system are not uniformly affected. That both psychosis groups lacked normal positive correlations between left temporal pole and left anterior STG gray matter volumes may reflect differential abnormalities in both groups of the isocortical anterior STG and the more cytoarchitectonically diverse and emotion-related temporal pole.

Some methodological issues in this study need to be commented on. First, we used VBM in a subset of the present participants.²⁷ However, as pointed out in that article, some VBM findings were inconsistent with manual ROI findings. In that article, one of the few systematic comparisons of VBM and manual ROIs in the literature, the data led us to conclude that VBM is not ready for adoption as the sole method for assessing ROI and that further work is needed to understand the reasons for the VBM differences from the manual ROIs, the current gold standard. Second, the absence of structural change in some ROIs is valid only for this period in the course of the illness. The literature suggests that ventricular size may increase with chronicity (cross-sectional study of first-episode and chronic bipolar illness⁵²), and it is possible, although not demonstrated herein, that other ROIs may also change. Our planned longitudinal study will help answer this question.

In conclusion, the patterns of structural abnormalities in olfactocentric paralimbic regions and their associated abnormalities in other temporolimbic regions may be important factors in the differential and common manifestations of the 2 psychoses.

Submitted for publication October 19, 2001; final revision received April 30, 2003; accepted May 5, 2003.

This study was supported in part by Merit Awards (Drs Shenton and McCarley) and a Middleton Award (Dr McCarley) from the Department of Veterans Affairs, Washington, DC; grants K02 MH 01110 and R01 MH 50747 (Dr Shenton), R01 MH 40799 (Dr McCarley), R01 RR 11747 (Dr Kikinis), and P41 PR13218 (Dr Jolesz) from the National Institutes of Health, Bethesda, Md; the MIND Institute, Albuquerque, NM (Dr McCarley); the Welfide Medicinal Research Foundation, Osaka, Japan (Dr Kasai); and the Uehara Memorial Foundation, Tokyo, Japan (Dr Kasai).

We thank Marie Fairbanks for her administrative support and Susan Demeo, BA, Carlye Griggs, BA, and Magdalena Spencer, BS, for their research assistant support.

Corresponding authors and reprints: Robert W. McCarley, MD, and Martha E. Shenton, PhD, Department of Psychiatry (116A), Boston Veterans Affairs Healthcare System, Brockton Division, Harvard Medical School, 940 Belmont St, Brockton, MA 02301 (e-mail: robert_mccarley@hms.harvard.edu and martha_shenton@hms.harvard.edu).

REFERENCES

1. Baumann B, Bogerts B. The pathomorphology of schizophrenia and mood disorders: similarities and differences. *Schizophr Res.* 1999;39:141-148.
2. Hirayasu Y, Shenton ME, Salisbury DF, Dickey CC, Fisher IA, Mazzone P, Kisler

- T, Aarakaki H, Kwon JS, Anderson JE, Yurgelun-Todd D, Tohen M, McCarley RW. Lower left temporal lobe MR volumes in patients with first-episode schizophrenia compared with psychotic patients with first-episode affective disorder and normal subjects. *Am J Psychiatry*. 1998;155:1384-1391.
3. Hirayasu Y, Shenton ME, Salisbury DF, Kwon JS, Wible CG, Fischer IA, Yurgelun-Todd D, Zarate C, Kikinis R, Jolesz FA, McCarley RW. Subgenual cingulate cortex volume in first-episode psychosis. *Am J Psychiatry*. 1999;156:1091-1093.
 4. Hirayasu Y, McCarley RW, Salisbury DF, Tanaka S, Kwon JS, Frumin M, Snyderman D, Yurgelun-Todd D, Kikinis R, Jolesz FA, Shenton ME. Planum temporale and Heschl gyrus volume reduction in schizophrenia. *Arch Gen Psychiatry*. 2000;57:692-699.
 5. Hirayasu Y, Tanaka S, Shenton ME, Salisbury DF, DeSantis MA, Levitt JJ, Wible C, Yurgelun-Todd D, Kikinis R, Jolesz FA, McCarley RW. Prefrontal gray matter volume reduction in first-episode schizophrenia. *Cereb Cortex*. 2001;11:374-381.
 6. Lee CU, Shenton ME, Salisbury DF, Kasai K, Onitsuka T, Dickey CC, Yurgelun-Todd D, Kikinis R, Jolesz FA, McCarley RW. Fusiform gyrus volume reduction in first-episode schizophrenia: an MRI study. *Arch Gen Psychiatry*. 2002;59:775-781.
 7. Pearlson GD, Petty RG, Ross CA, Tien AY. Schizophrenia: a disease of heteromodal association cortex? *Neuropsychopharmacology*. 1996;14:1-17.
 8. Mesulam MM. Paralimbic (mesocortical) areas. In: Mesulam MM, ed. *Principles of Behavioral and Cognitive Neurology*. New York, NY: Oxford University Press; 2000:49-54.
 9. Mesulam MM, Mufson EJ. The insula of Reil in man and monkey: architectonics, connectivity, and function. In: Peters A, Jones EG, eds. *Cerebral Cortex*. Vol 4. New York, NY: Plenum Press; 1985:179-226.
 10. Gloor P. Multiple associate areas in the primate temporal lobe and its vicinity and their connections. In: *The Temporal Lobe and Limbic System*. New York, NY: Oxford University Press; 1997:218-239.
 11. Mega MS, Cummings JL. Frontal subcortical circuits: anatomy and function. In: Salloway SP, Malloy PF, Duffy JD, eds. *The Frontal Lobes and Neuropsychiatric Illness*. Washington, DC: American Psychiatric Publishing; 2001:15-32.
 12. Cerebral cortex. In: Afifi AK, Bergman RA. *Functional Neuroanatomy*. New York, NY: McGraw-Hill Co; 1998:338-343.
 13. Augstine JR. Circuitry and functional aspects of the insular lobe in primates including humans. *Brain Res Rev*. 1996;22:229-244.
 14. Dronkers NF. A new brain region for coordinating speech articulation. *Nature*. 1996;384:159-161.
 15. Türe U, Yasargil DCH, Al-Mefty O, Yasargil MG. Topographic anatomy of the insular region. *J Neurosurg*. 1999;90:720-733.
 16. Crespo-Facorro B, Kim JJ, Andreasen NC, O'Leary DS, Bockholt HJ, Magnotta V. Insular cortex abnormalities in schizophrenia: a structural magnetic resonance imaging study of first-episode patients. *Schizophr Res*. 2000;46:35-43.
 17. Goldstein JM, Goodman JM, Seidman LJ, Kennedy DN, Makris N, Lee H, Tourville J, Caviness VS Jr, Faraone SV, Tsuang MT. Cortical abnormalities in schizophrenia identified by structural magnetic resonance imaging. *Arch Gen Psychiatry*. 1999;56:537-547.
 18. Wright IC, Ellison ZR, Sharma T, Friston KJ, Murray RM, McGuire PK. Mapping of grey matter changes in schizophrenia. *Schizophr Res*. 1999;35:1-14.
 19. Paillère-Martinot ML, Caclin A, Artiges E, Poline JB, Joliot M, Mallet L, Recasens C, Attar-Lévy D, Martinot JL. Cerebral gray and white matter reductions and clinical correlates in patients with early onset schizophrenia. *Schizophr Res*. 2001;50:19-26.
 20. Sigmundsson T, Suckling J, Maier M, Williams SCR, Bullmore ET, Greenwood KE, Fukuda R, Ron MA, Toone BK. Structural abnormalities in frontal, temporal, and limbic regions and interconnecting white matter tracts in schizophrenic patients with prominent negative symptoms. *Am J Psychiatry*. 2001;158:234-243.
 21. Wilke M, Kaufmann C, Grabner A, Pütz B, Wetter TC, Auer DP. Gray matter changes and correlates of disease severity in schizophrenia: a statistical parametric mapping study. *Neuroimage*. 2001;13:814-824.
 22. Markowitsch HJ. Which brain regions are critically involved in the retrieval of old episodic memory? *Brain Res Rev*. 1995;21:117-127.
 23. Grabowski TJ, Damasio H, Tranel D, Boles Ponto LL, Hichwa RD, Damasio AR. A role for left temporal pole in the retrieval of words for unique entities. *Hum Brain Mapp*. 2001;13:199-212.
 24. Blair RJR, Morris JS, Frith CD, Perrett DI, Dolan RJ. Dissociable neural responses to facial expressions of sadness and anger. *Brain*. 1999;122:883-893.
 25. Sugiura M, Kawashima R, Nakamura K, Sato N, Nakamura A, Kato T, Hatano K, Schormann T, Zilles K, Sato K, Ito K, Fukuda H. Activation reduction in anterior temporal cortices during repeated recognition of faces of personal acquaintances. *Neuroimage*. 2001;13:877-890.
 26. Gur RE, Turetsky BI, Cowell PE, Finkelman C, Maany V, Grossman RI, Arnold SE, Bilker WB, Gur RC. Temporolimbic volume reductions in schizophrenia. *Arch Gen Psychiatry*. 2000;57:769-775.
 27. Kubicki M, Shenton ME, Salisbury DF, Hirayasu Y, Kasai K, Kikinis R, Jolesz FA, McCarley RW. Voxel-based morphometric analysis of gray matter in first episode schizophrenia. *Neuroimage*. 2002;17:1711-1719.
 28. Salisbury DF, Shenton ME, Sherwood AR, Fischer IA, Yurgelun-Todd DA, Tohen M, McCarley RW. First-episode schizophrenic psychosis differs from first-episode affective psychosis and controls in P300 amplitude over left temporal lobe. *Arch Gen Psychiatry*. 1998;55:173-180.
 29. Oldfield RC. The assessment and analysis of handedness: the Edinburgh Inventory. *Neuropsychologia*. 1971;9:97-113.
 30. Spitzer RL, Williams JBW, Gibbon M, First M. *The Structured Clinical Interview for DSM-III-R, Non-Patient Edition (SCID-NP)*. Washington, DC: American Psychiatric Association; 1990.
 31. Spitzer RL, Williams JBW, Gibbon M, First M. *The Structured Clinical Interview for DSM-III-R (SCID)*. Washington, DC: American Psychiatric Association; 1990.
 32. DeLisi LE, Sakuma M, Tew W, Kushner M, Hoff AL, Grimson R. Schizophrenia as a chronic active brain process: a study of progressive brain structural change subsequent to the onset of schizophrenia. *Psychiatry Res*. 1997;74:129-140.
 33. Lieberman JA, Chakos M, Wu H, Alvir J, Hoffman E, Robinson D, Bilder R. Longitudinal study of brain morphology in first episode schizophrenia. *Biol Psychiatry*. 2001;49:487-499.
 34. Overall JE, Hollister LE, Pichot P. Major psychiatric disorders: a four-dimensional model. *Arch Gen Psychiatry*. 1967;16:146-151.
 35. Overall JE, Gorham DR. The Brief Psychiatric Rating Scale. *Psychol Rep*. 1962;10:799-812.
 36. Folstein MF, Folstein SE, McHugh PR. "Mini-Mental State": a practical method for grading the cognitive state of patients for the clinician. *J Psychiatr Res*. 1975;12:189-198.
 37. Wechsler D. *Wechsler Adult Intelligence Scale-Revised*. New York, NY: Harcourt Brace Jovanovich Publishers; 1981.
 38. Endicott J, Spitzer RL, Fleiss JL, Cohen J. The Global Assessment Scale: a procedure for measuring overall severity of psychiatric disturbance. *Arch Gen Psychiatry*. 1976;33:766-771.
 39. Hollingshead AB. *Two Factor Index of Social Position*. New Haven, Conn: Yale University Press; 1965.
 40. Wible CG, Shenton ME, Hokama H, Kikinis R, Jolesz FA, Metcalf D, McCarley RW. Prefrontal cortex and schizophrenia: a quantitative magnetic resonance imaging study. *Arch Gen Psychiatry*. 1995;52:279-288.
 41. Gerig G, Kubler O, Kikinis R, Jolesz FA. Nonlinear anisotropic filtering of MRI data. *IEEE Trans Med Imaging*. 1992;11:221-232.
 42. Wells WM III, Grimson WEL, Kikinis R, Jolesz FA. Adaptive segmentation of MRI data. *IEEE Trans Med Imaging*. 1996;15:429-442.
 43. Crespo-Facorro B, Kim JJ, Andreasen NC, Spinks R, O'Leary DS, Bockholt HJ, Harris G, Magnotta VA. Cerebral cortex: a topographic segmentation method using magnetic resonance imaging. *Psychiatry Res*. 2000;100:97-126.
 44. Kim JJ, Crespo-Facorro B, Andreasen NC, O'Leary DS, Zhang B, Harris G, Magnotta VA. An MRI-based parcellation method for the temporal lobe. *Neuroimage*. 2000;11:271-288.
 45. Curtis VA, Bullmore ET, Brammer MJ, Wright IC, Williams SCR, Morris RG, Sharma TS, Murray RM, McGuire PK. Attenuated frontal activation during a verbal fluency task in patients with schizophrenia. *Am J Psychiatry*. 1998;155:1056-1063.
 46. Crespo-Facorro B, Wiser AK, Andreasen NC, O'Leary DS, Watkins GL, Boles Ponto LL, Hichwa RD. Neural basis of novel and well-learned recognition memory in schizophrenia: a positron emission tomography study. *Hum Brain Mapp*. 2001;12:219-231.
 47. Crespo-Facorro B, Paradiso S, Andreasen NC, O'Leary DS, Watkins GL, Ponto LLB, Hichwa RD. Neural mechanisms of anhedonia in schizophrenia: a PET study of response to unpleasant and pleasant odors. *JAMA*. 2001;286:427-435.
 48. Roper SN, Lévesque MF, Sutherland WW, Engel J Jr. Surgical treatment of partial epilepsy arising from the insular cortex: report of two cases. *J Neurosurg*. 1993;79:266-269.
 49. Highley JR, McDonald B, Walker MA, Esiri MM, Crow TJ. Schizophrenia and temporal lobe asymmetry: a post-mortem stereological study of tissue volume. *Br J Psychiatry*. 1999;175:127-134.
 50. McCarley RW, Wible CG, Frumin M, Hirayasu Y, Levitt JJ, Fischer IA, Shenton ME. MRI anatomy of schizophrenia. *Biol Psychiatry*. 1999;45:1099-1119.
 51. Shenton ME, Dickey CC, Frumin M, McCarley RW. A review of MRI findings in schizophrenia. *Schizophr Res*. 2001;49:1-52.
 52. Strakowski SM, DelBello MP, Zimmerman ME, Getz GE, Mills NP, Ret J, Shear P, Adler CM. Ventricular and periventricular structural volumes in first- versus multiple-episode bipolar disorder. *Am J Psychiatry*. 2002;159:1841-1847.