

DTI Atlas Building – Santa Fe

- Casey Goodlett, Guido Gerig

Overview

- ◆ Algorithm [1]
- ◆ Inputs
- ◆ Geometry of atlas fibers
- ◆ Diffusion statistics
- ◆ Results, conclusions, and thoughts

Inputs

- ◆ Larger data set
- ◆ Image data
 - ◆ Scanner resolution
 - ◆ No distortion correction

Preprocessing

- ◆ Tensor estimation – DTIPProcess from NeuroLib
 - ◆ Weighted least squares (3 iterations)
 - ◆ Background threshold 350
 - ◆ Time: 3-4 minutes per
- ◆ FA/MD/Color FA computation using DTIPProcess
- ◆ Maximum eigenvalue image (sigma = 4.5 mm)
- ◆ ~minutes per-image, Xeon dual-core w/ 2GB (Memory is limiting factor for processing)

Registration

- ◆ Average baseline image registered to T2 atlas
 - ◆ RView
 - ◆ Cross-Correlation
 - ◆ 3 resolution levels
- ◆ Affine registration used as initialization for fluid registration (Joshi, Davis) [2]
 - ◆ Multi-resolution (3 levels)
 - ◆ Runs in ~15 minutes on 8 core machine 64 GB RAM

Fiber Tracking

- ◆ Computed on atlas tensor image
- ◆ ROIs redrawn in atlas based on sample ROIs
 - ◆ InsightSNAP 1.5.4 with FA and/or Color FA images
 - ◆ Arcuate drawn based on Susumu Mori's atlas
- ◆ FiberTracking 2.3.1 used with default parameters

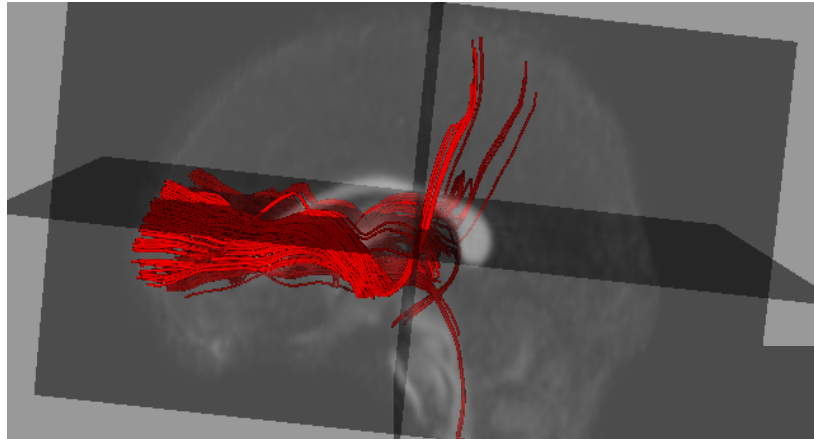
Collection of Diffusion Statistics

- ◆ FiberViewer 1.2.3 used for clustering/analysis
- ◆ Fiber process command line tool in DTIProcess
- ◆ For each point in atlas bundle lookup data from individual image
- ◆ For each bundle project collected data onto 1-d curve via arc-length parameterization. Median of data in cross-section
 - ◆ FA
 - ◆ MD

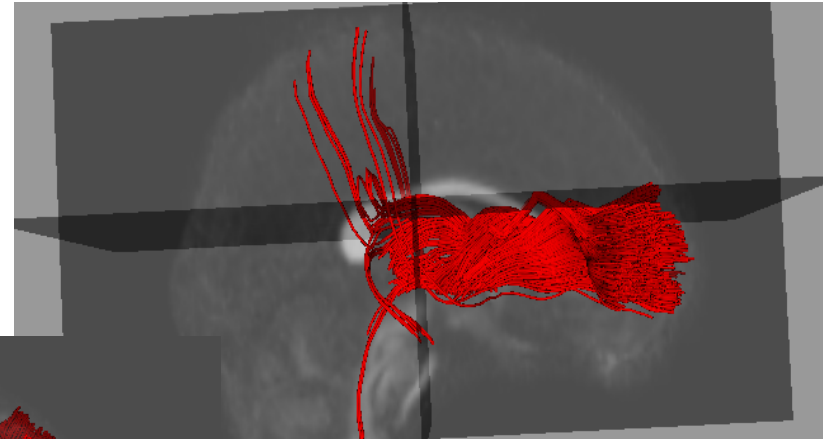
Analysis of Tract Statistics

- ◆ FiberViewer used to reduce each individual fiber bundle to 1-d function (median statistic)
- ◆ Population (N images) collected into spreadsheet NxM (m == # of samples along tract)
- ◆ Analysis done using scipy, numpy
- ◆ Functional Data Analysis [3]
 - ◆ Smoothing
 - ◆ PCA
 - ◆ point-wise tests (multiple comparison correction)

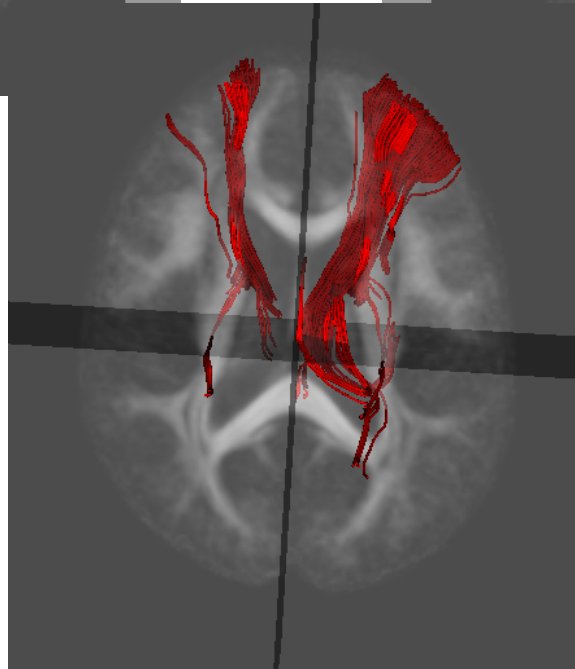
Internal Capsule



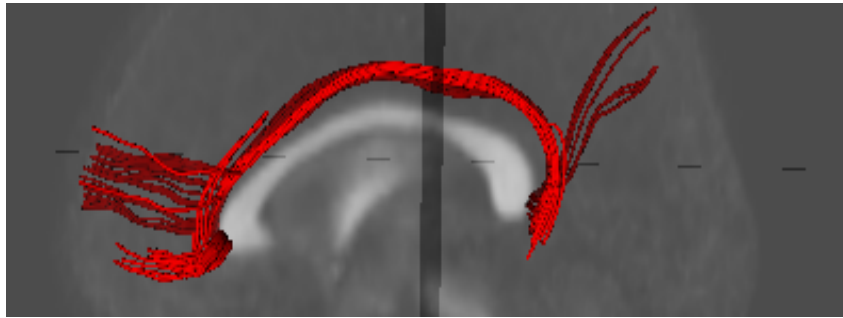
left



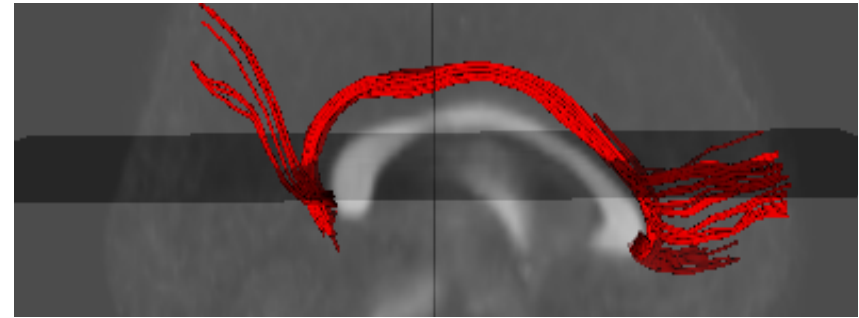
right



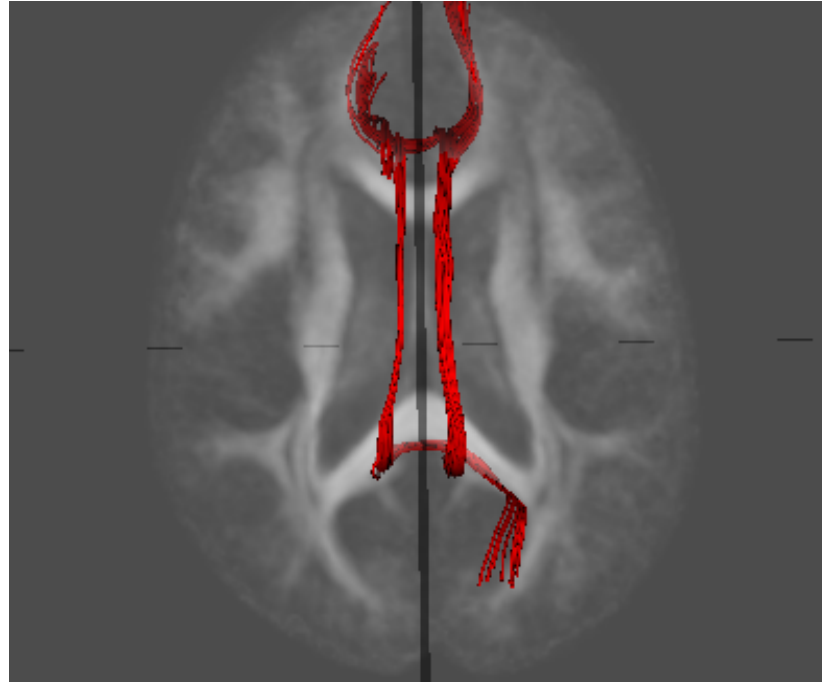
Cingulum



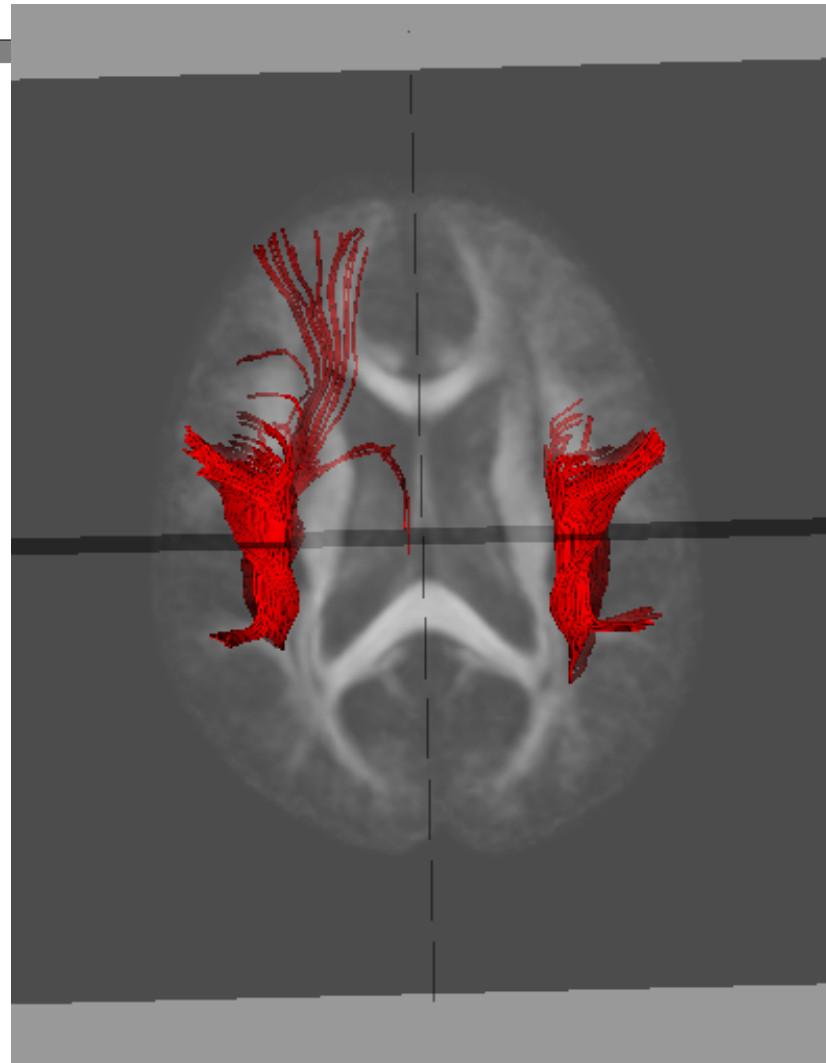
left



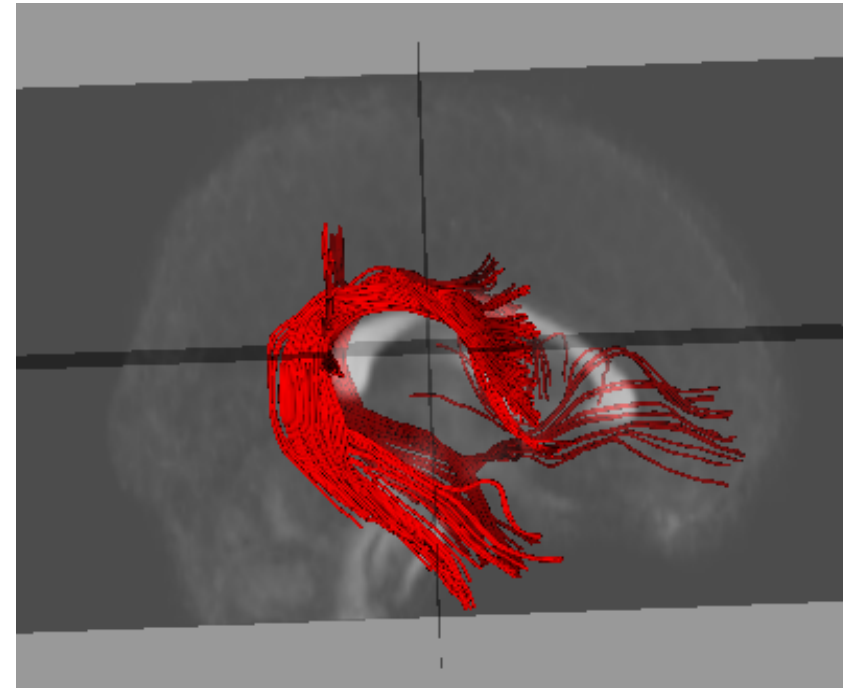
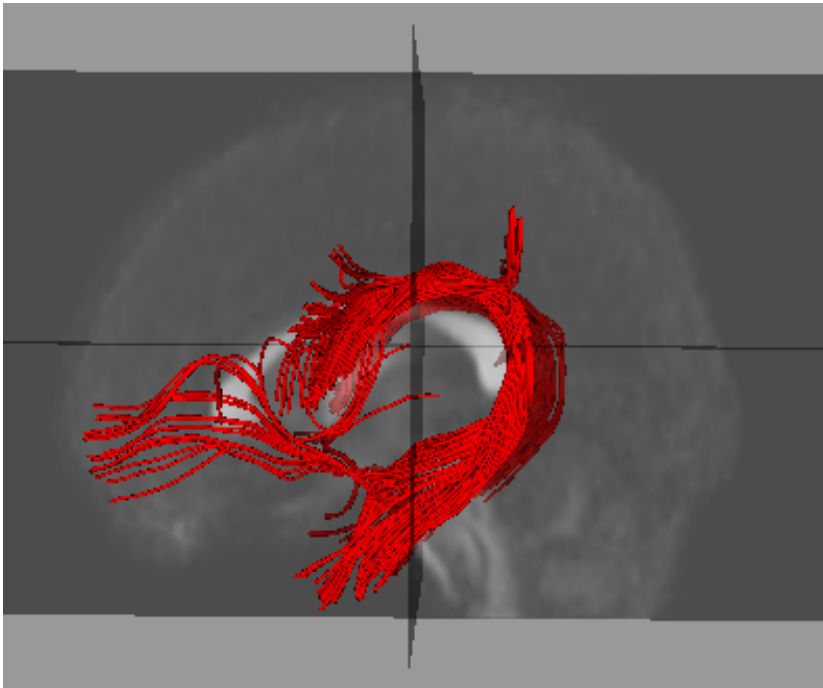
right



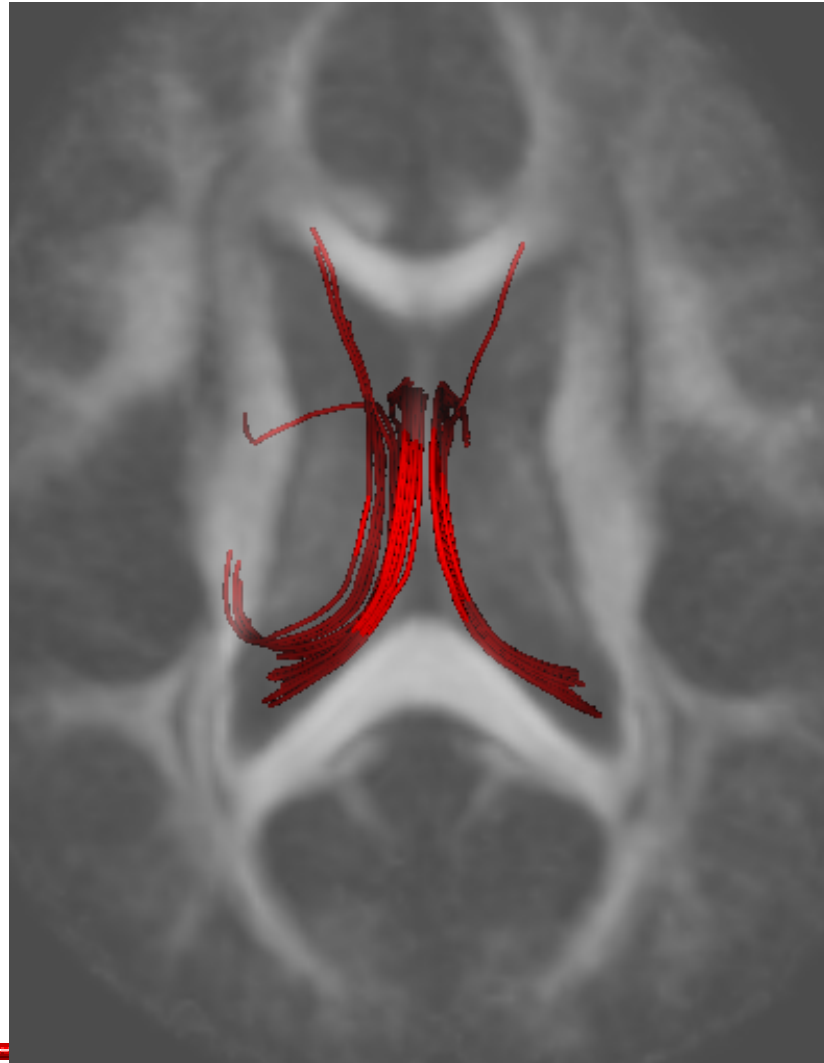
Arcuate



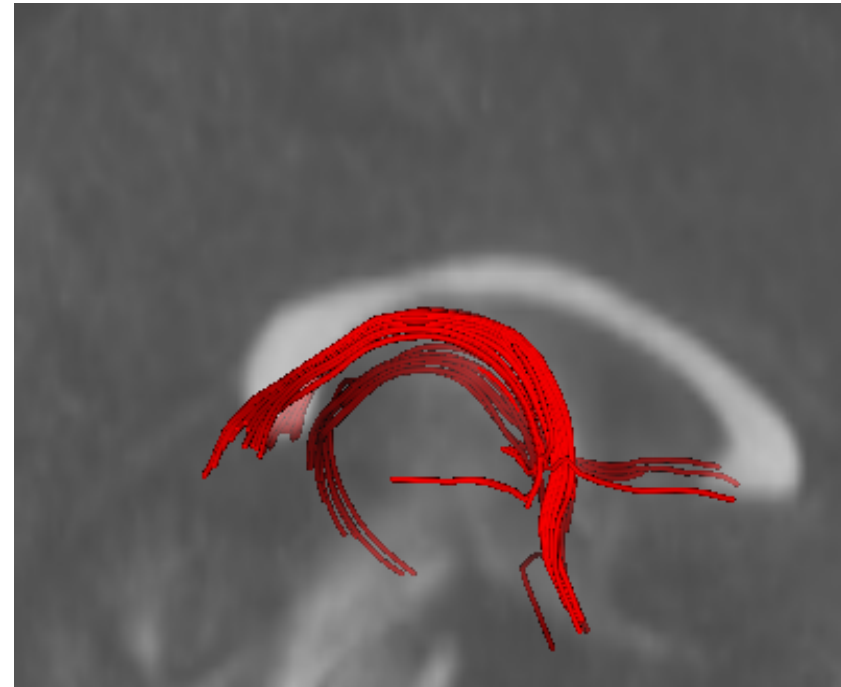
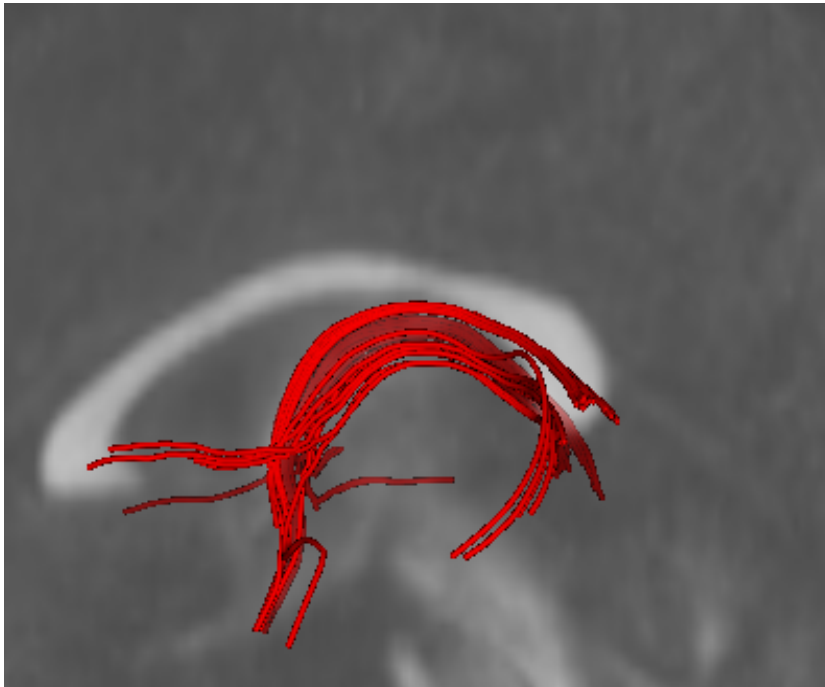
Arcuate



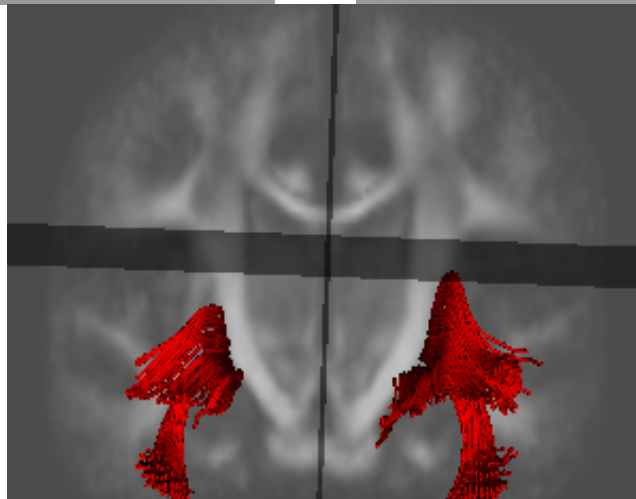
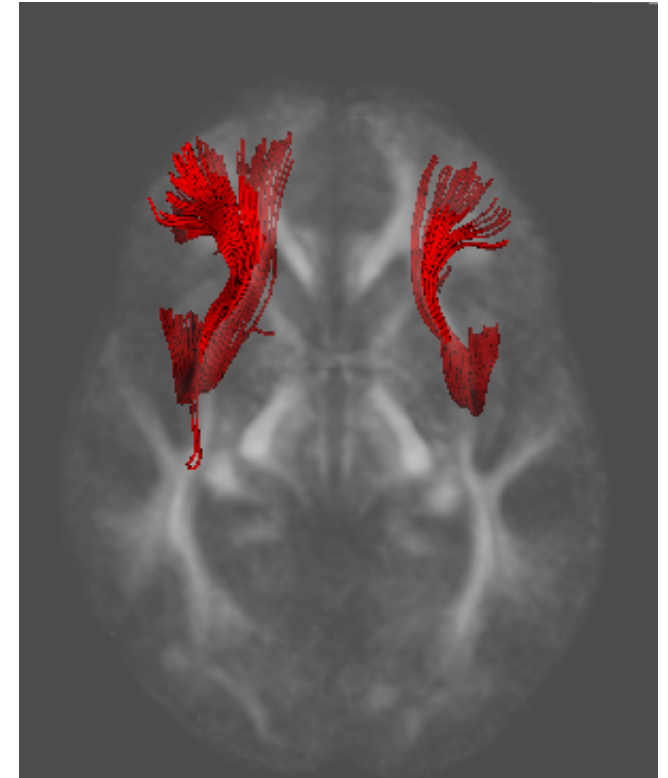
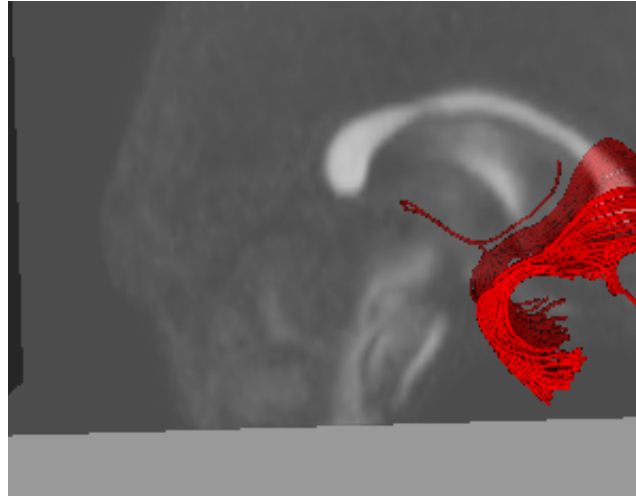
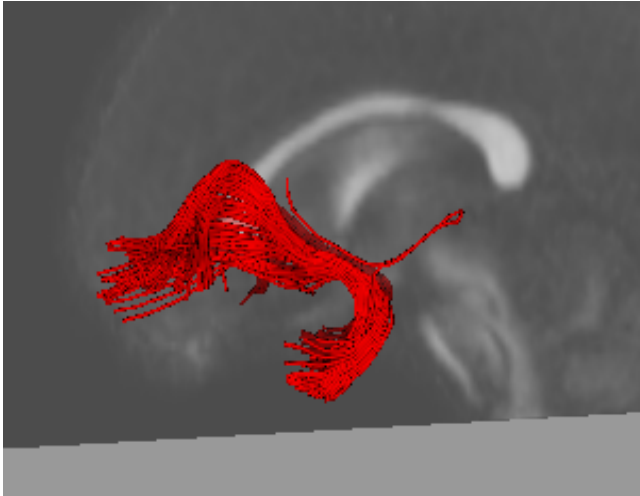
Fornix



Fornix

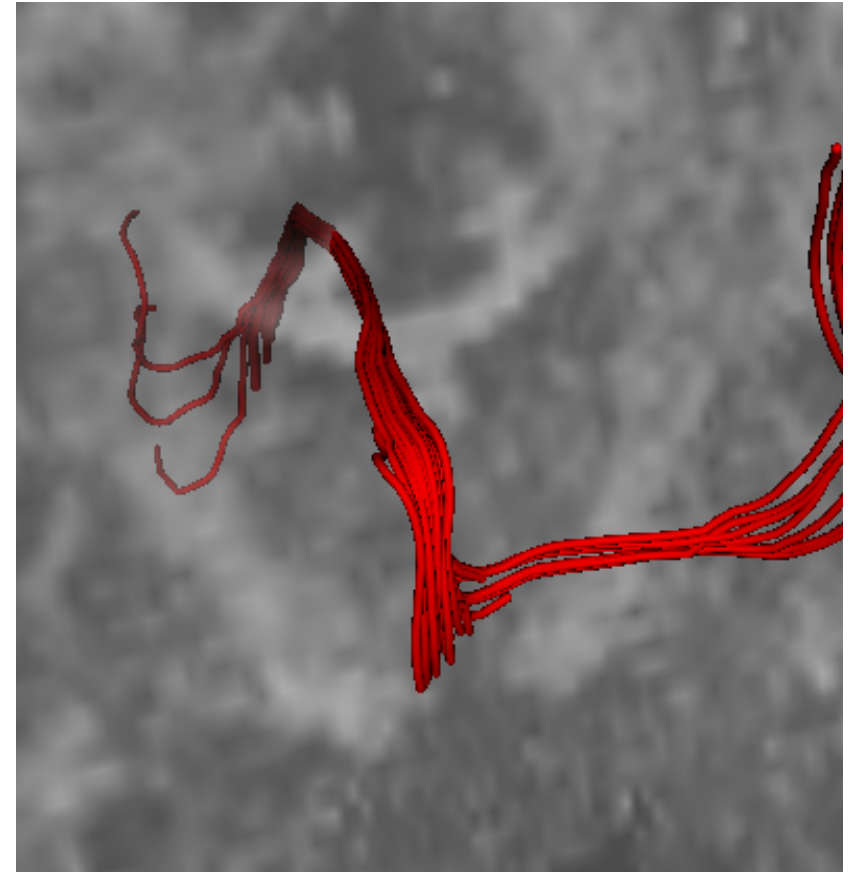
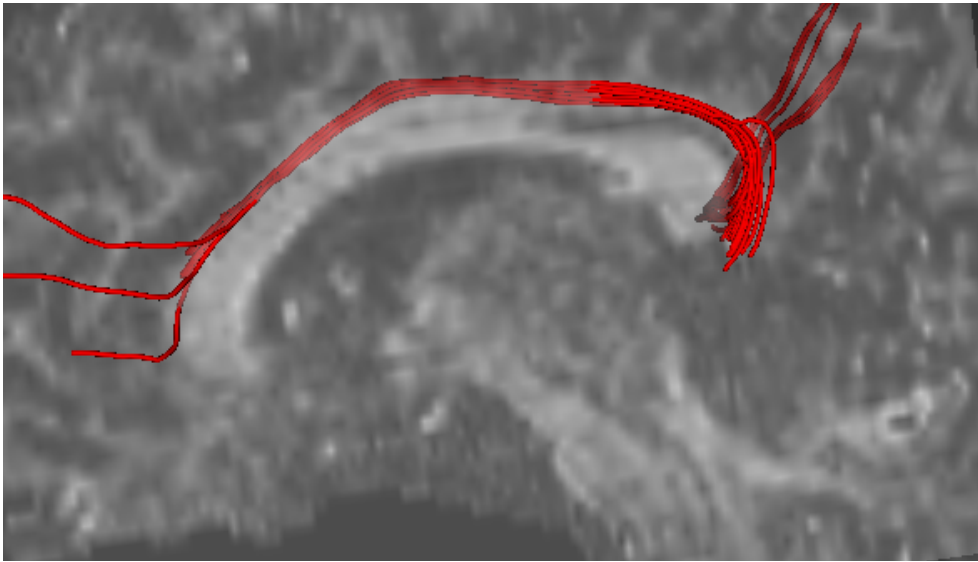


Uncinate



Quick Quality Check of Atlas

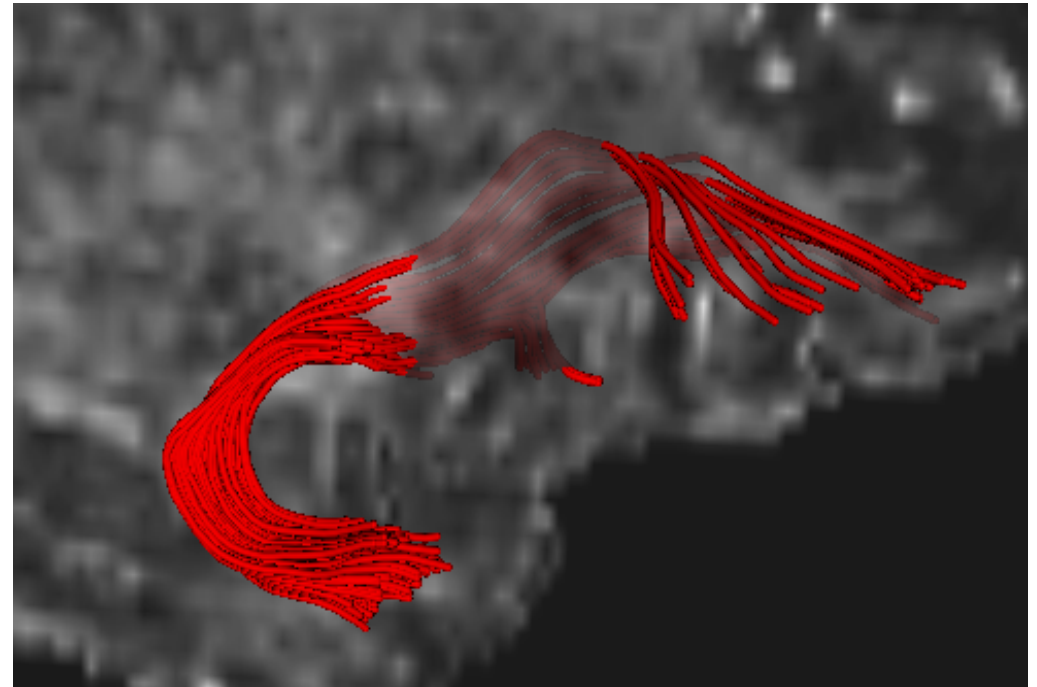

caseD00922



Top: Left cingulum bundle (Sagittal View)
Right: Left cingulum bundle (Coronal View)

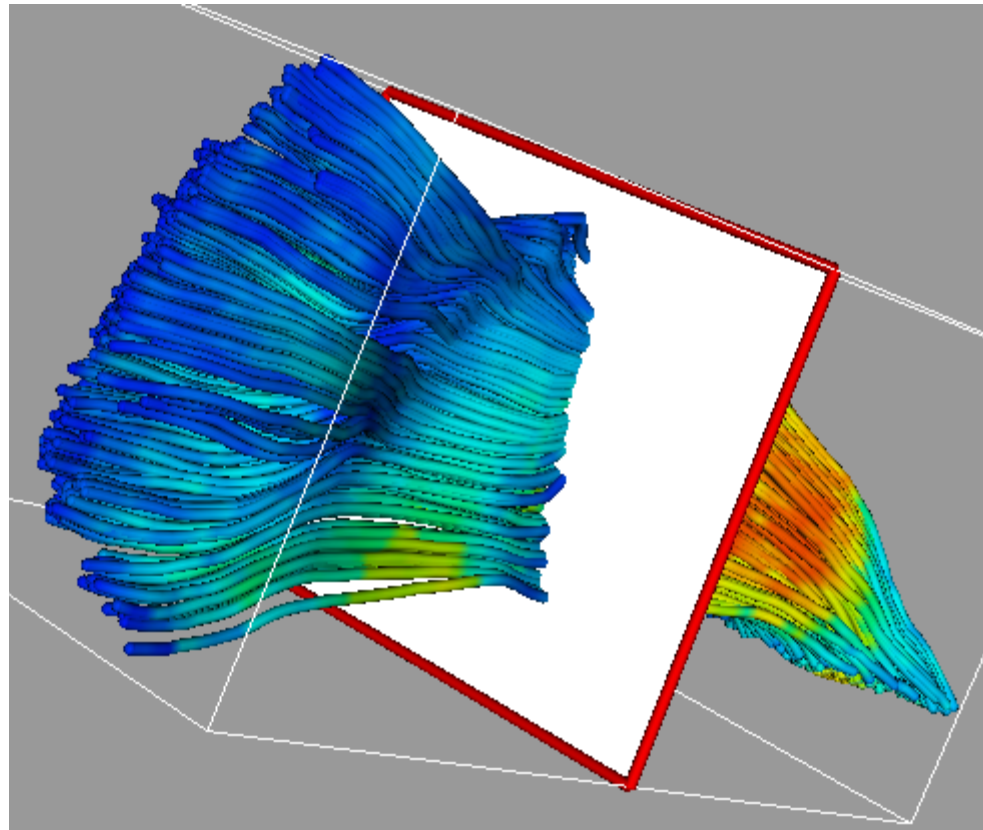
Quick Quality Check of Atlas

caseD00939

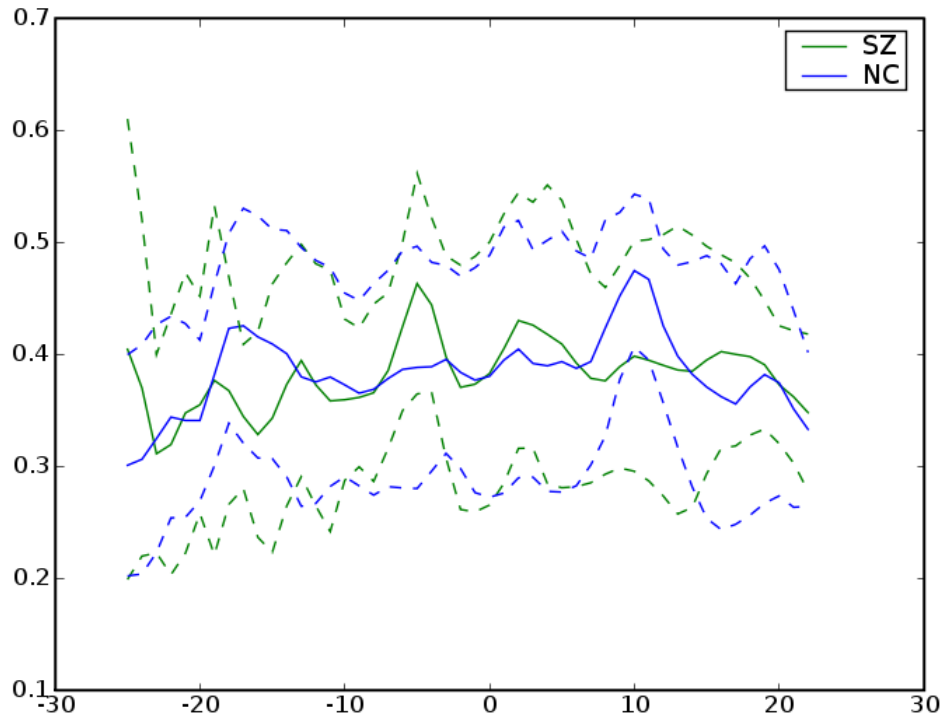


Left: Right Uncinate (from Anterior)
Top: Right Uncinate (from Right)

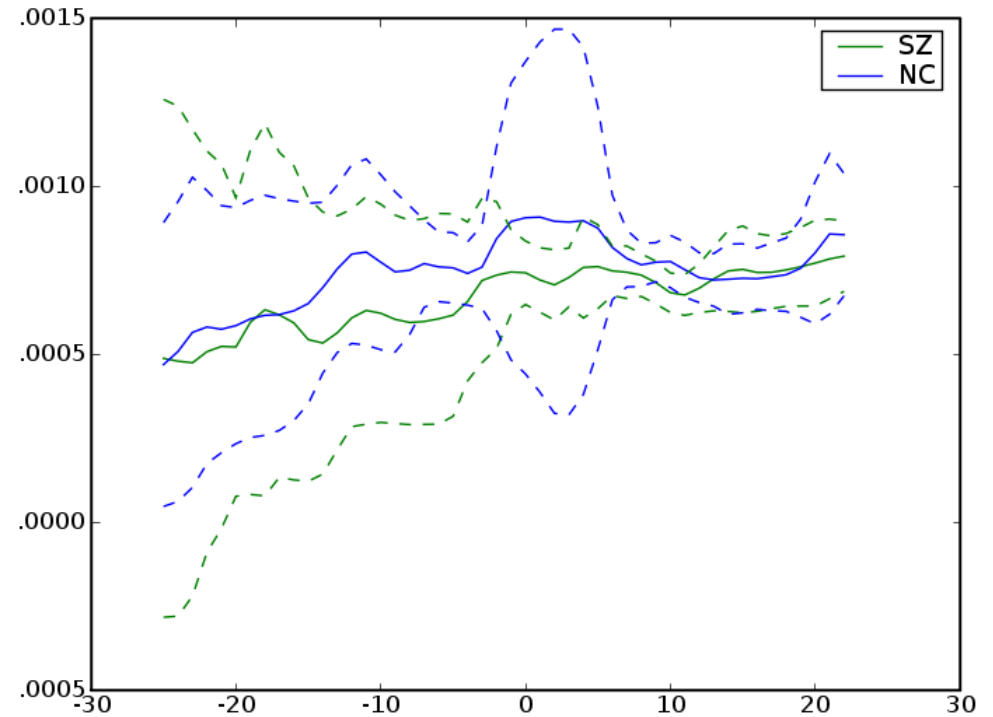
Left Internal Capsule



Left Internal Capsule

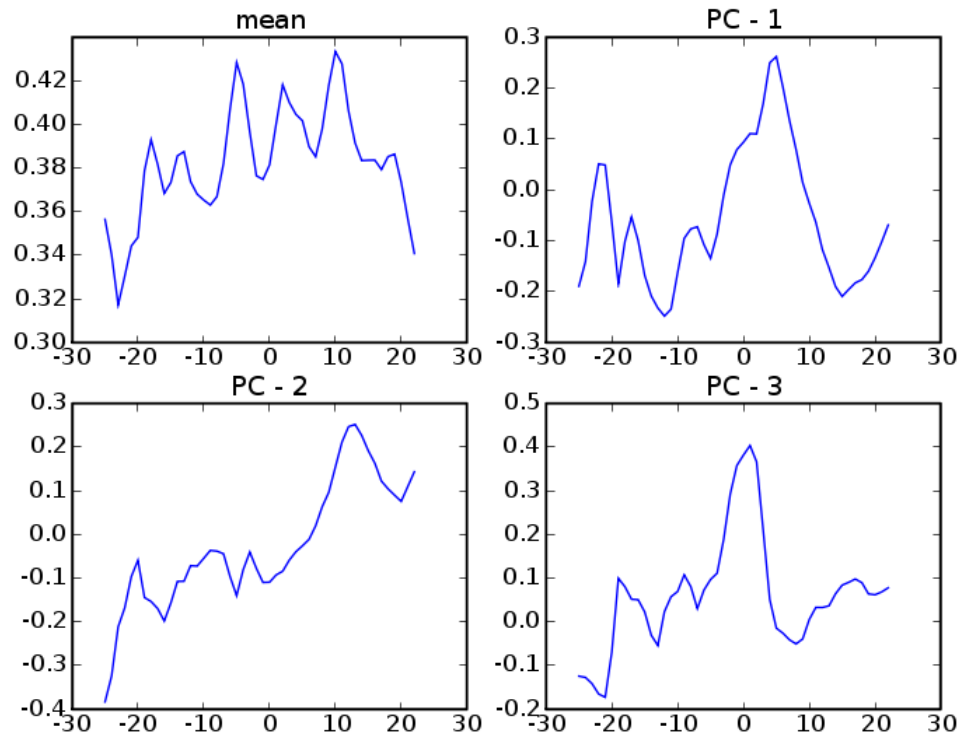


FA

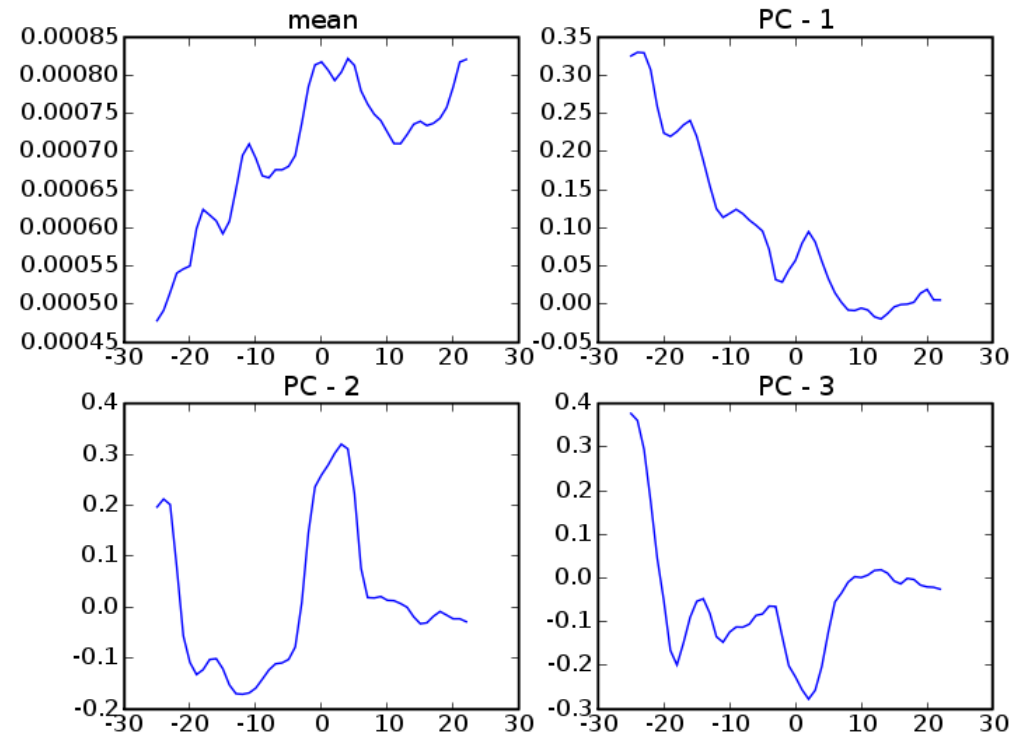


MD

Left Internal Capsule

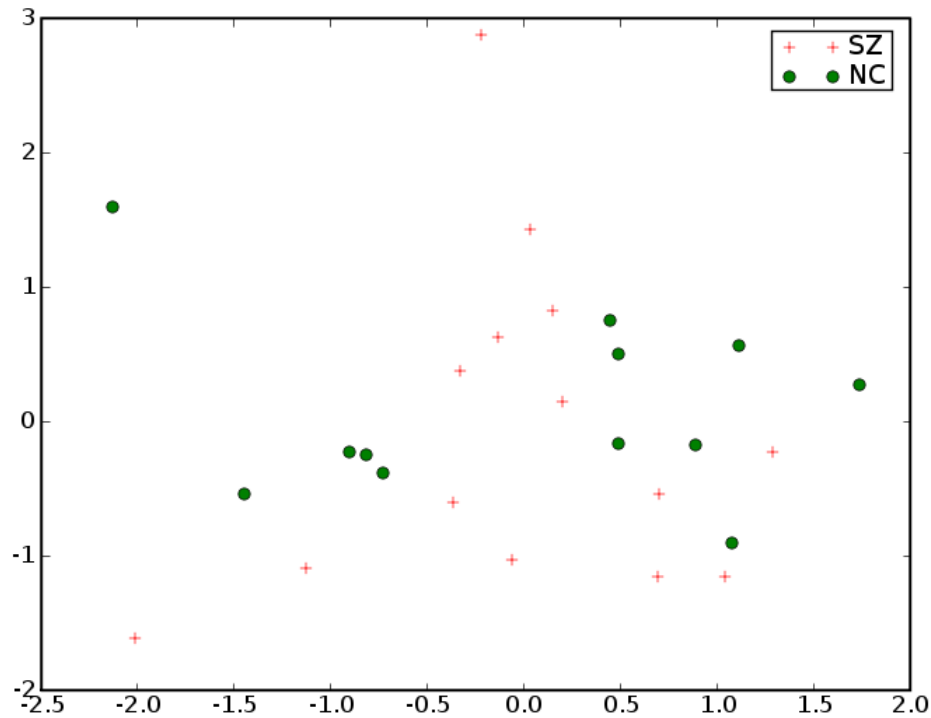


FA

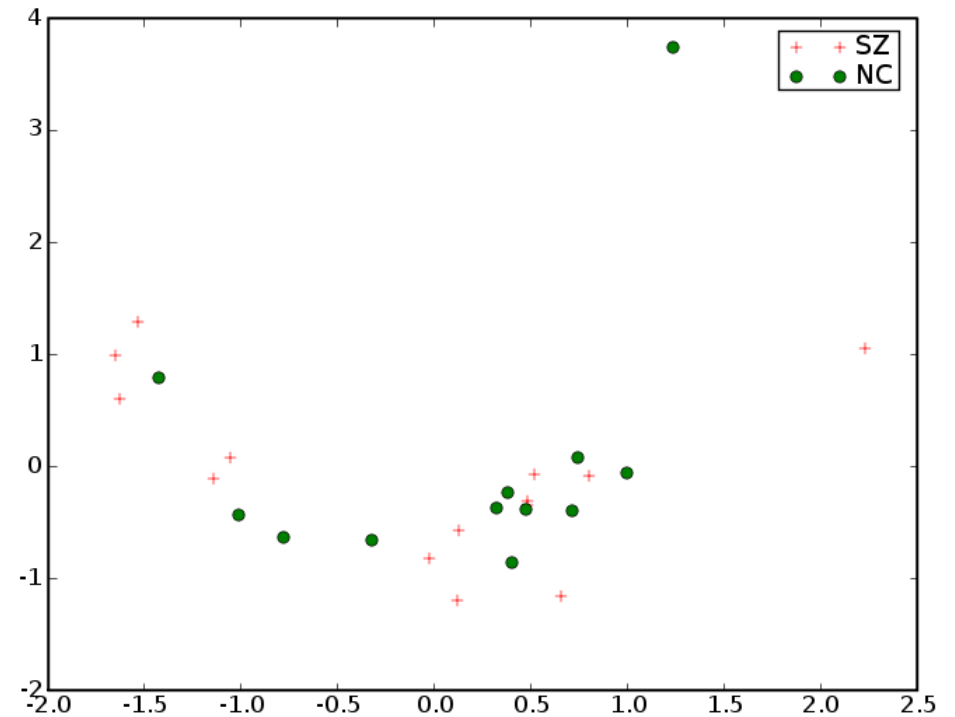


MD

Left Internal Capsule




FA

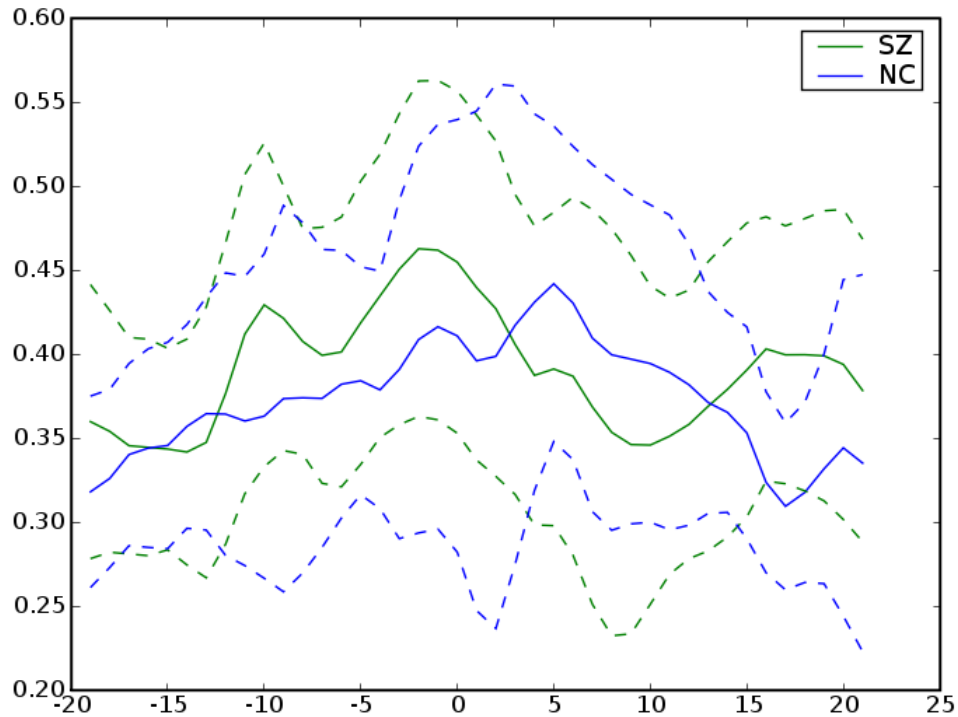


MD

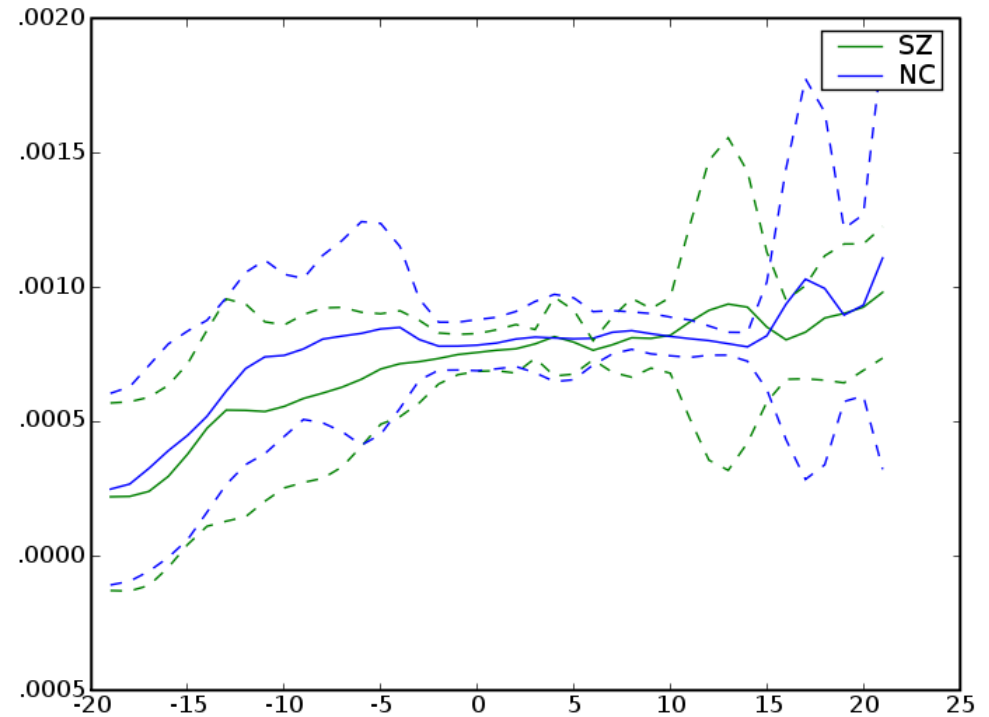
Right Internal Capsule



Right Internal Capsule

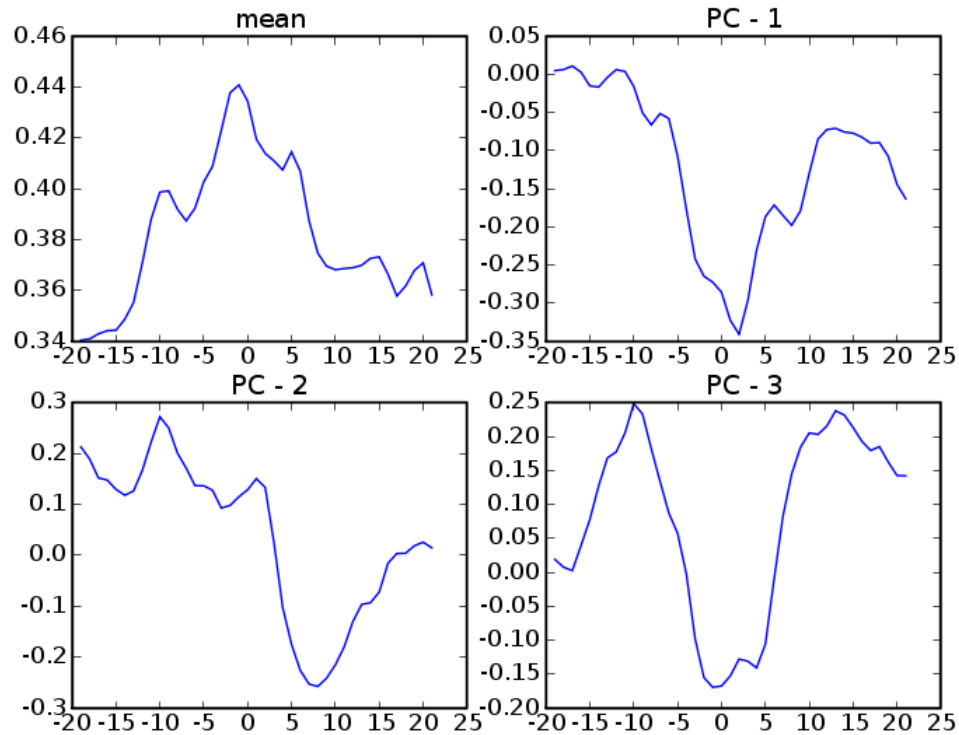


FA

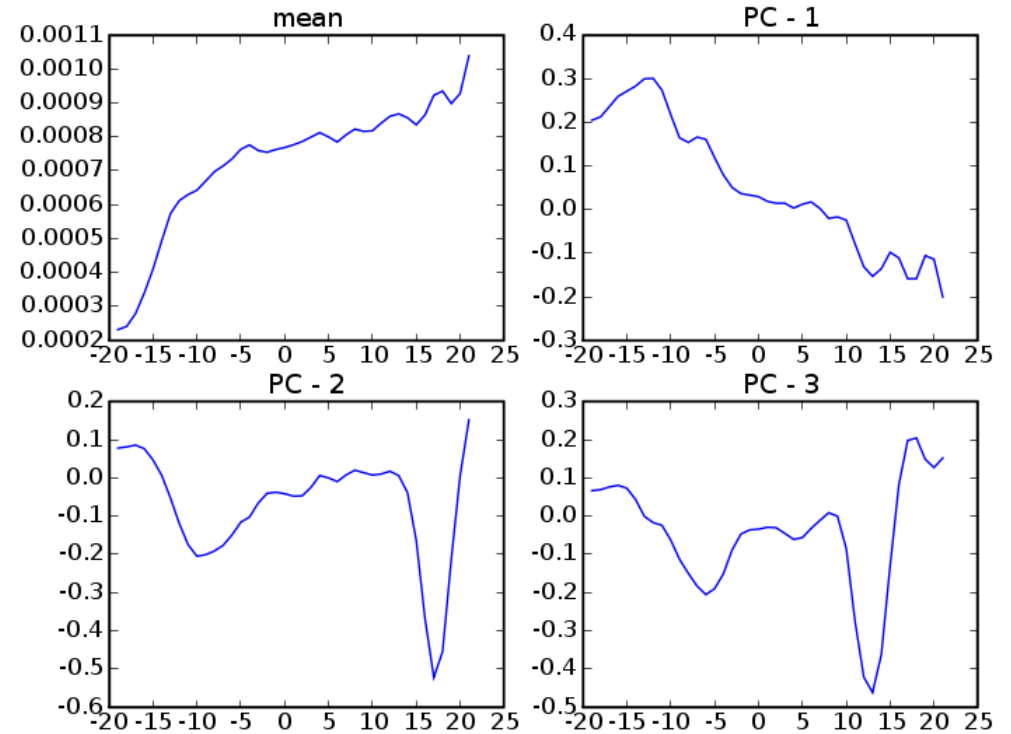


MD

Right Internal Capsule

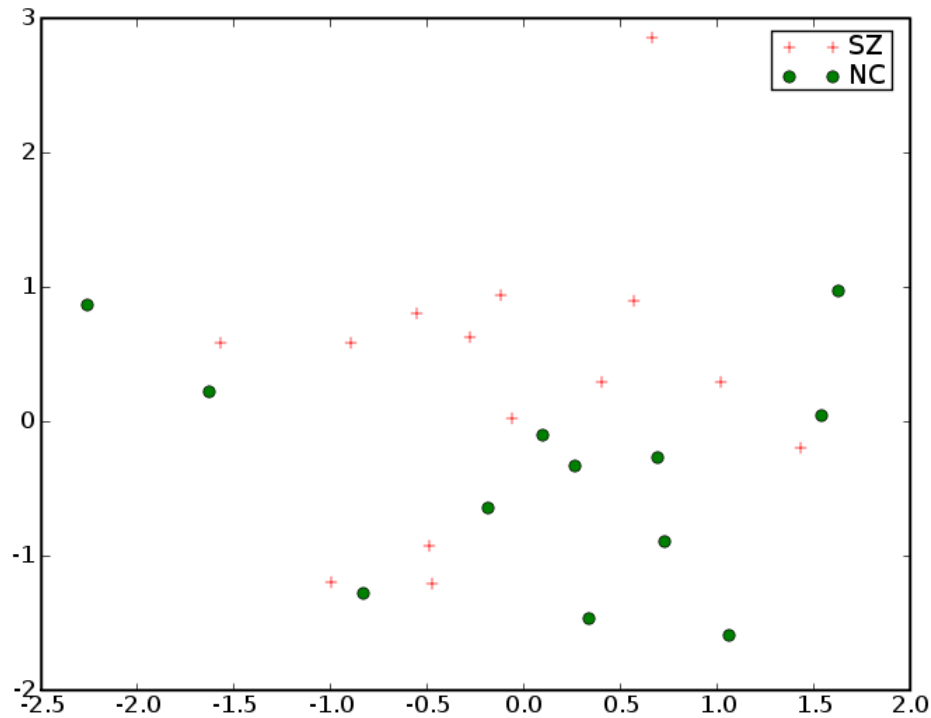


FA

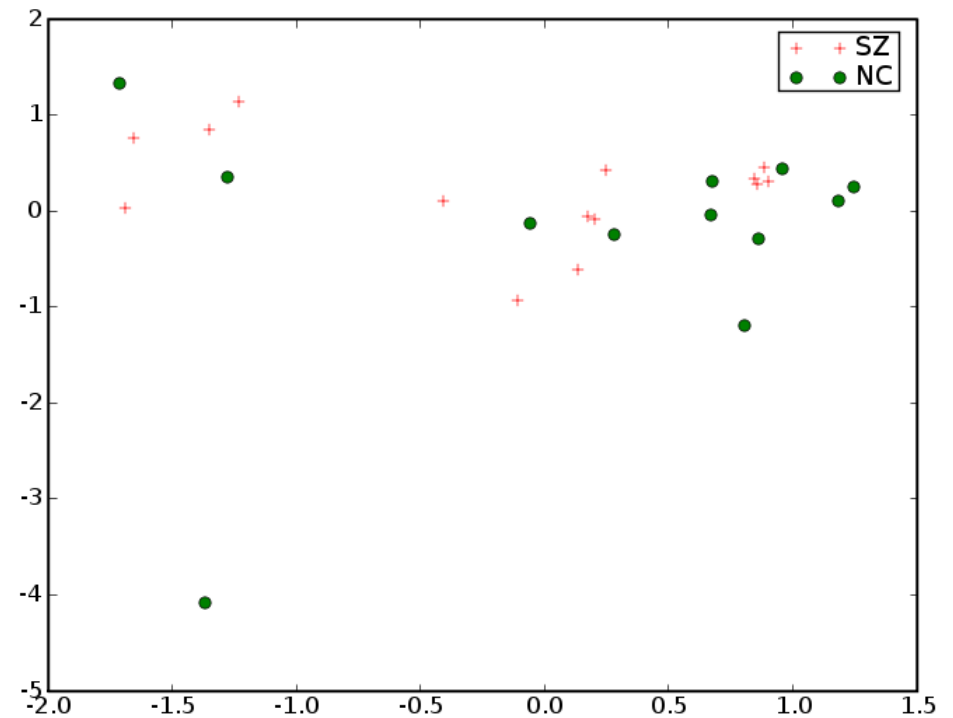


MD

Right Internal Capsule

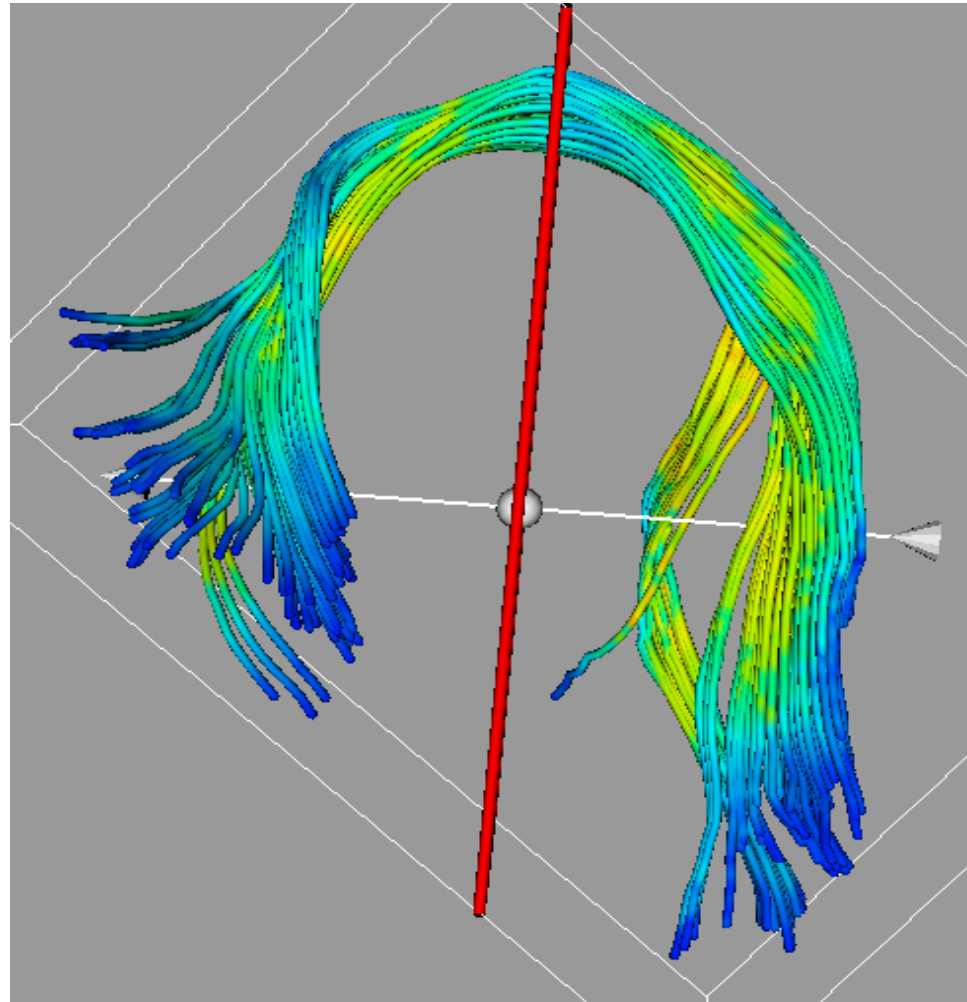


FA

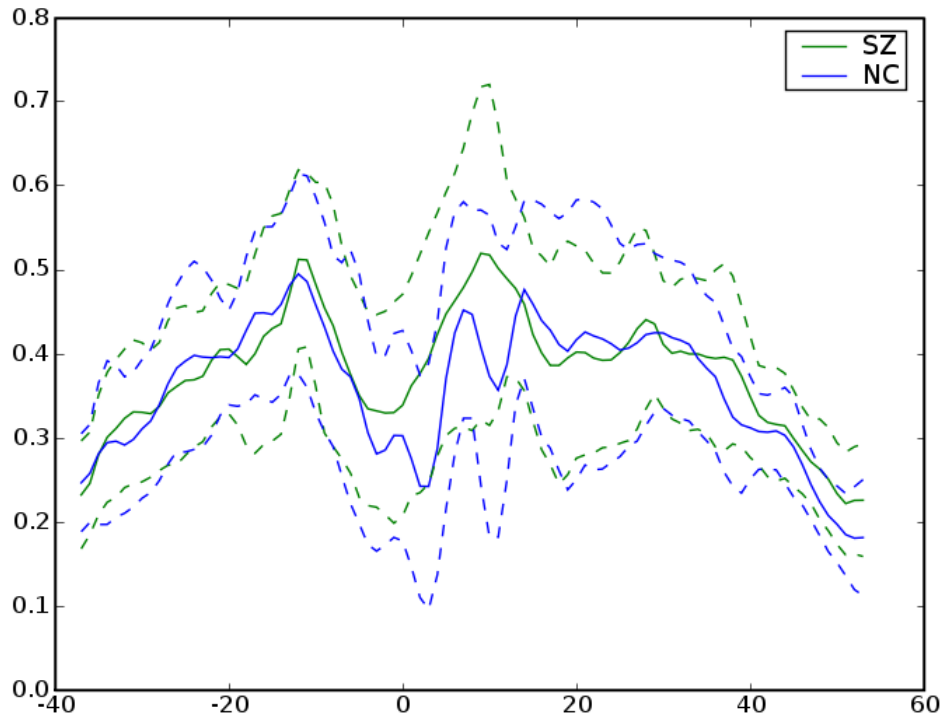


MD

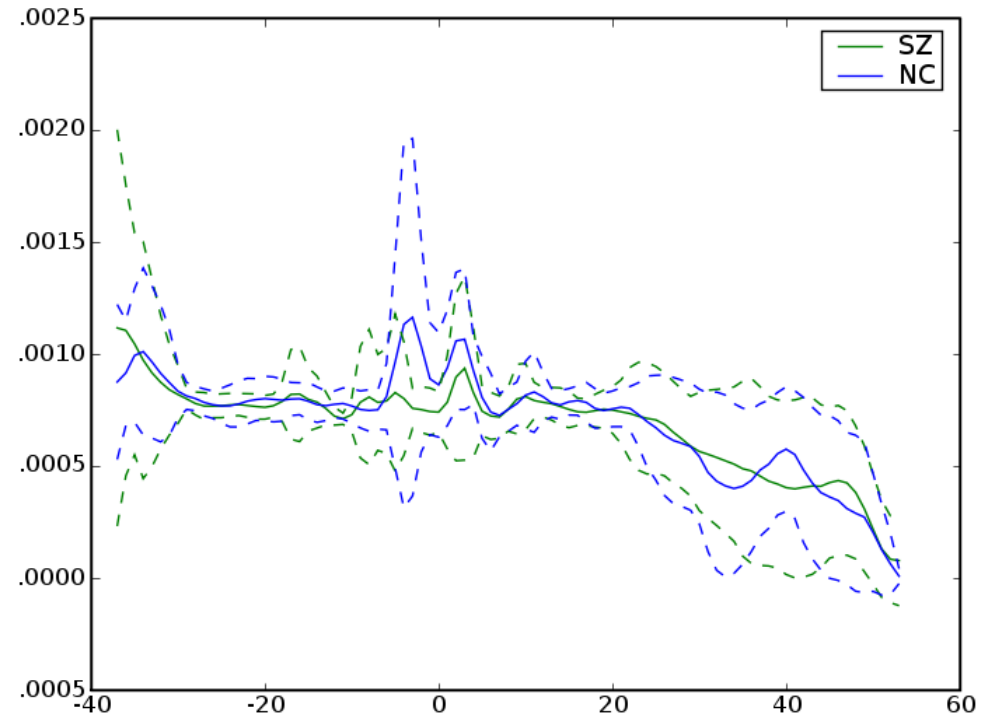
Left Arcuate



Left Arcuate

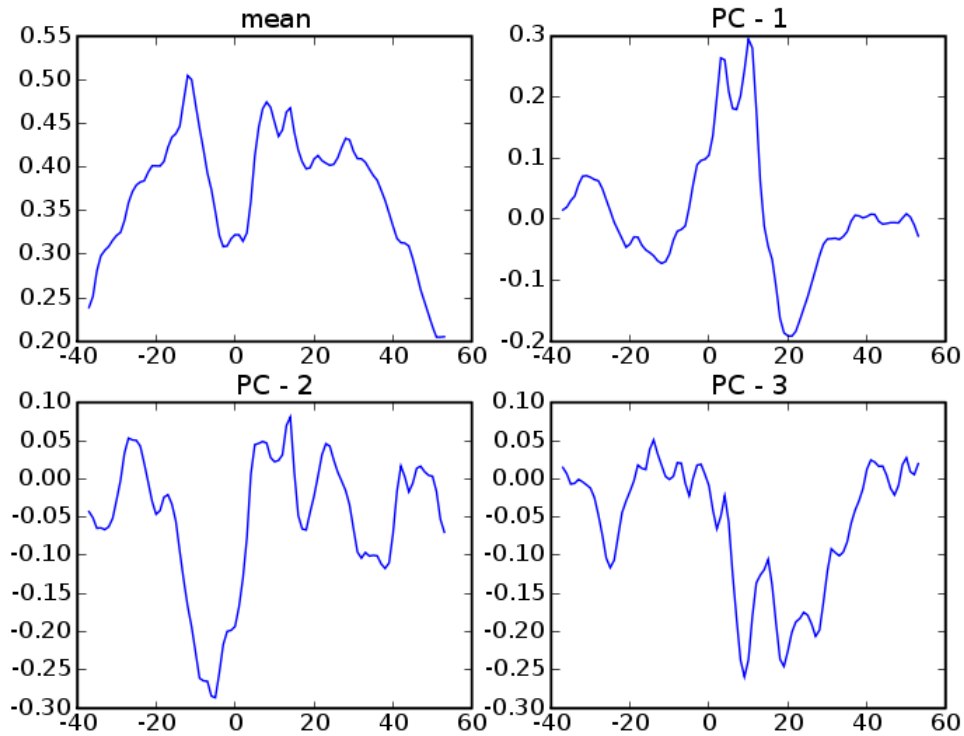


FA

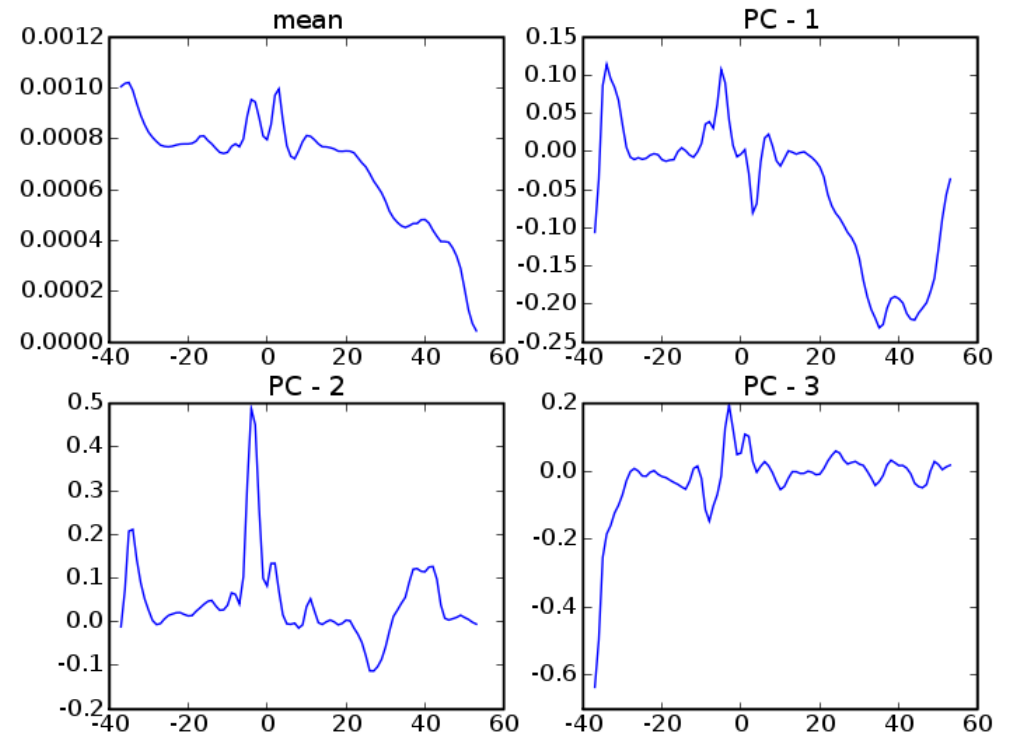


MD

Left Arcuate

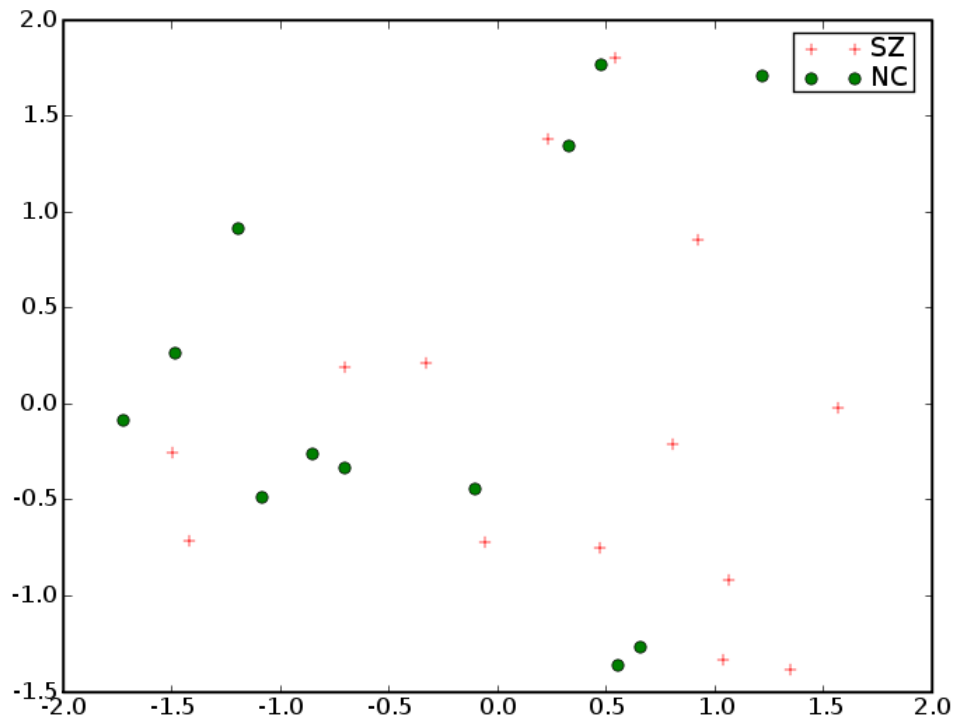


FA

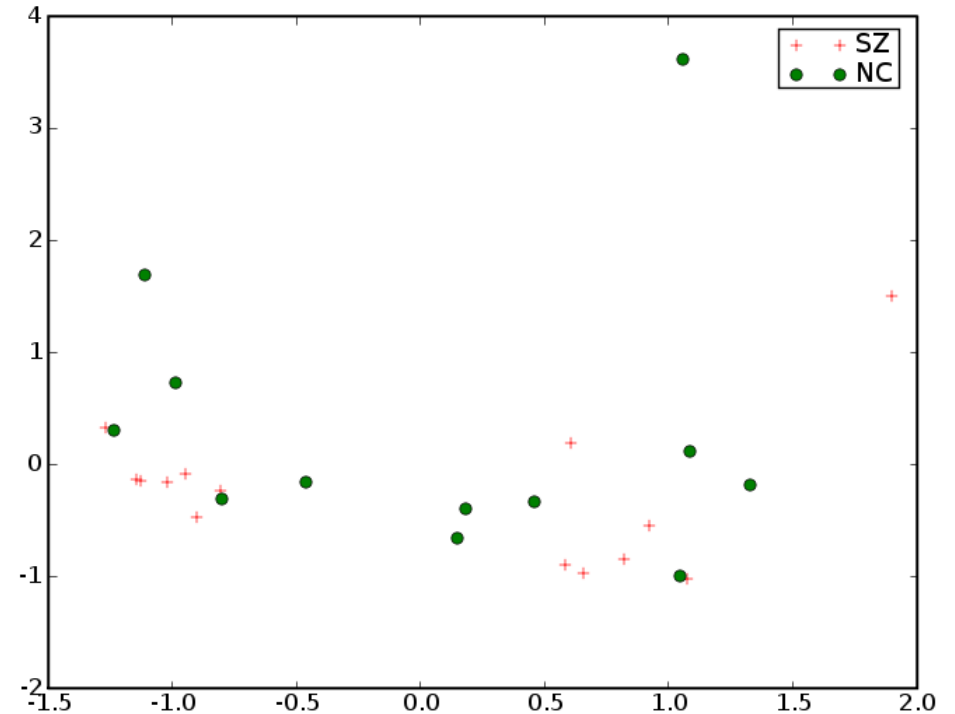


MD

Left Arcuate



FA

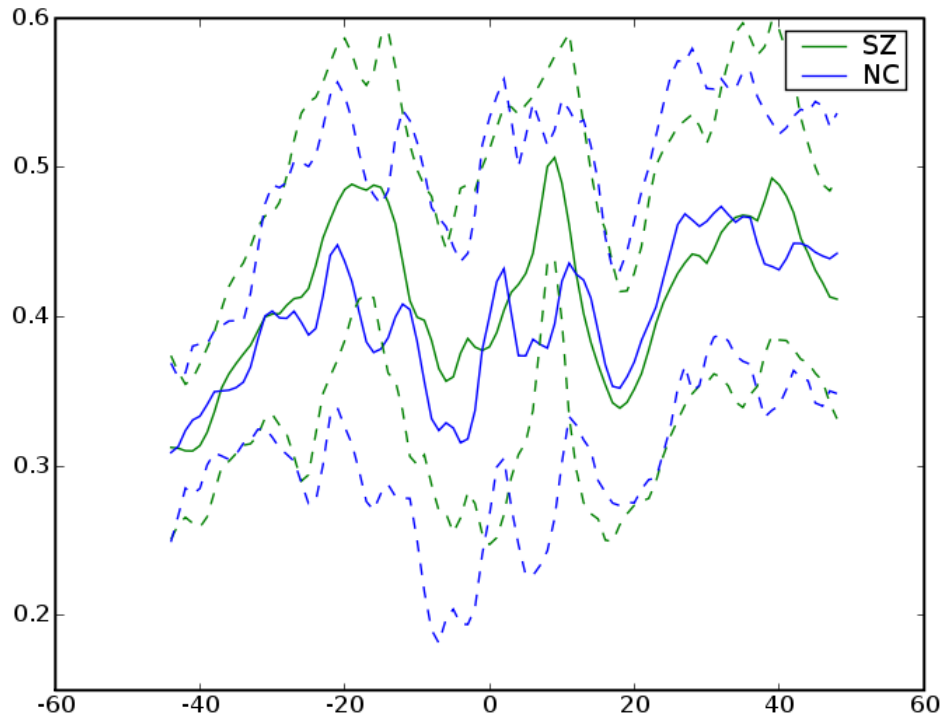


MD

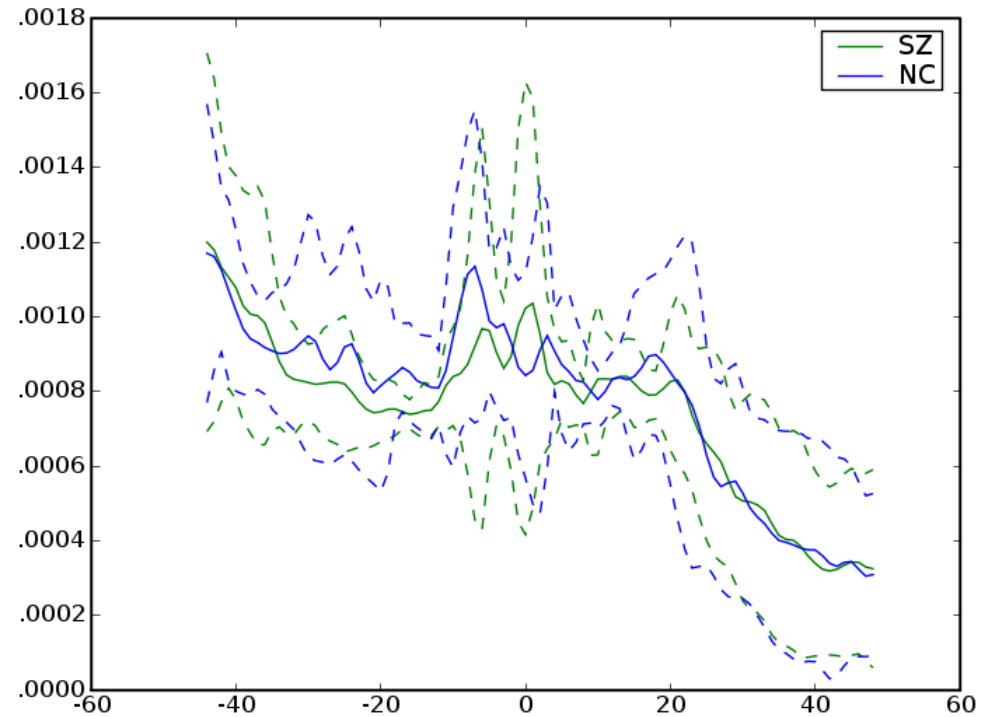
Right Arcuate



Right Arcuate

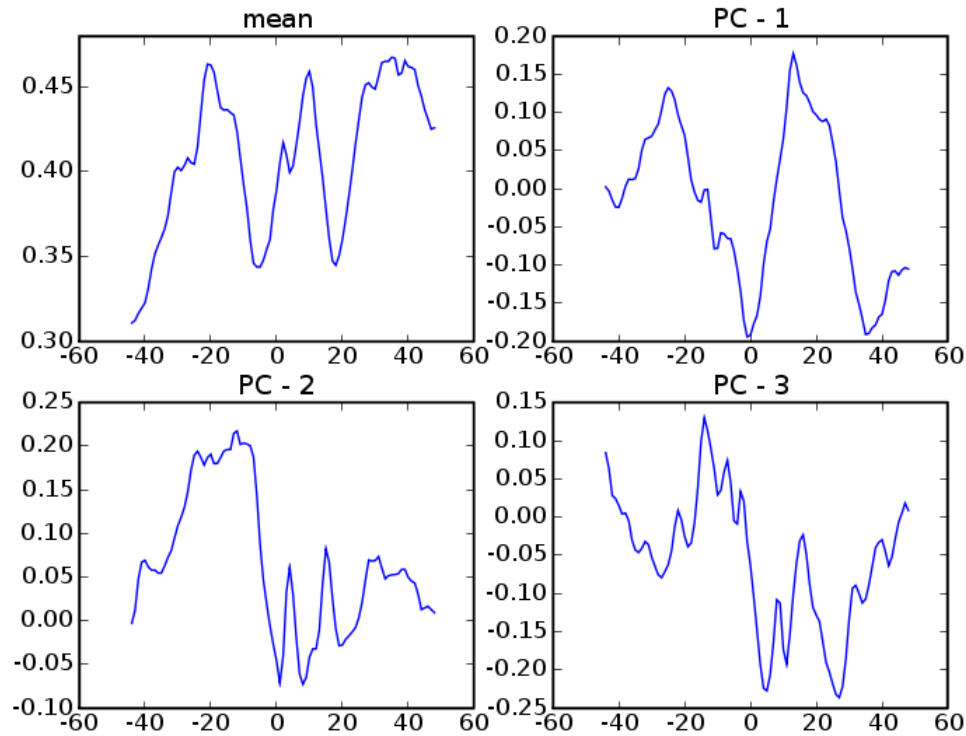


FA

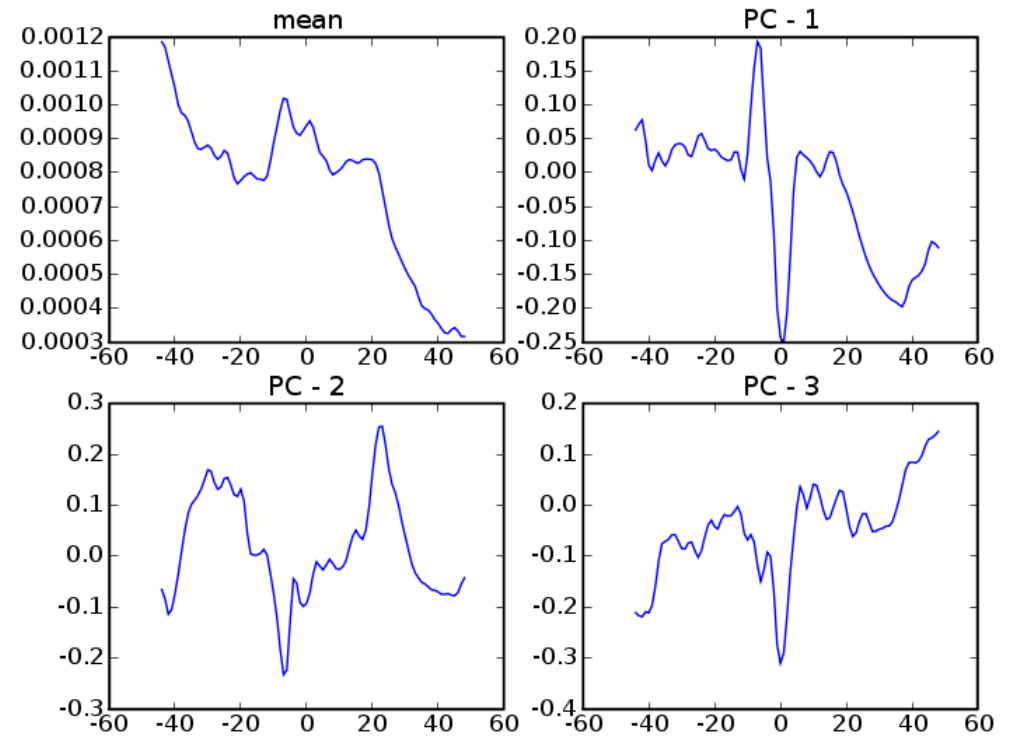


MD

Right Arcuate

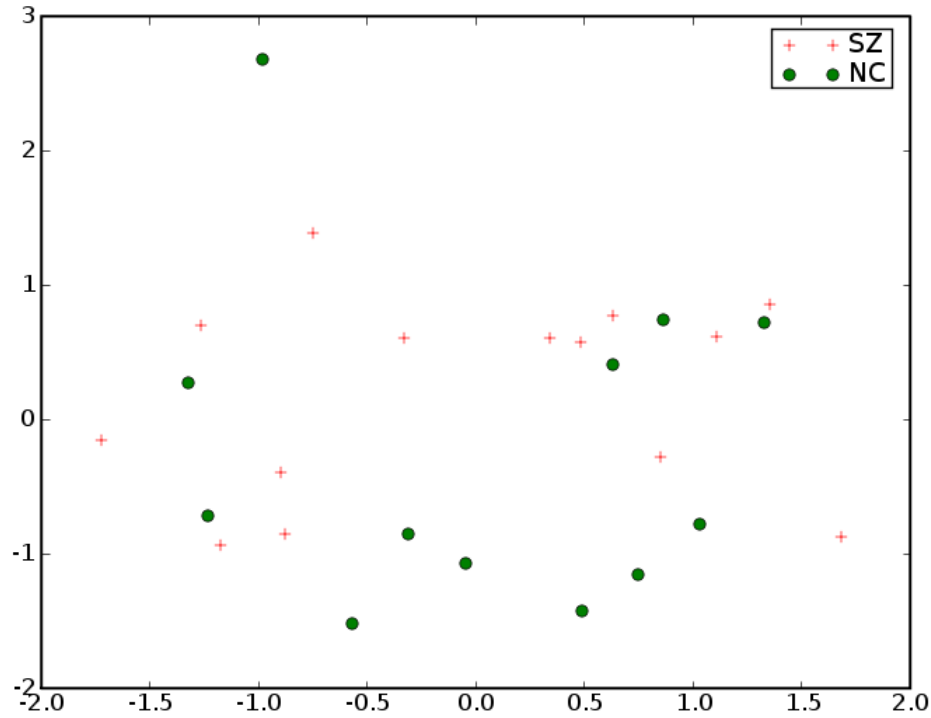


FA

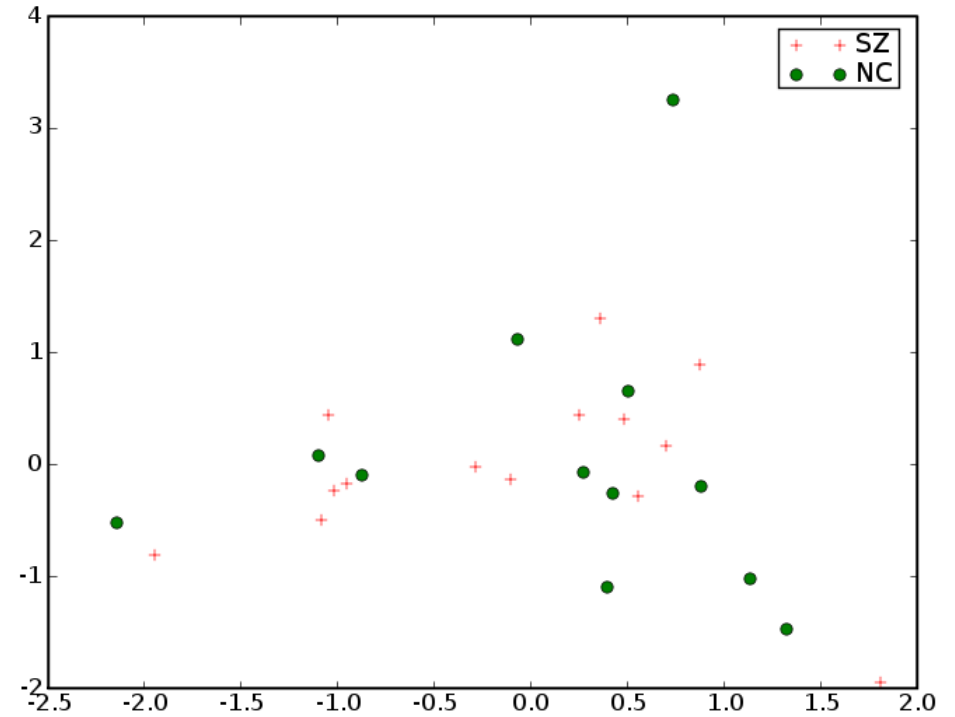


MD

Right Arcuate

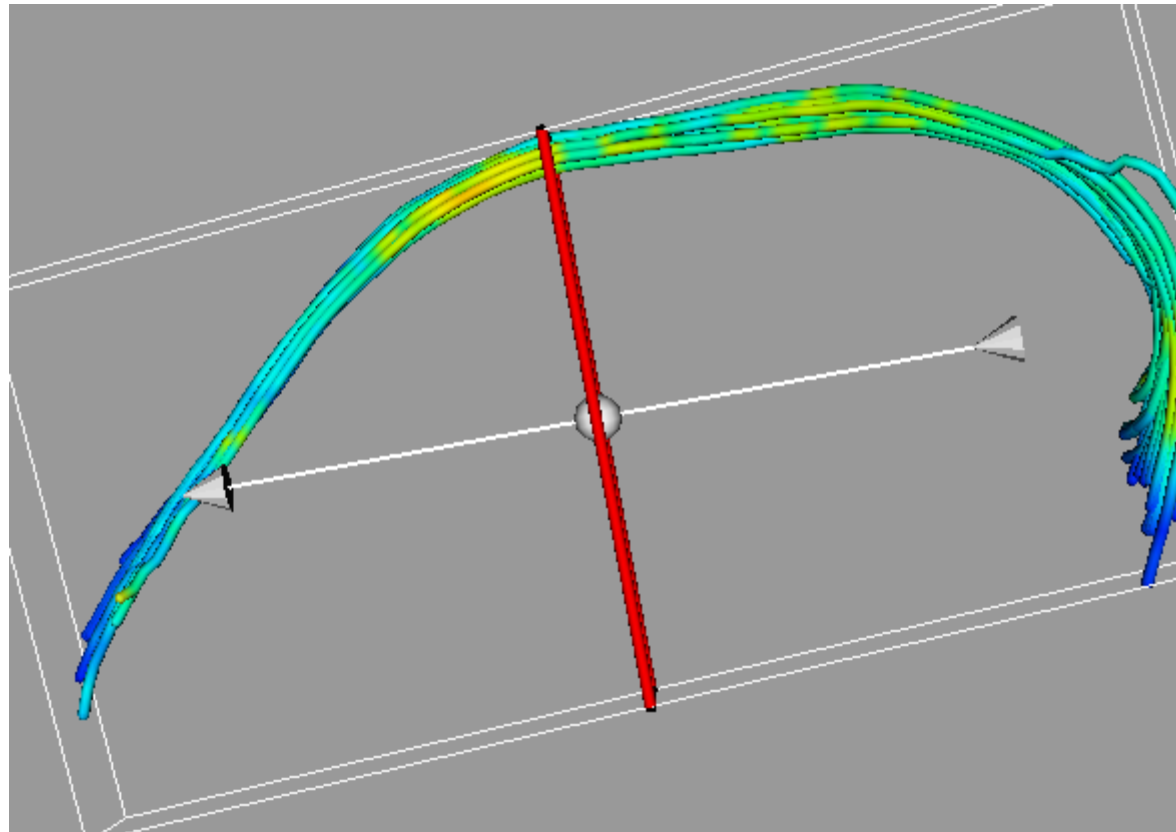


FA

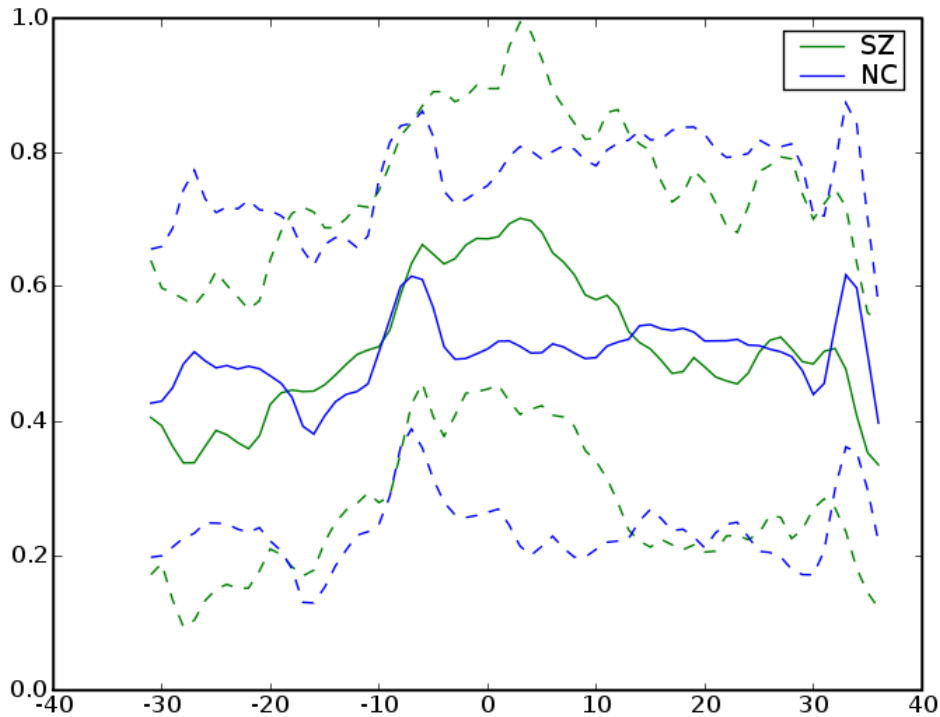


MD

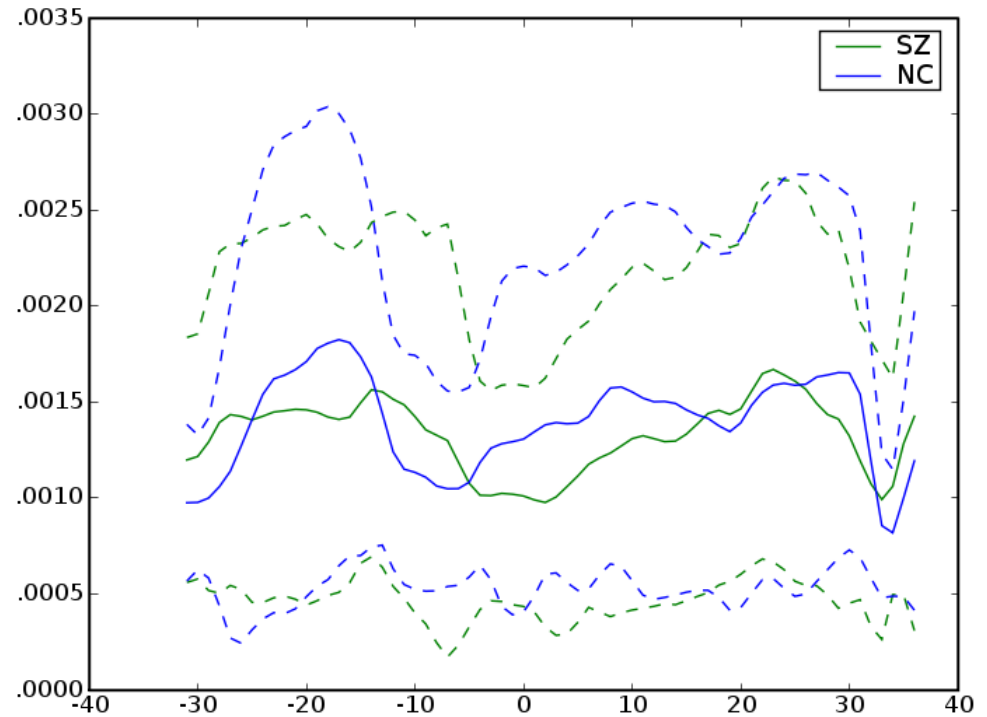
Left Cingulum



Left Cingulum

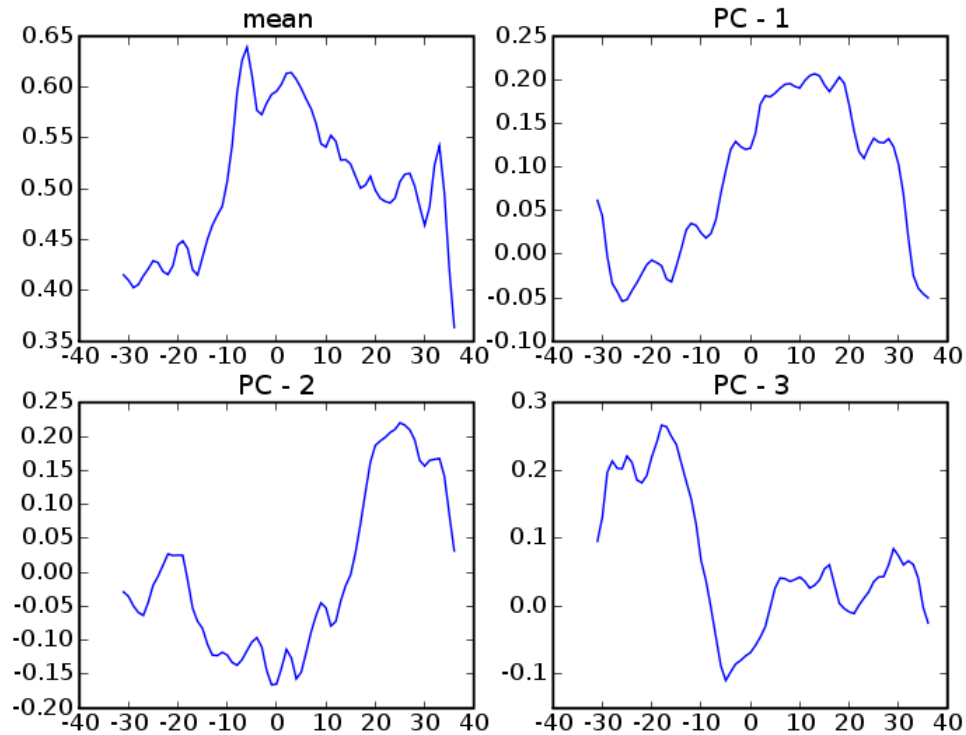


FA

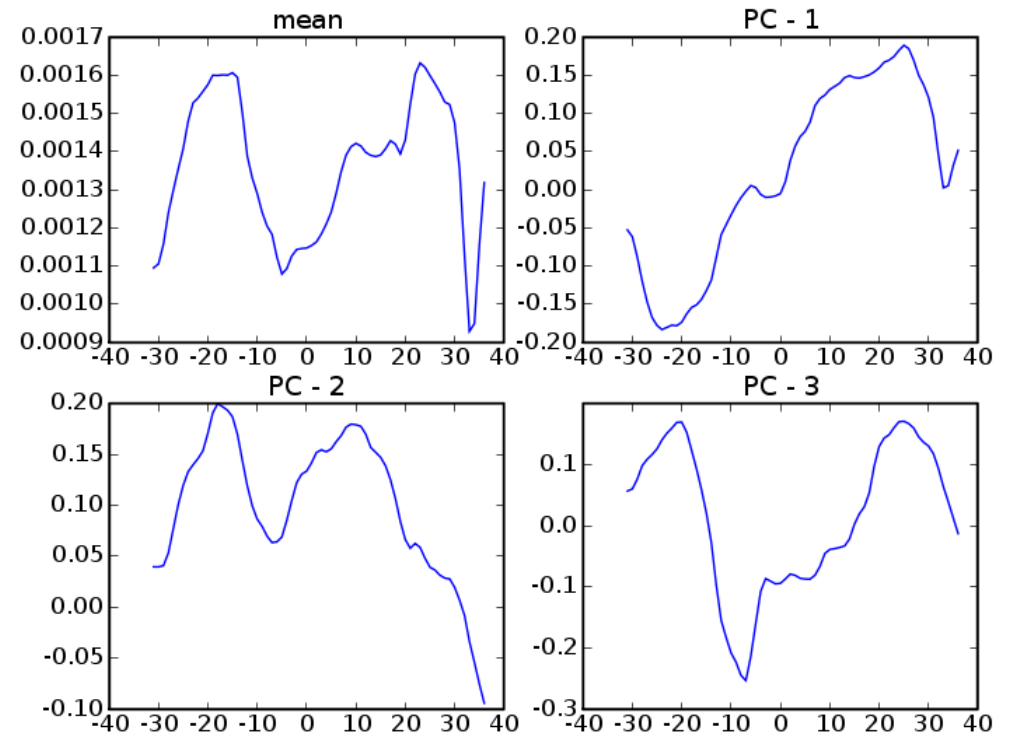


MD

Left Cingulum

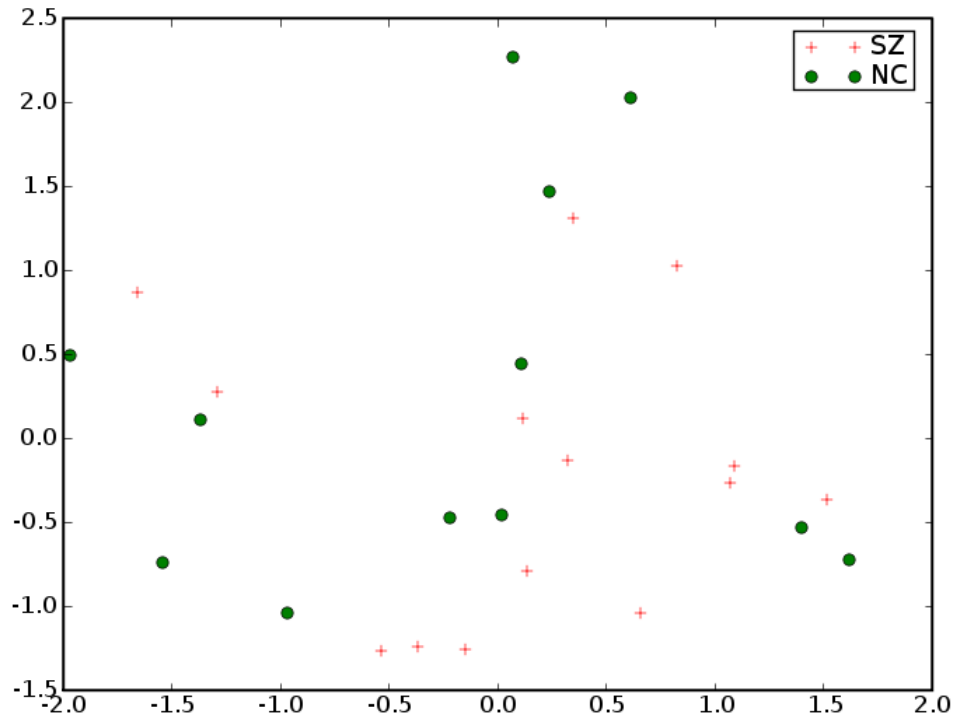


FA

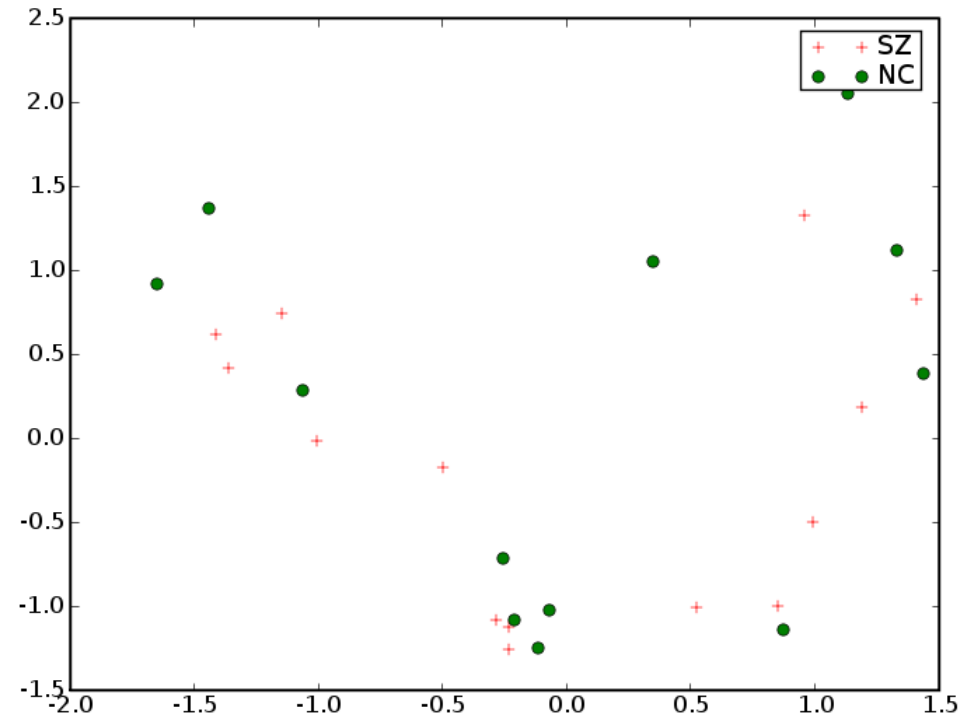


MD

Left Cingulum

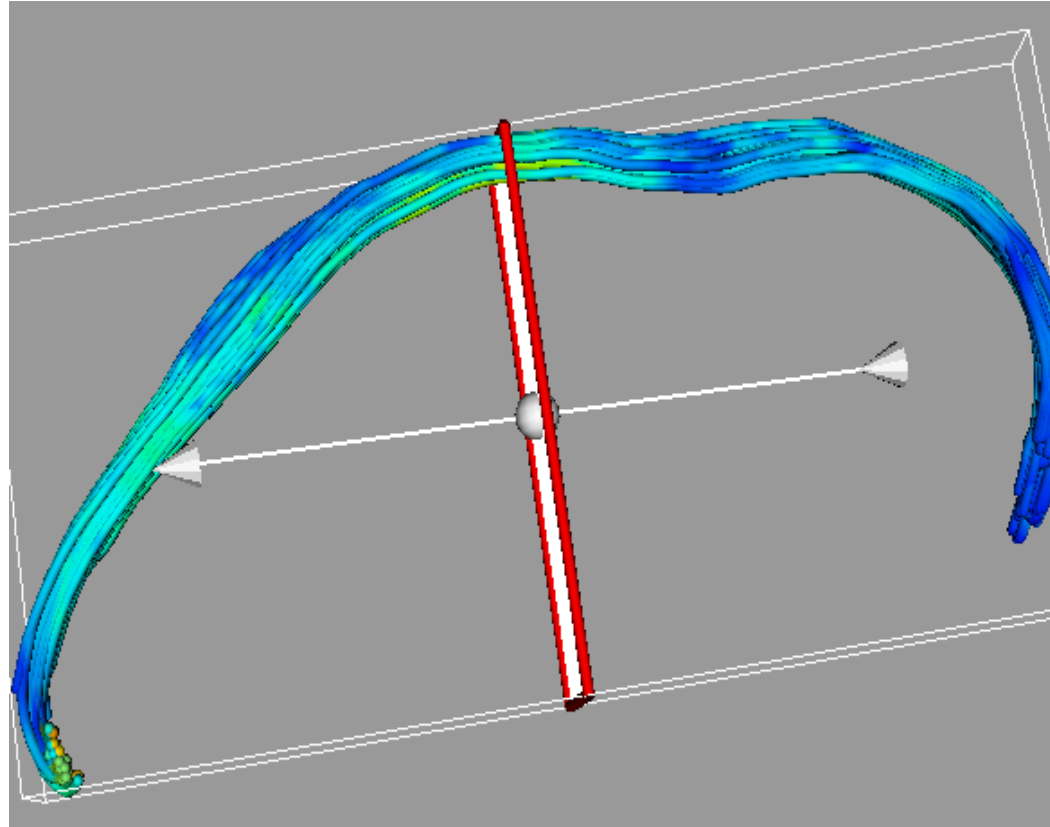


FA

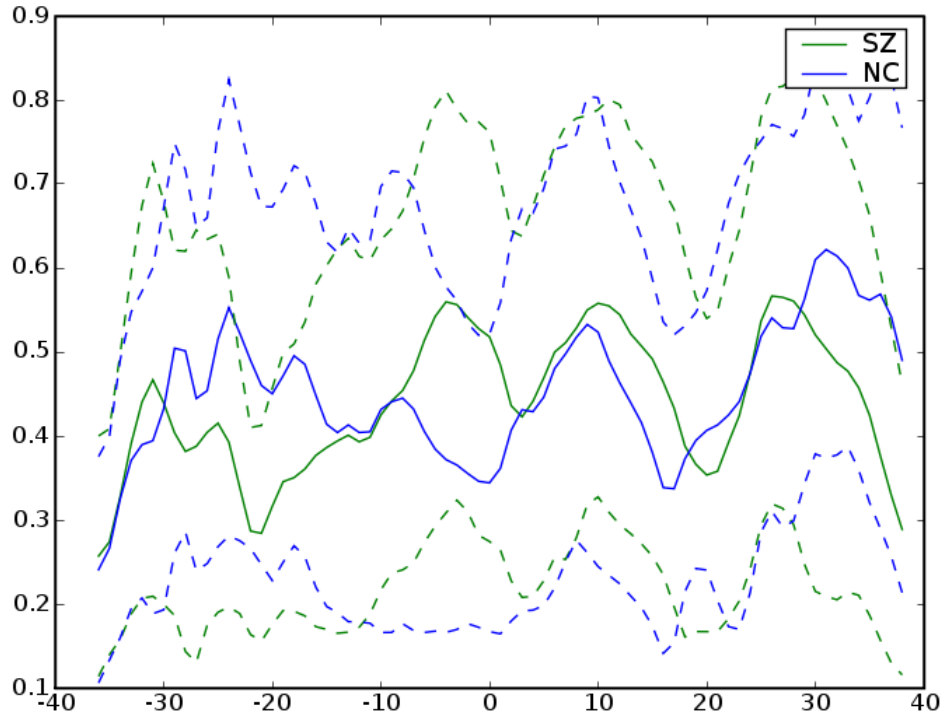


MD

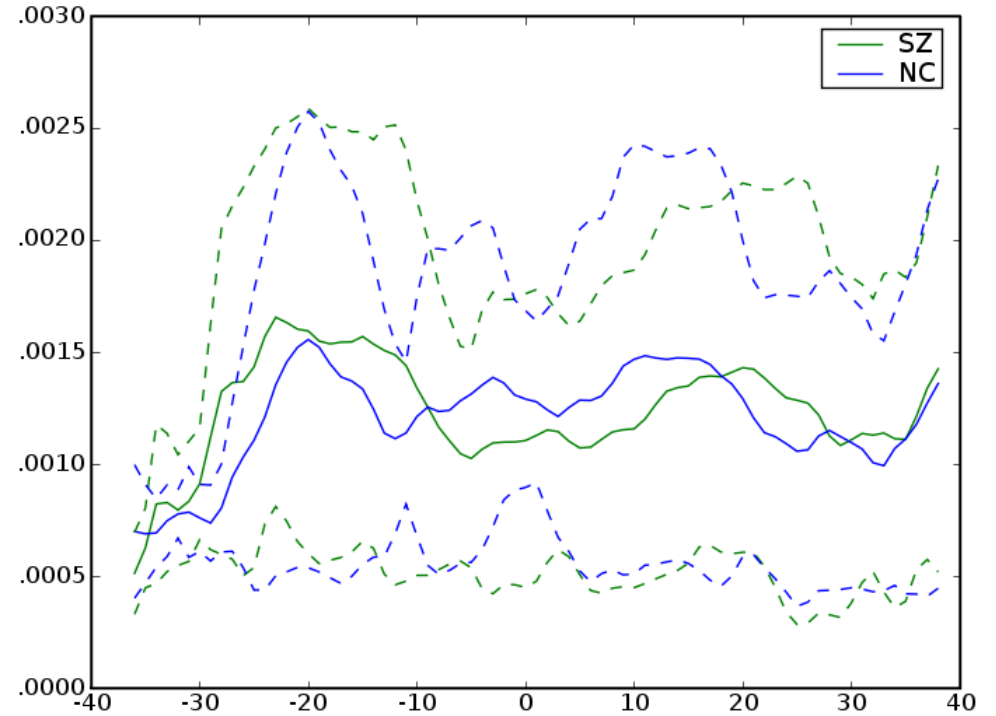
Right Cingulum



Right Cingulum

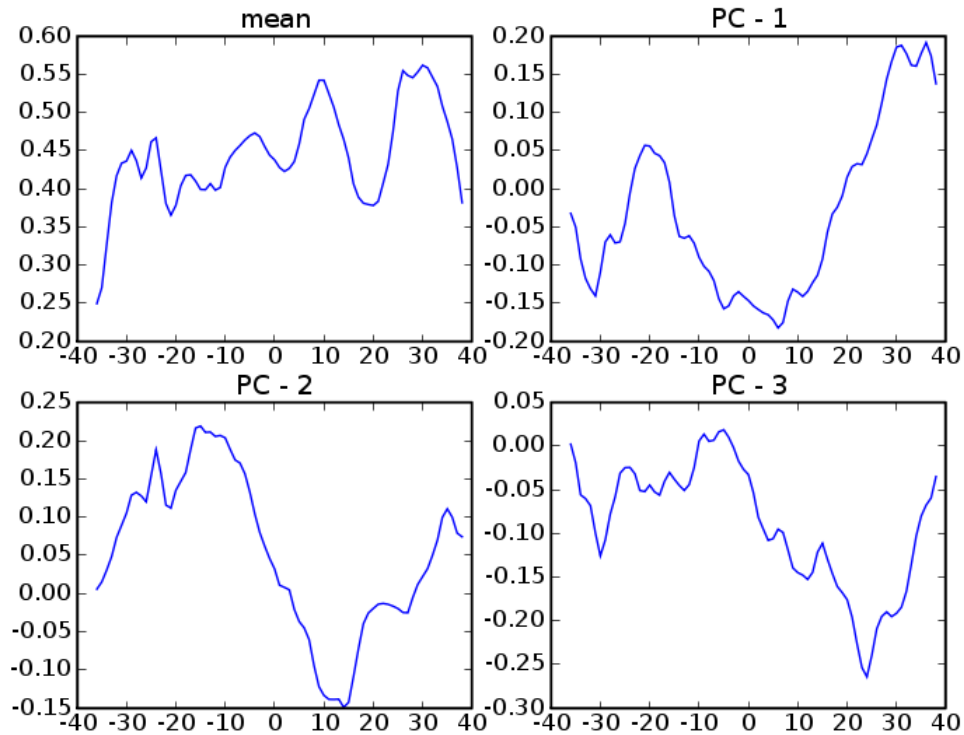


FA

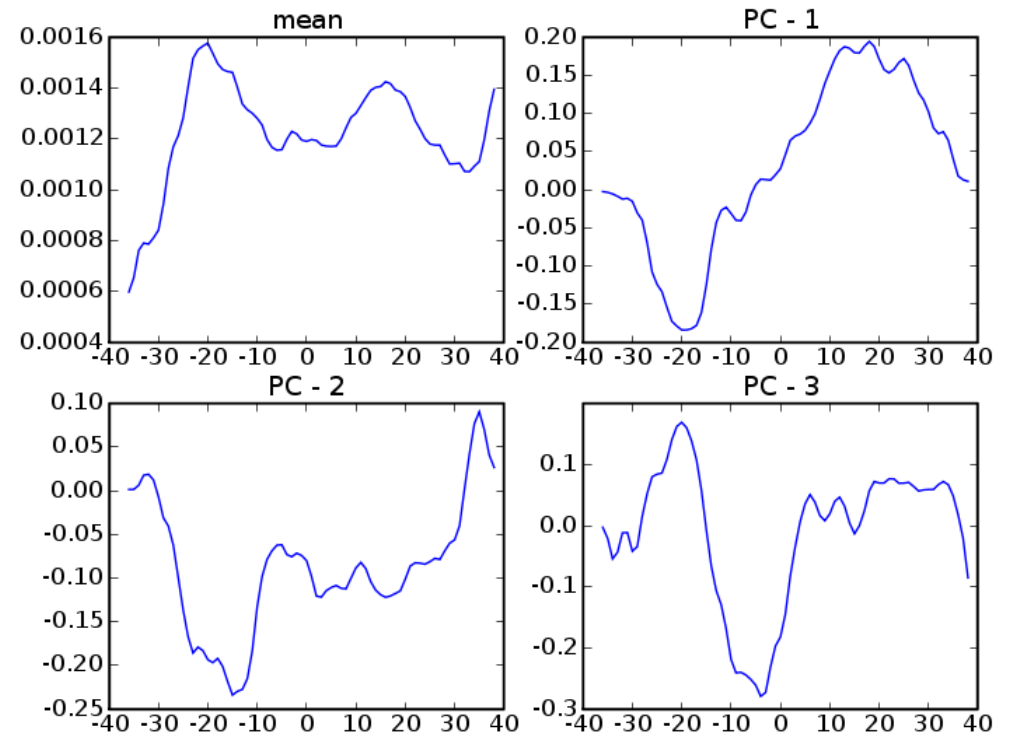


MD

Right Cingulum

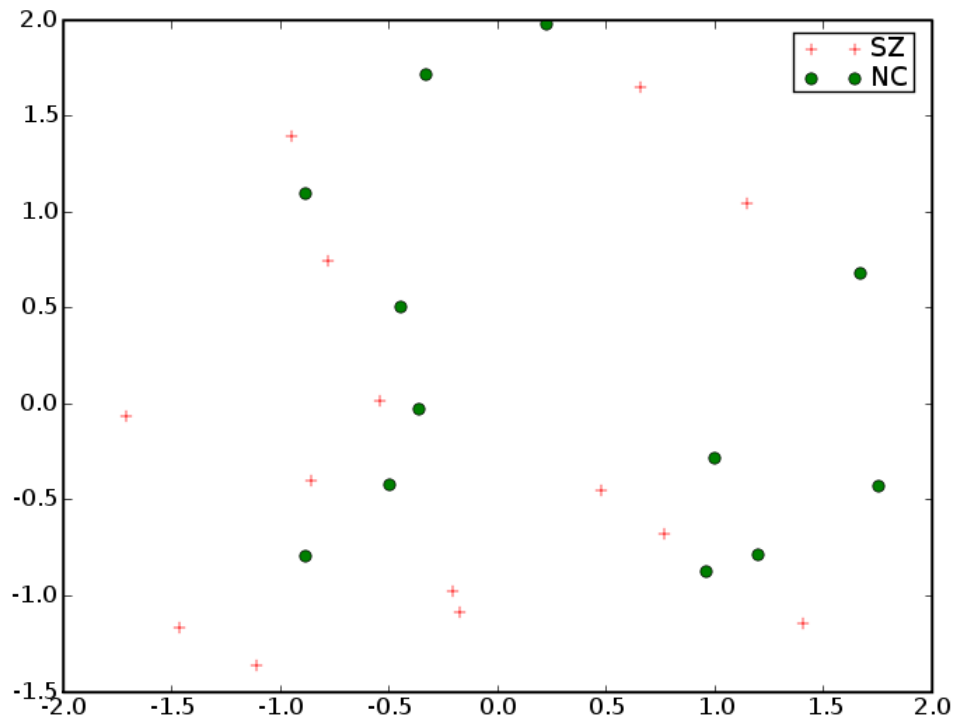


FA

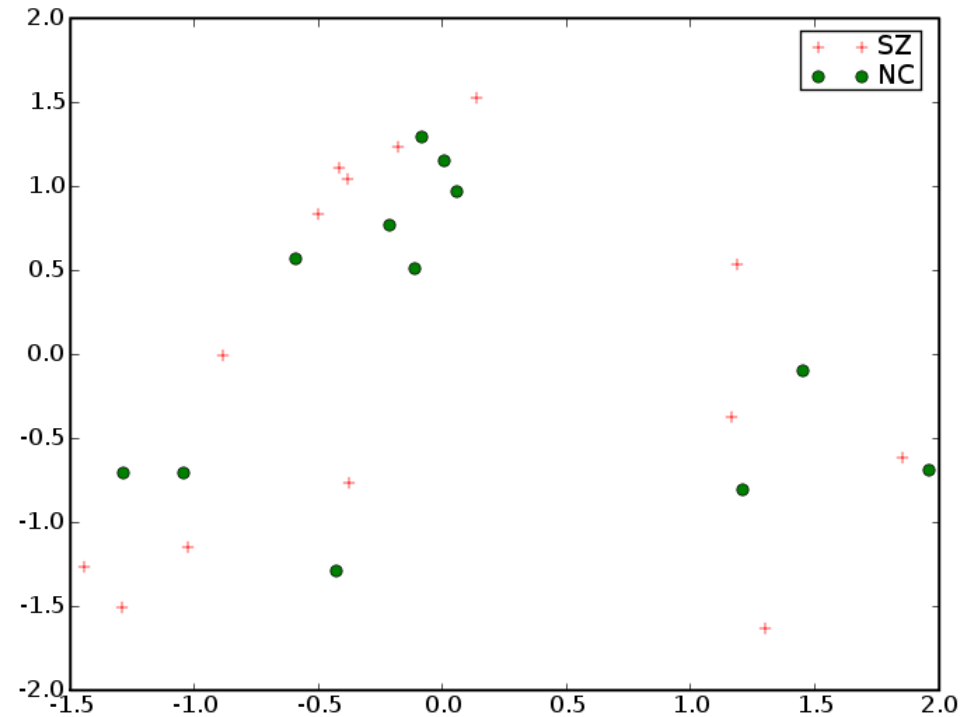


MD

Right Cingulum

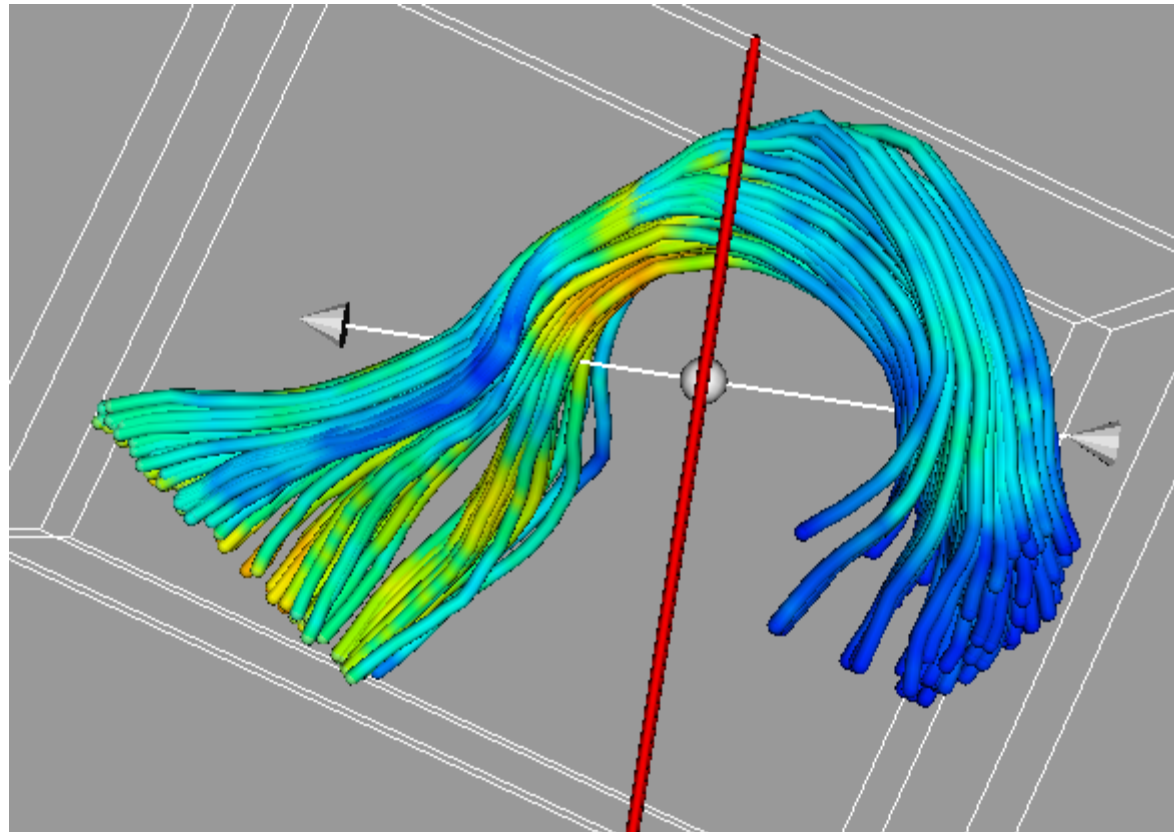


FA

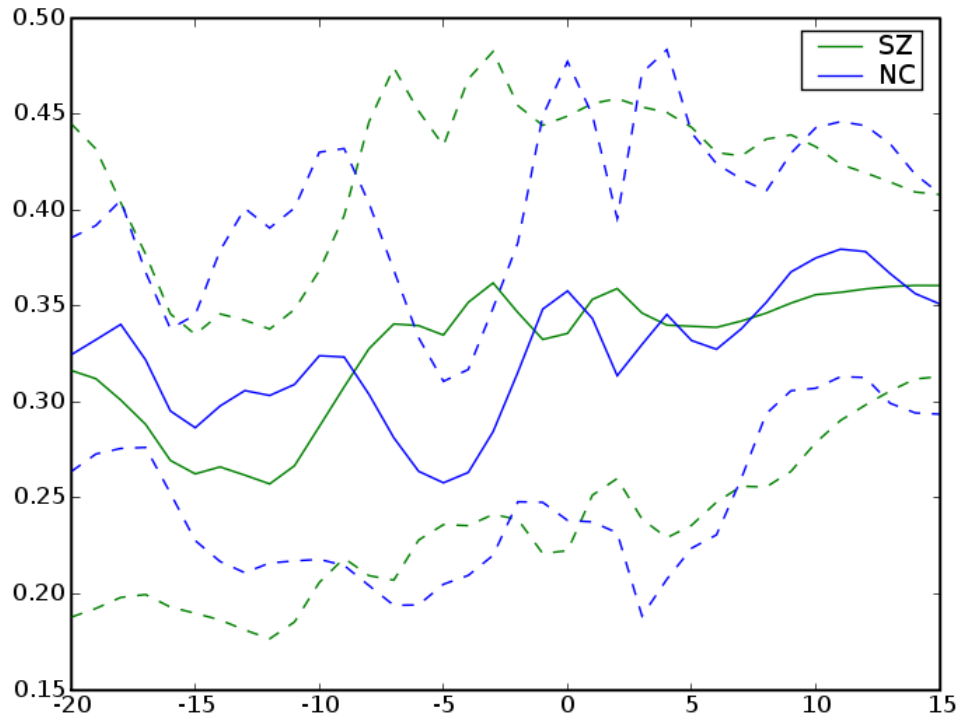


MD

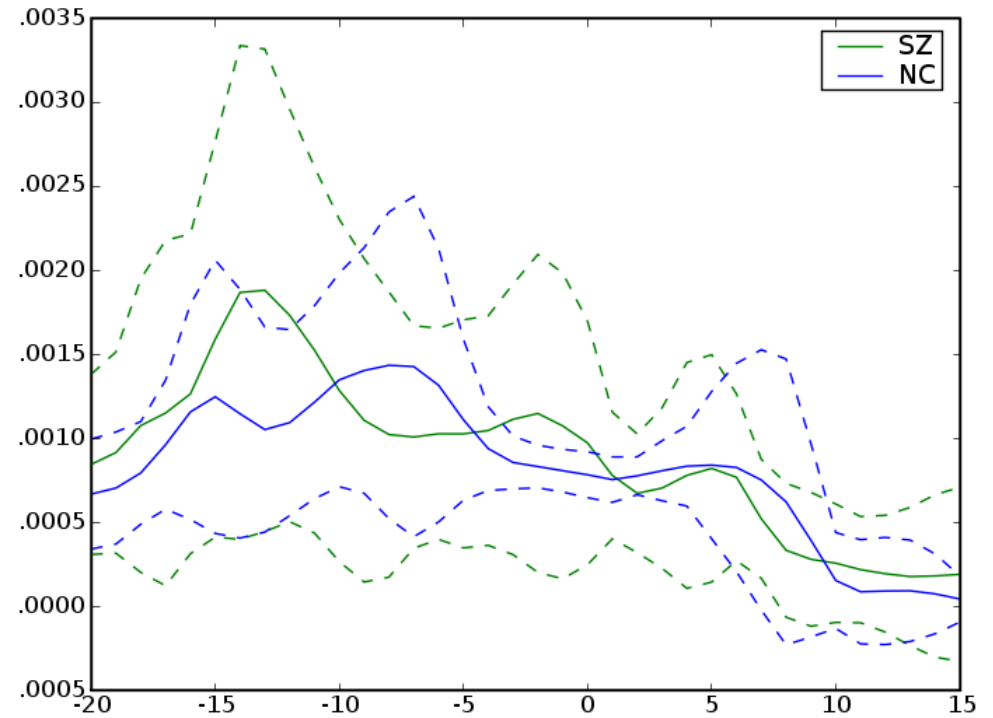
Left Uncinate



Left Uncinate

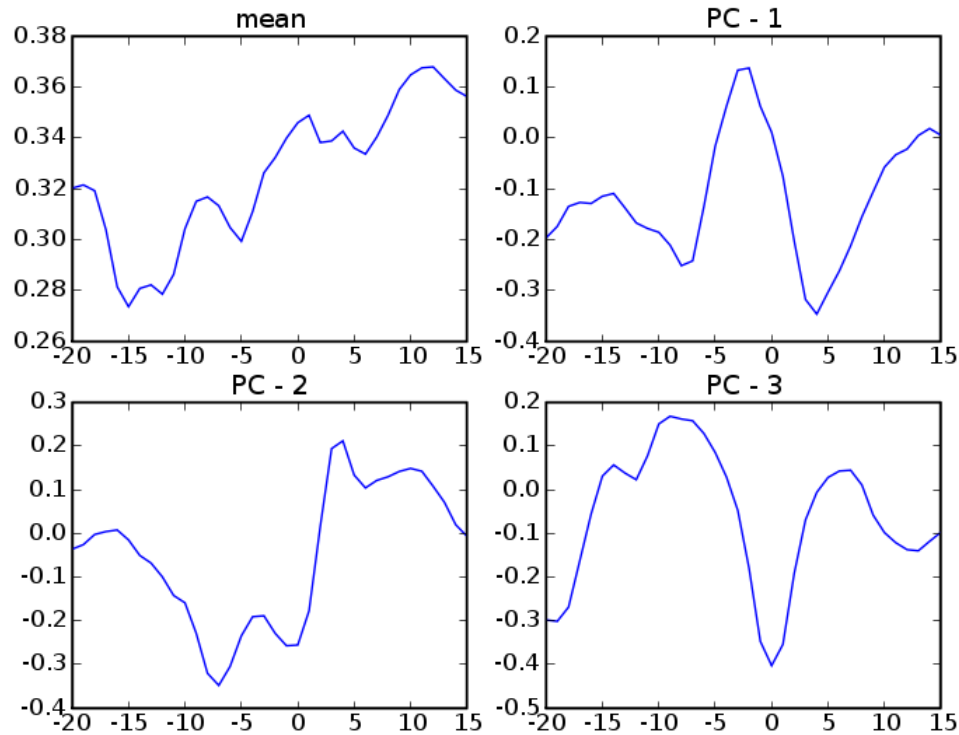


FA

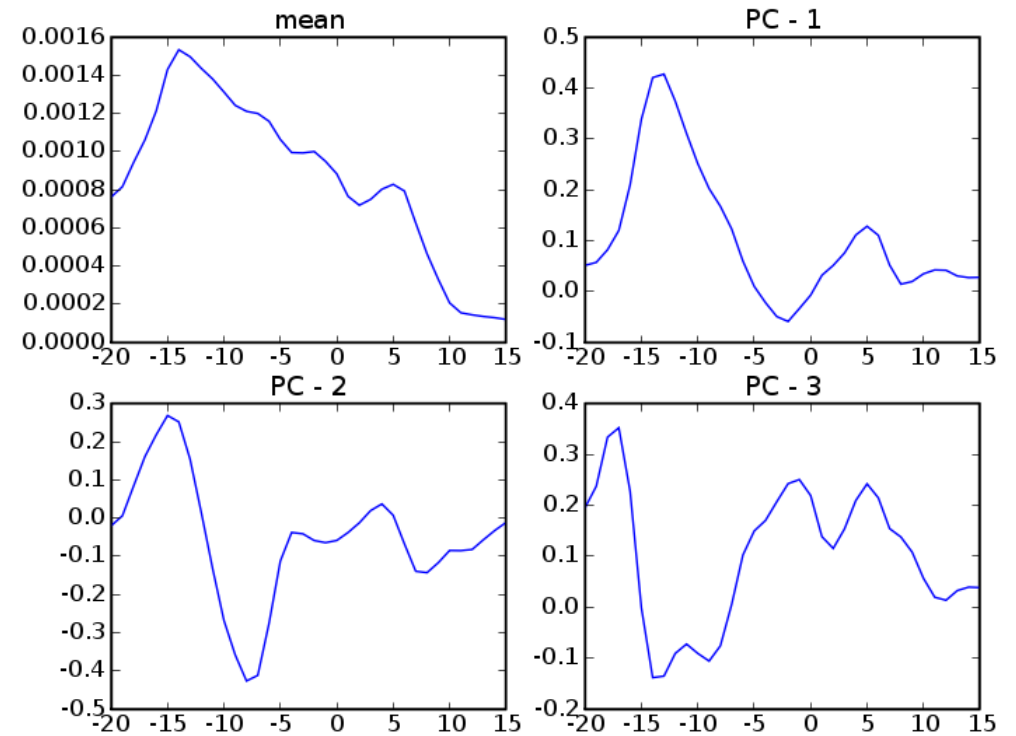


MD

Left Uncinate

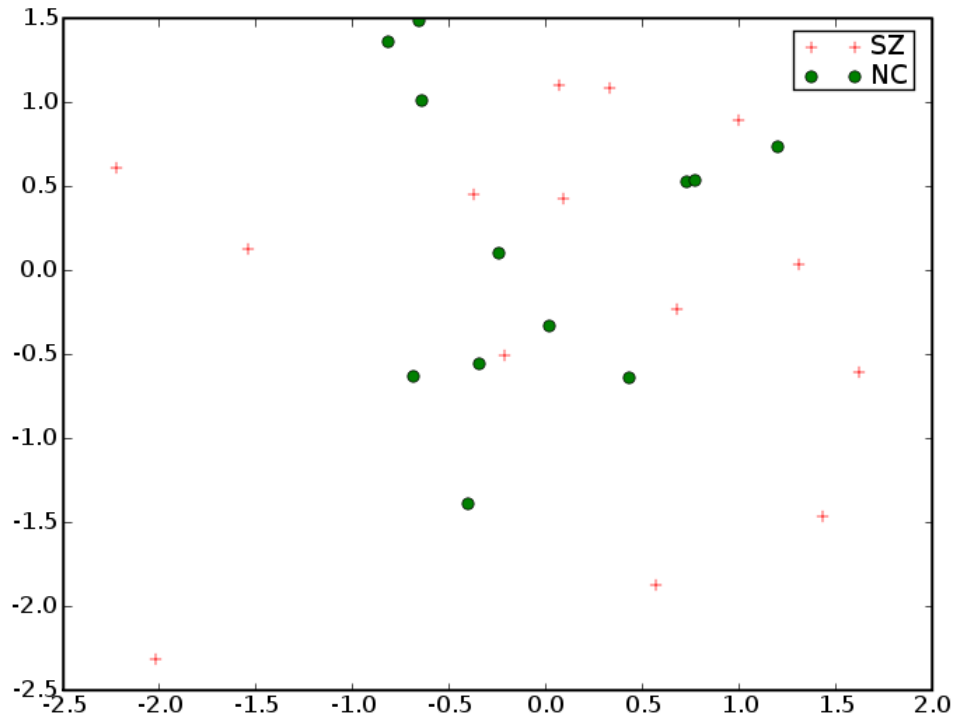


FA

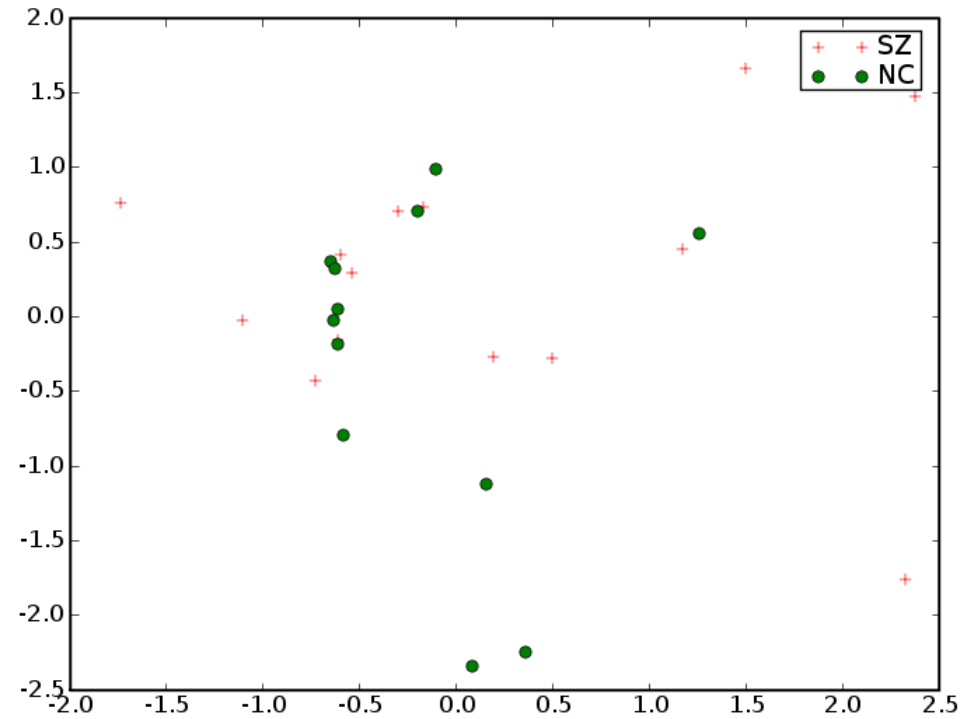


MD

Left Uncinate

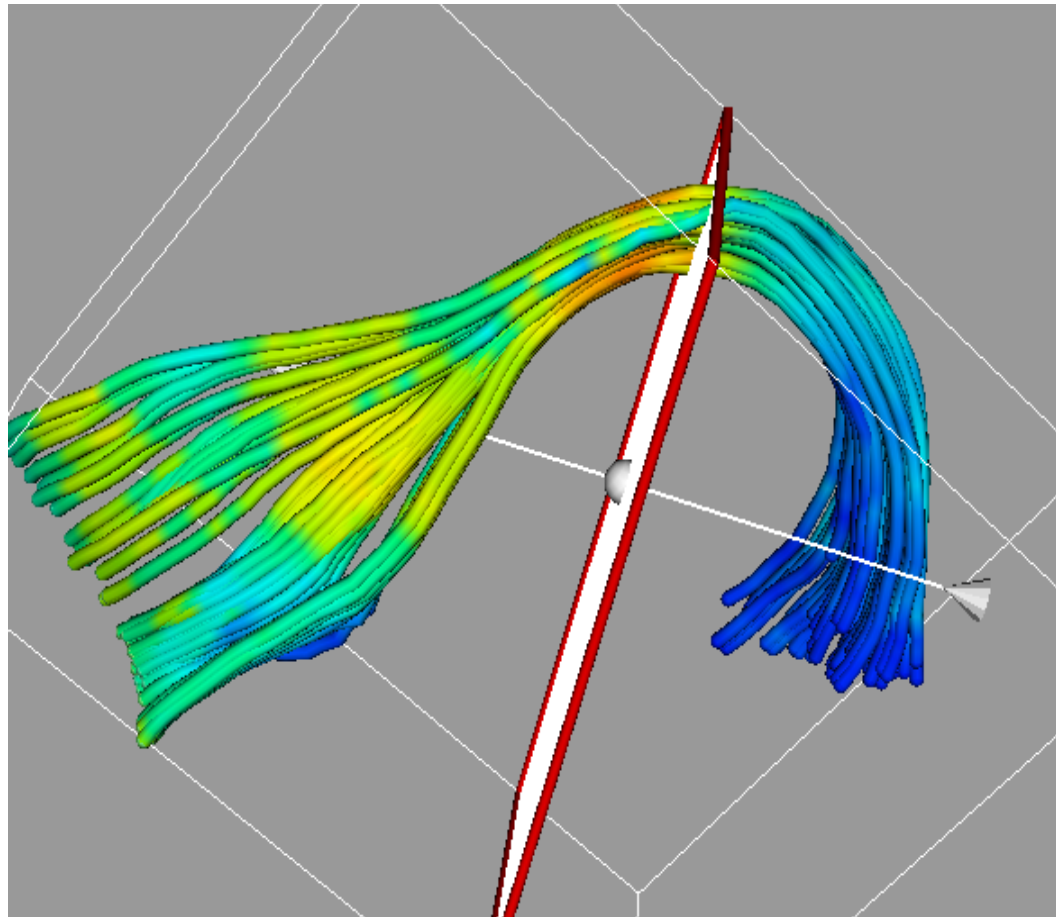


FA

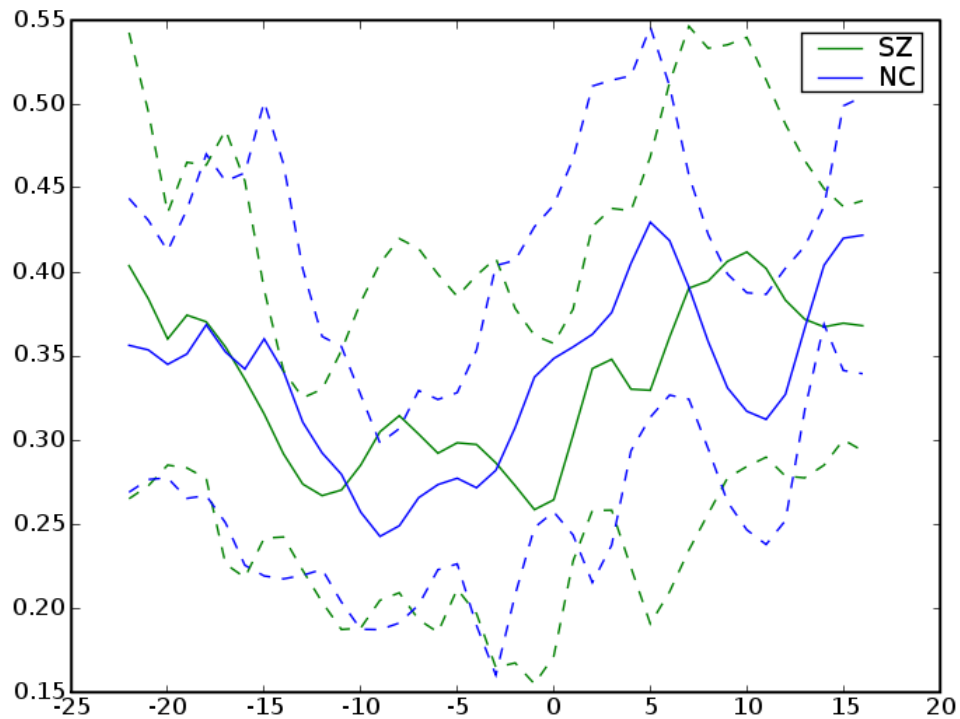


MD

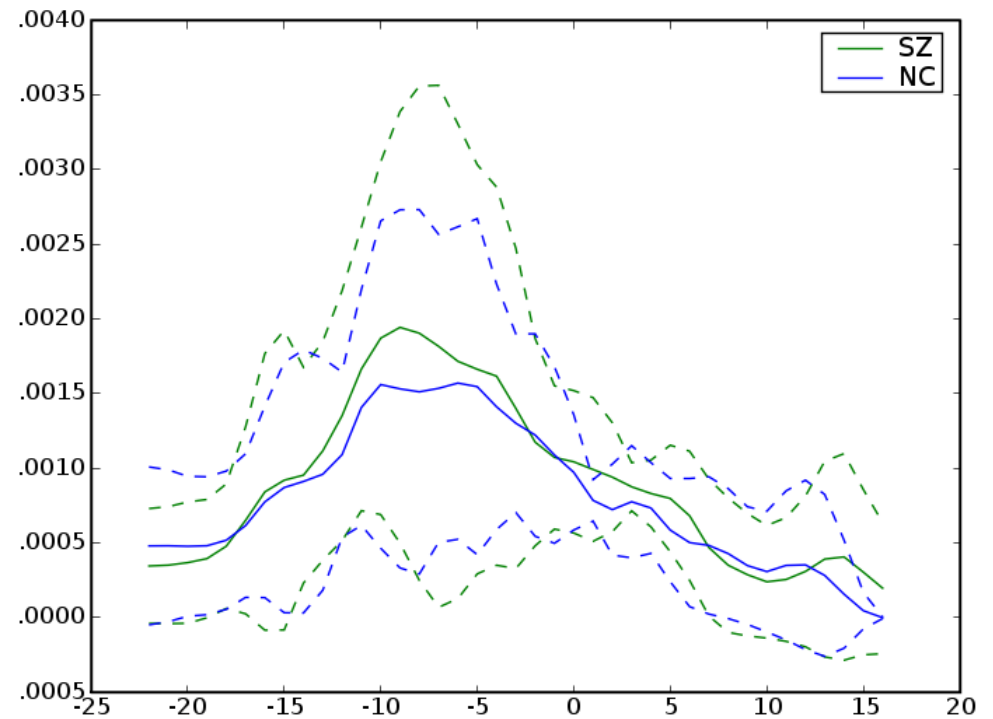
Right Uncinate



Right Uncinate

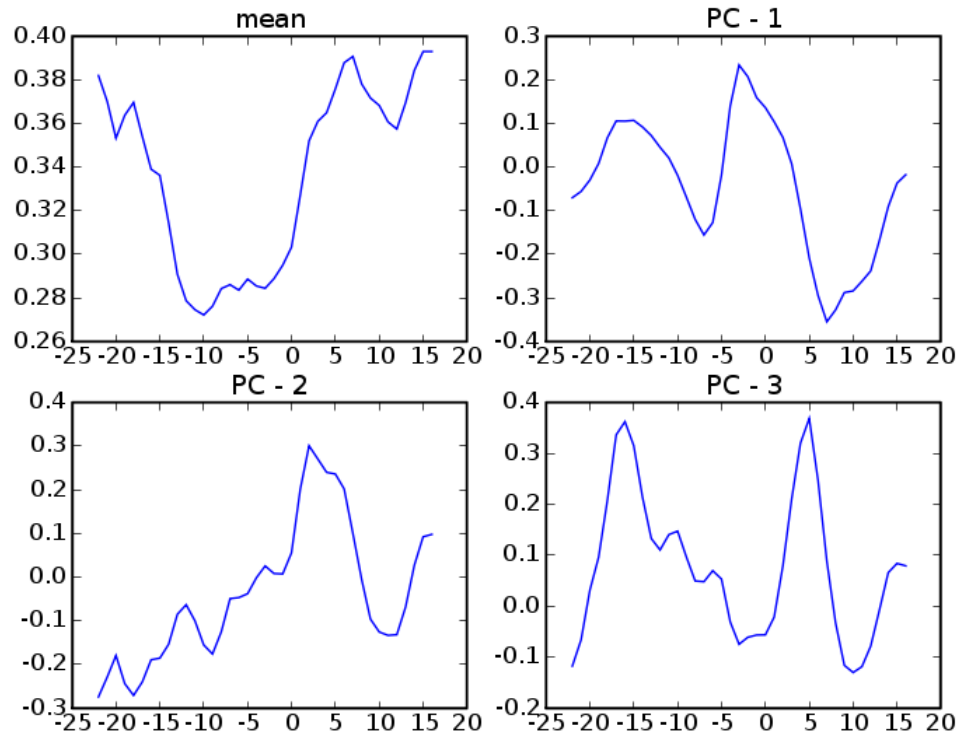


FA

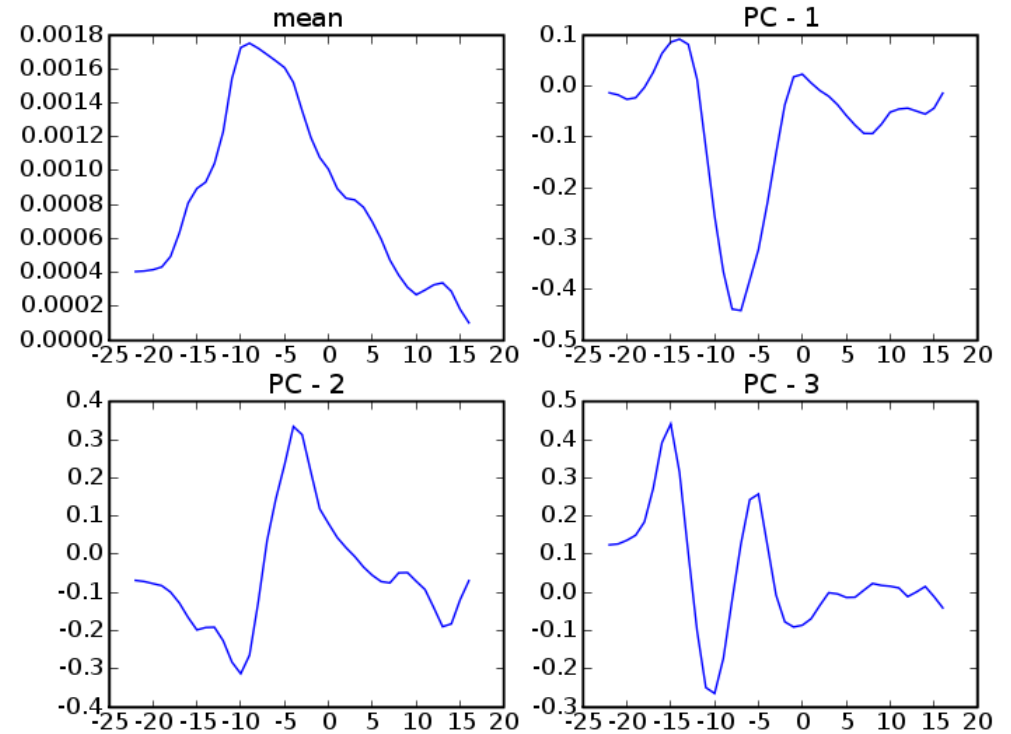


MD

Right Uncinate

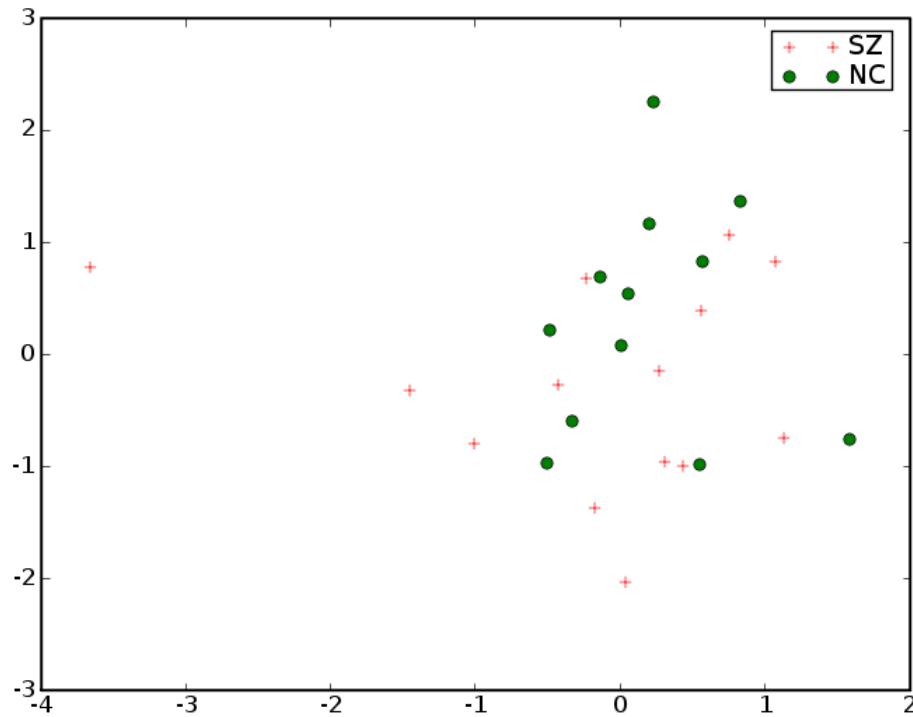


FA

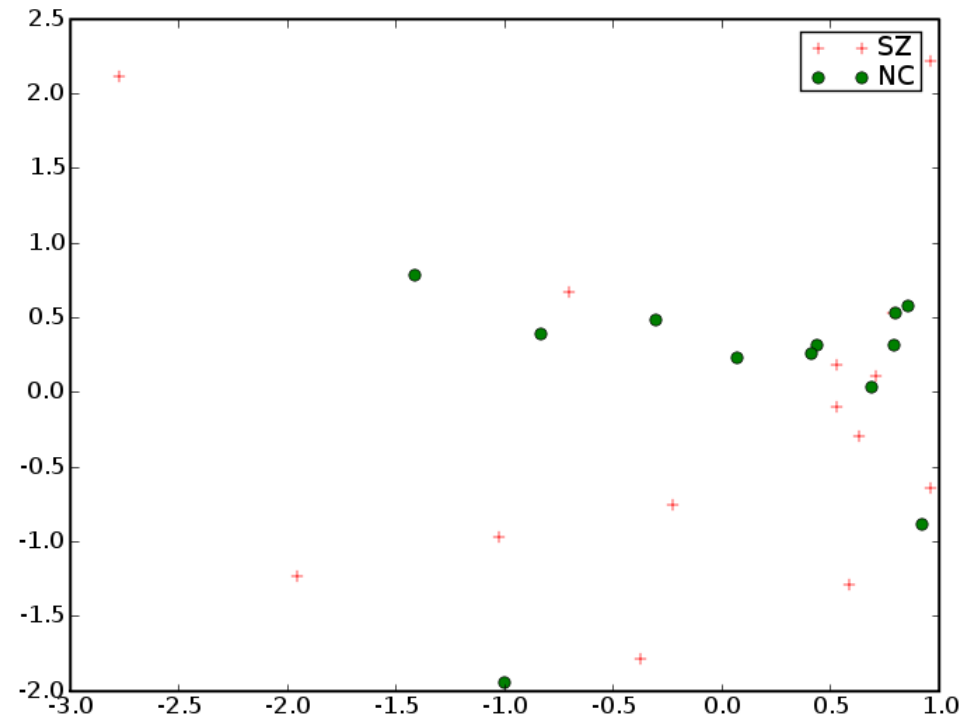


MD

Right Uncinate



FA



MD

Results

- ◆ Lateralization in Internal Capsule, Cingulum,
 - ◆ Possibly due to atlas procedure especially in cingulum
 - ◆ Possibly in original data especially in internal capsule
- ◆ No statistically significant diffusion differences
- ◆ We want to compare the atlas results with individual manual processing

References

- [1] Improved correspondance for DTI population studies via unbiased atlas building. Casey Goodlett, Brad Davis, Remi Jean, Guido Gerig. MICCAI 2006.
- [2] Unbiased diffeomorphic atlas construction for computational anatomy. Sarang Joshi, Brad Davis, Matthieu Jomier, Guido Gerig. NeuroImage vol. 23 Supplement. pgs 151-160. 11/2004
- [3] Functional Data Analysis. Ramsay, J.O.; Silverman, B.W.