

Exploring Peritumoral White Matter Fibers for Neurosurgical Planning

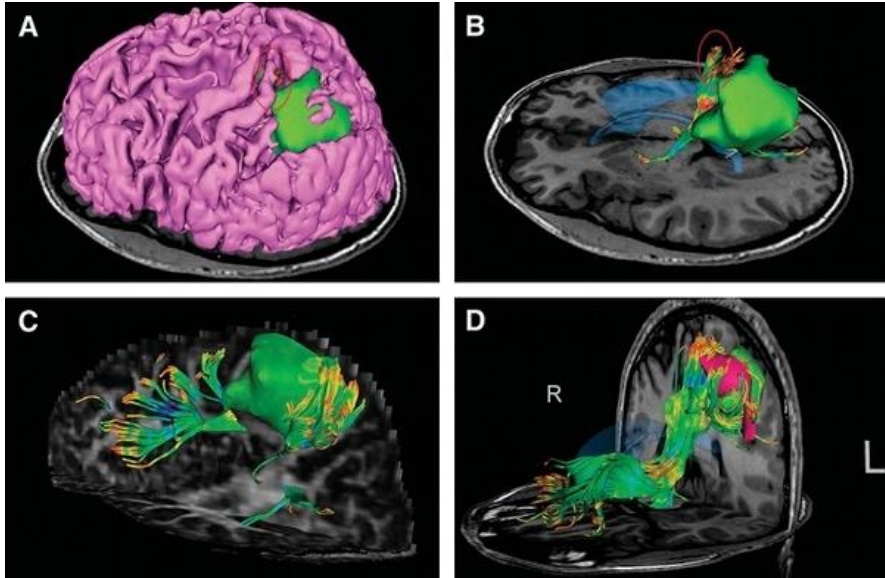
Sonia Pujol, Ph.D.

Ron Kikinis, M.D.

Surgical Planning Laboratory

Harvard University

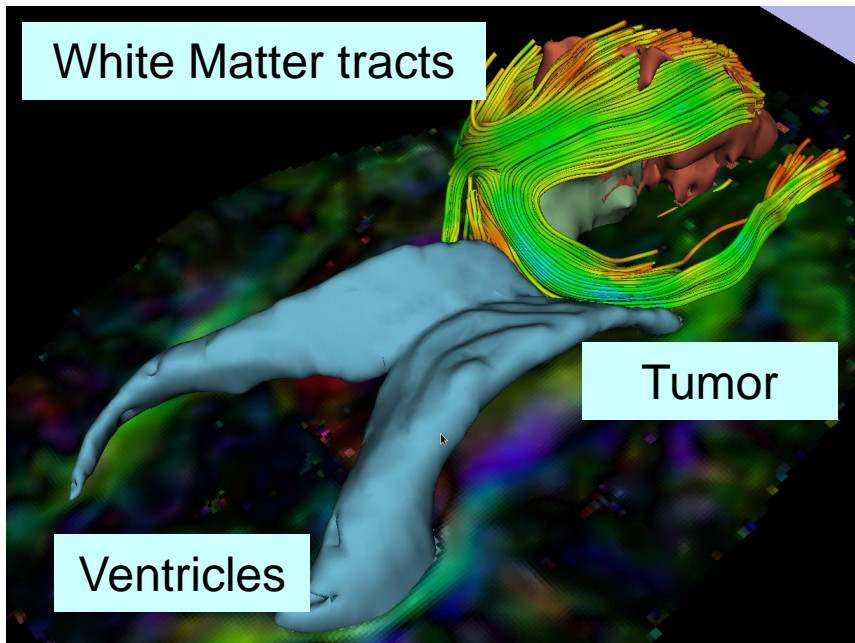
Clinical Goal



Diffusion Tensor Imaging (DTI) Tractography has the potential to bring valuable spatial information on tumor infiltration and tract displacement for neurosurgical planning of tumor resection.

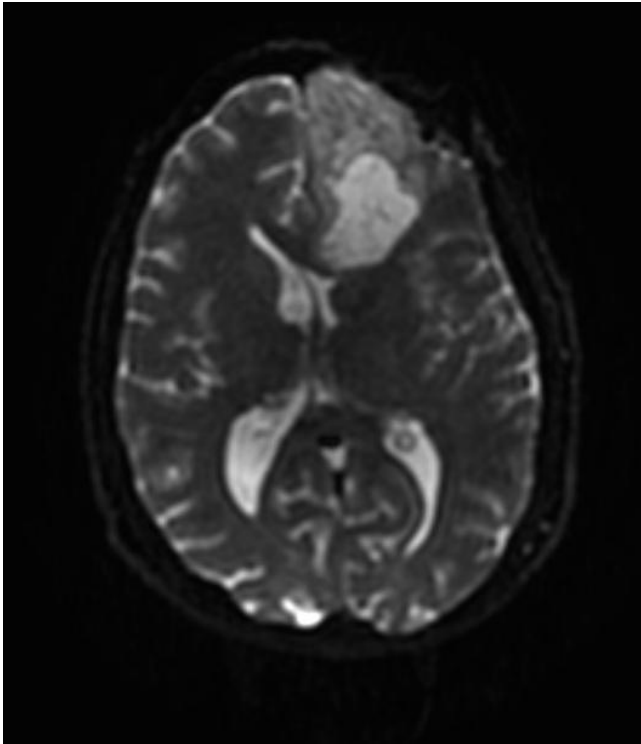
Image Courtesy of Dr. Alexandra Golby, Brigham and Women's Hospital, Boston, MA. *Neurosurgery* 2011 Feb; 68(2):496-505.

Clinical Goal



The goal of this tutorial is to explore white matter fibers surrounding a tumor using Diffusion Tensor Imaging (DTI) Tractography.

Clinical Case

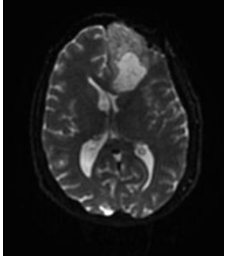


- 35 year-old male diagnosed with Glioblastoma multiforme (GBM)
- Diffusion Weighted Imaging (DWI) acquisition for neurosurgical planning
(White Matter Exploration Dataset)

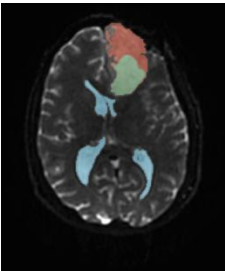
Material

- This tutorial uses the Slicer3.6.3 release version available at www.slicer.org
- Windows XP: Slicer3-3.6.3-2011-03-04-win32.exe
- Mac OS: Slicer3-3.6.3-2011-03-04-darwin-x86
- Linux_x86: Slicer3-3.6.3-2011-03-04-linux-x86
- Linux_x86_64: Slicer3-3.6.3-2011-03-04-linux-x86_64

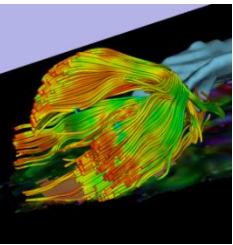
Overview of the analysis pipeline




Part 1: Loading & Visualization of Diffusion Data



Part 2: Segmentation of the ventricles, and solid and cystic parts of the tumor

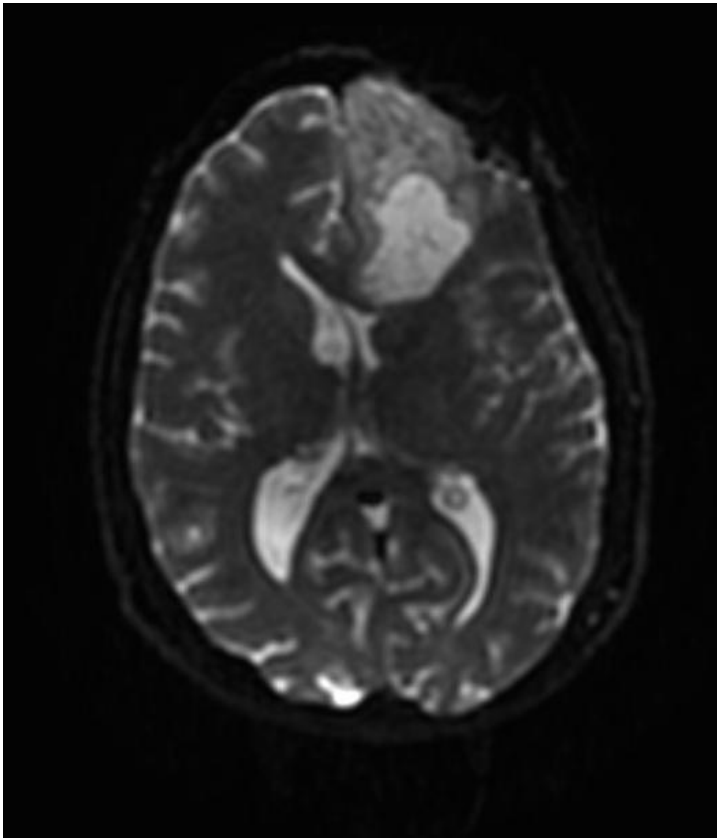


Part 3: Tractography reconstruction of the white matter fibers in the peri-tumoral volume



Part 4: Tractography exploration of the ipsilateral and contralateral side

Part 1: Loading and Visualization of Diffusion Data

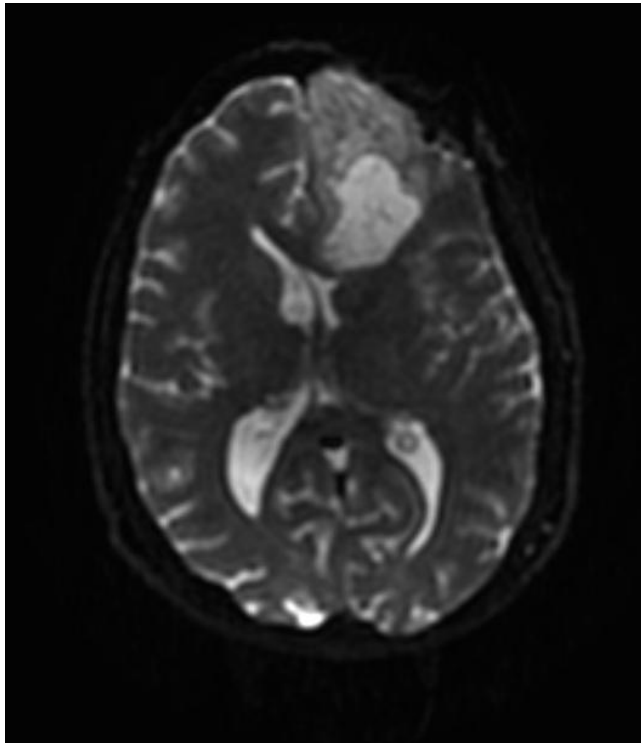



Diffusion Tensor Imaging

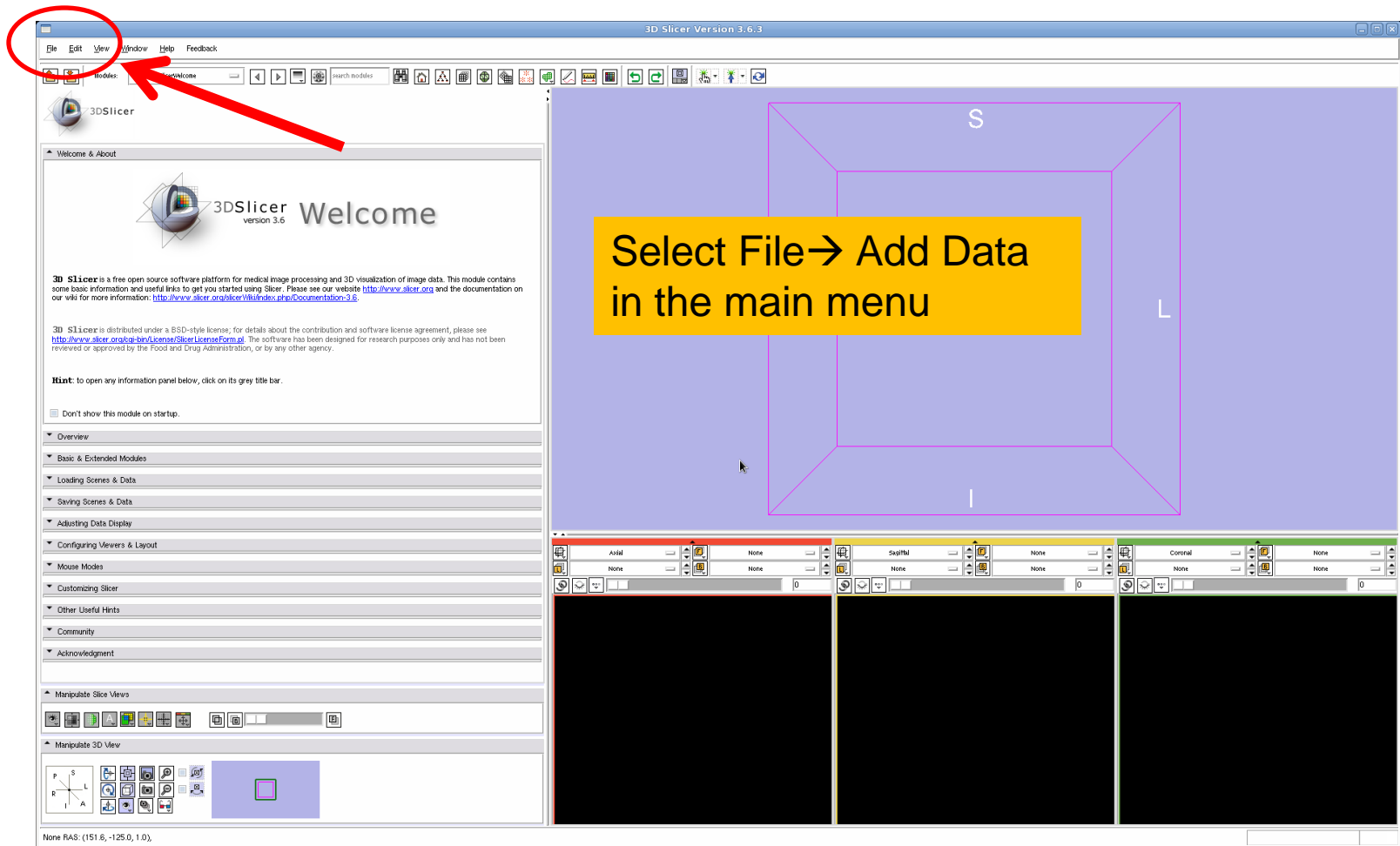
$$S_i = S_0 e^{-b \hat{g}_i^T \underline{D} \hat{g}_i}$$

(Stejskal and Tanner 1965, Basser 1994)

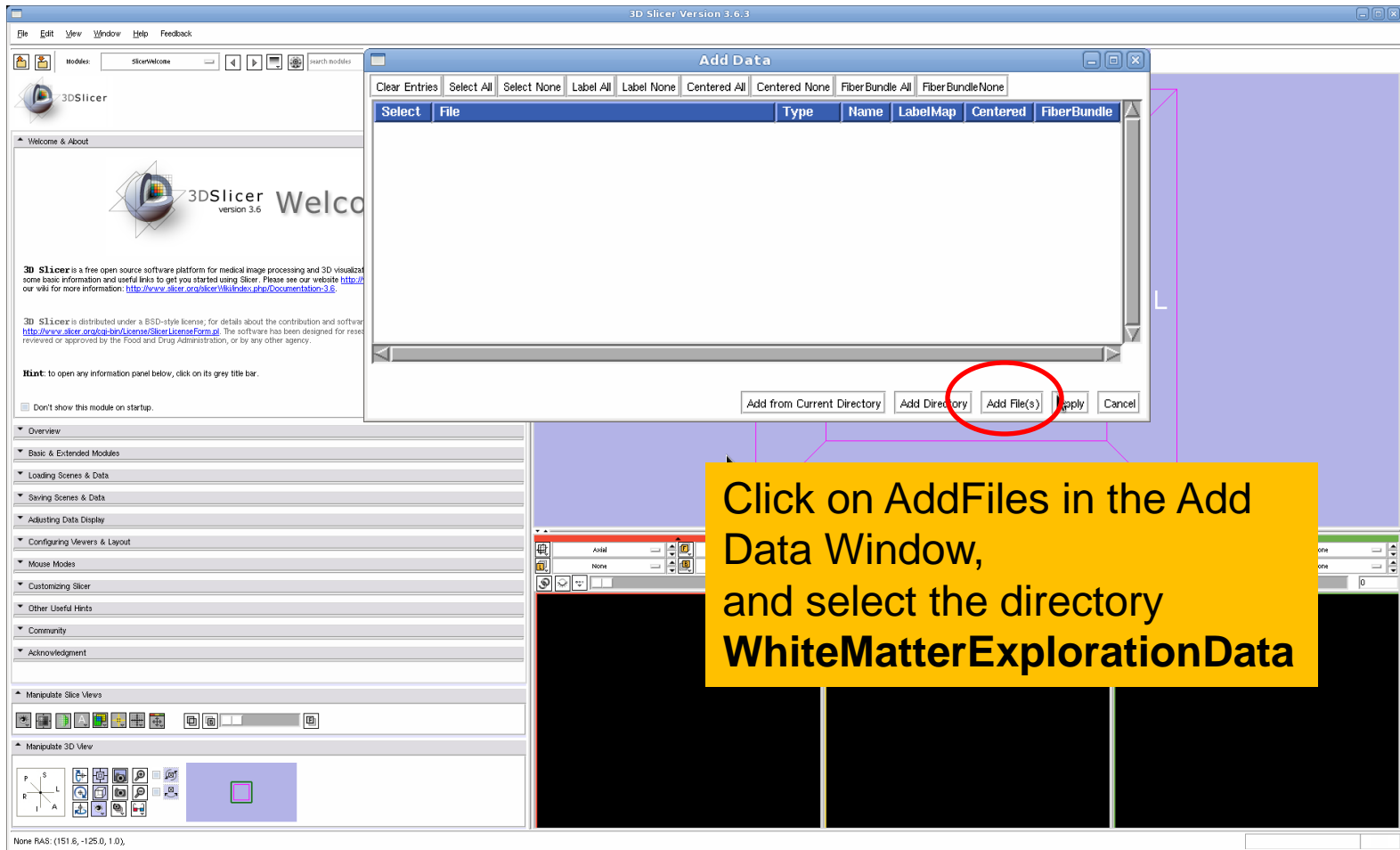
$$\underline{D} = \begin{bmatrix} D_{xx} & D_{xy} & D_{xz} \\ D_{yx} & D_{yy} & D_{yz} \\ D_{zx} & D_{zy} & D_{zz} \end{bmatrix}$$



Loading DTI and Baseline Data



Loading DTI and Baseline Data



Loading DTI and Baseline Data

Name	Size	Modified time
Baseline Volume.nrrd	2,743 KB	11/01/10 10:20:03
DTI Volume.nhdr	1 KB	11/01/10 10:20:00
DTI Volume.raw.gz	10,678 KB	11/01/10 10:20:00

File name: Open

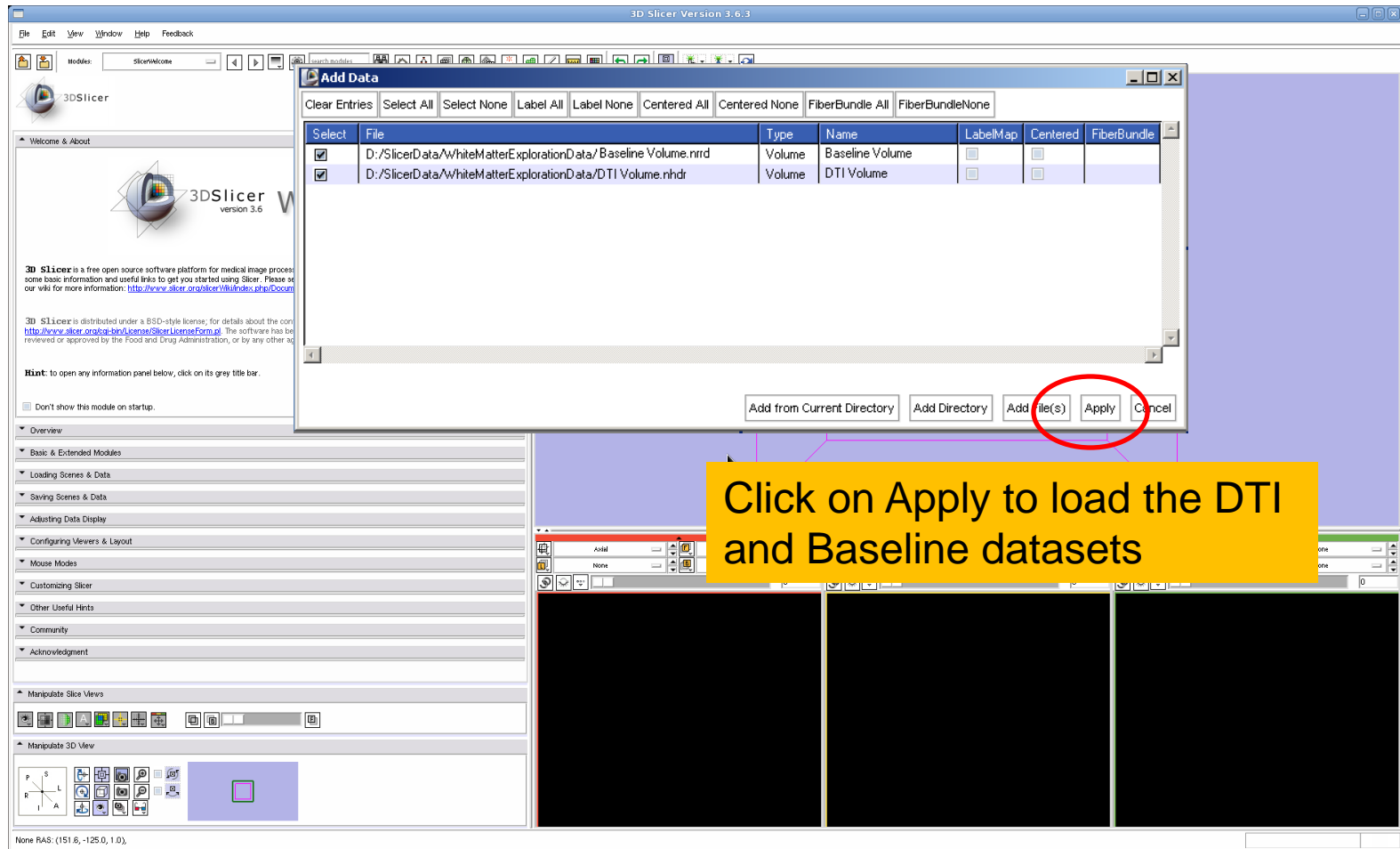
Files of type: All Files (*.*) Cancel

None RAS: (151 6, -125 0, 1 0).

Select the directory **WhiteMatterExplorationData**

Select the files **BaselineVolume.nrrd** and **DTIVolume.nhdr** and click on **Open**

Loading DTI and Baseline Data



Loading DTI and Baseline Data

3D Slicer Version 3.6.3

File Edit View Window Help Feedback

modules Volumes

3DSlicer

Help & Acknowledgement

Load

Select Volume File

Volume Name: Output Baseline Volume

Image Origin: From File

Image Orientation: From File

Label Map: Single File

Keep all Apply Previous Next

Active Volume: Output Baseline Volume

Display

Lookup Table: Grey

Interpolate

Window Level Editor Presets: CT-abdomen CT-brain CT-lung

Volume Window Level Presets:

Window/Level: Manual 5003 18197

Threshold: Off 0 18197

Update Histogram Interactively

[0, 18197] x [0, 1]

Update Display On Load

Manipulate Slice Views


Manipulate 3D View

Axial None None

Sagittal None Baseline Volume

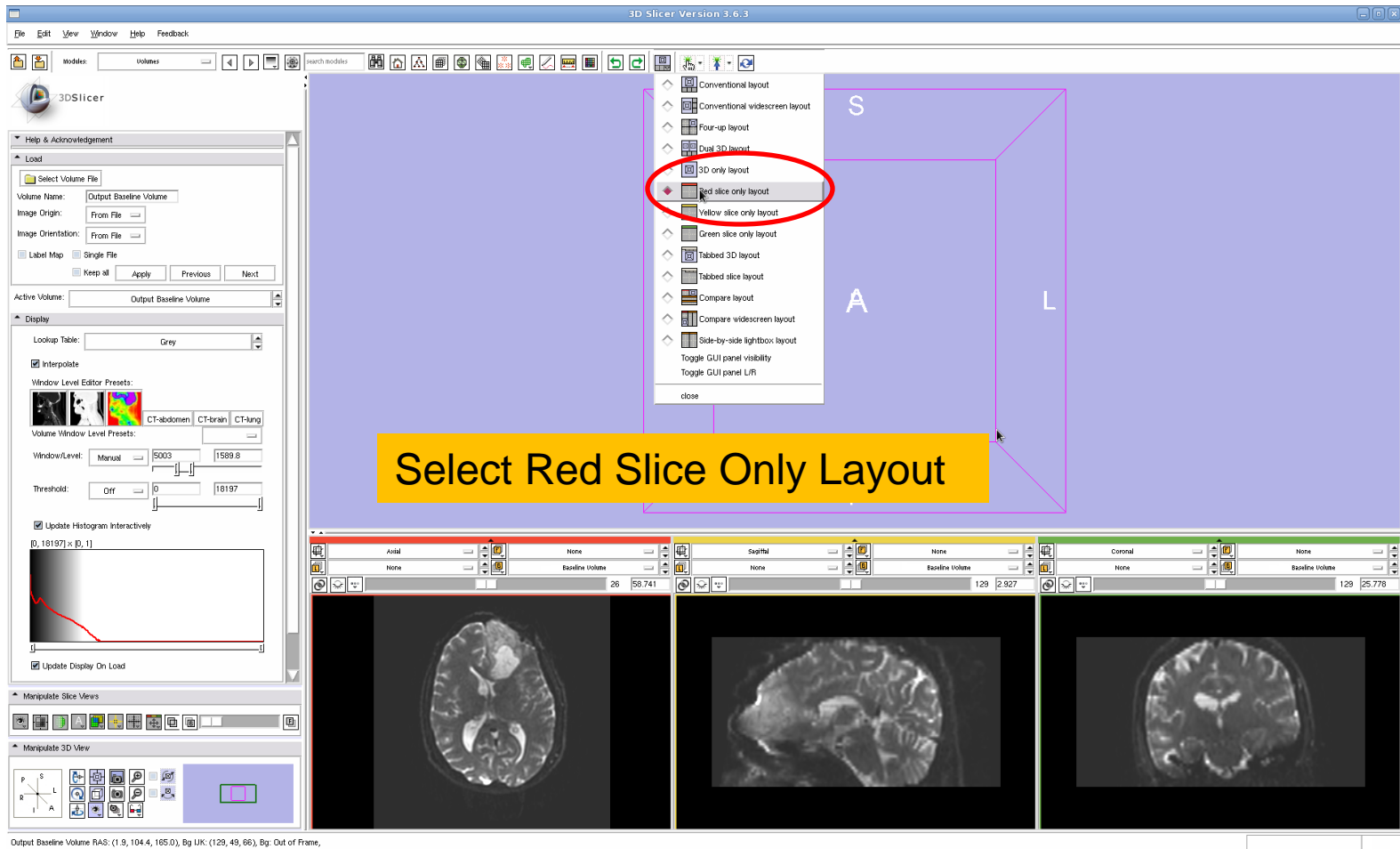
Coronal None Baseline Volume

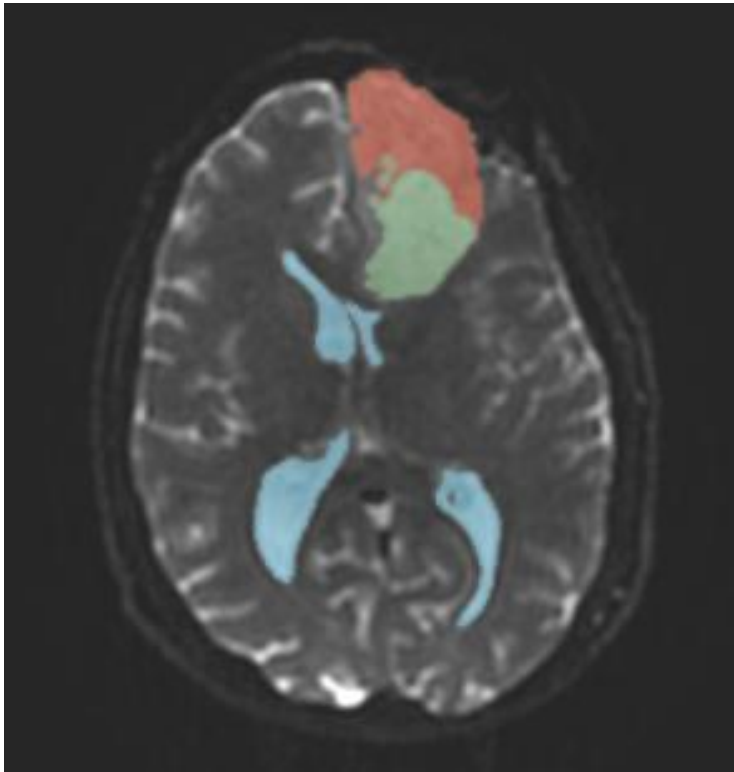
Output Baseline Volume RAS: (1.9, 104.4, 165.0), Bg IJK: (129, 49, 66), Bg: Out of Frame.

Click on the link icon  to link the three anatomical viewers, and set the Baseline volume in Background

Select the module **Volumes** and adjust the Window and Level values of the Baseline Volume.

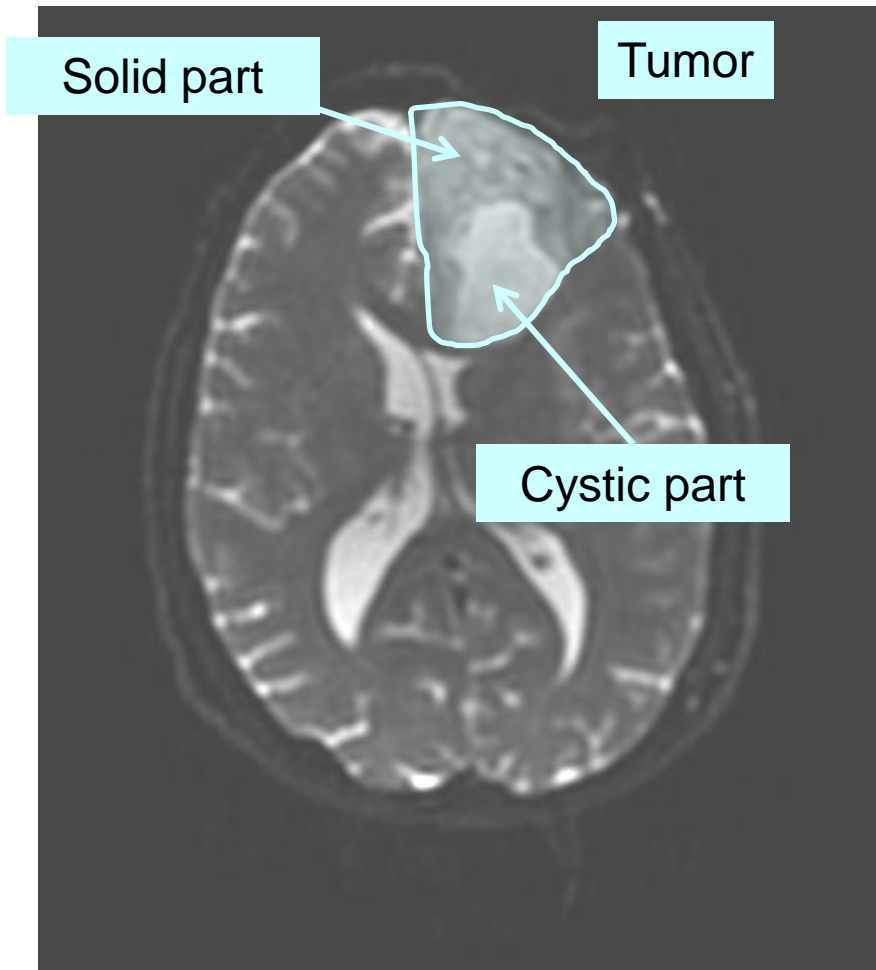
Loading DTI and Baseline Data





Part 1: Segmenting the tumor and ventricles

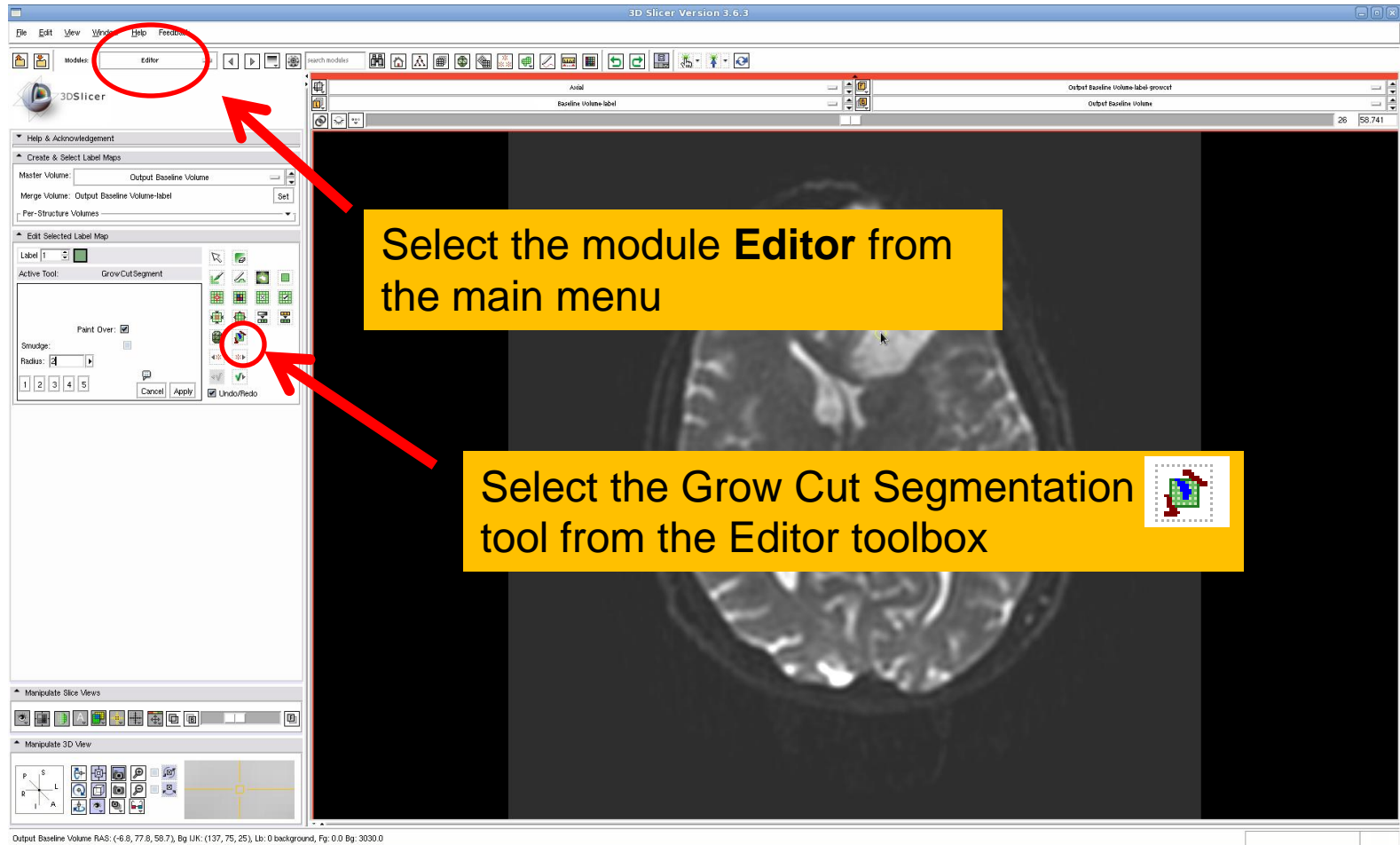
Tumor Segmentation



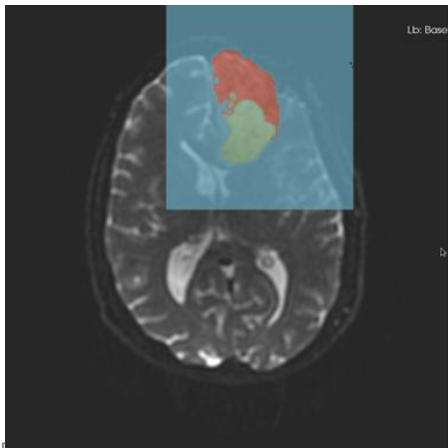
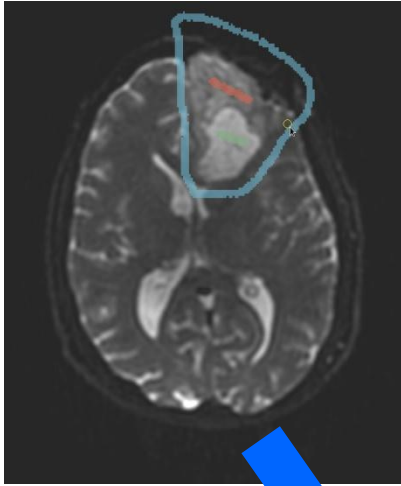
The tumor in this clinical case is composed of two parts: a solid part, and a cystic part.

In this section, we'll segment the different parts of the tumor using a Grow Cut Segmentation algorithm.

Tumor Segmentation

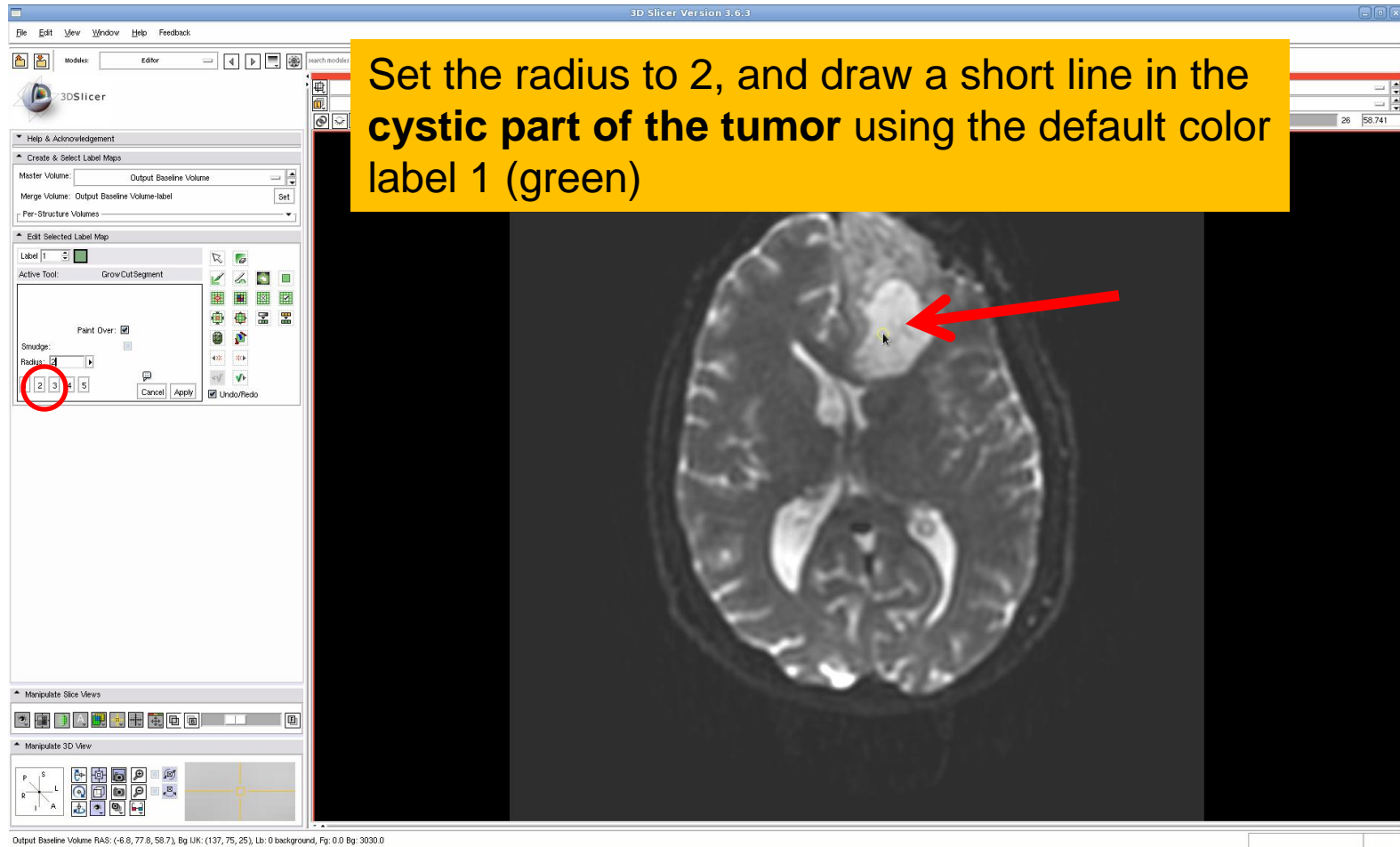


Grow Cut Segmentation

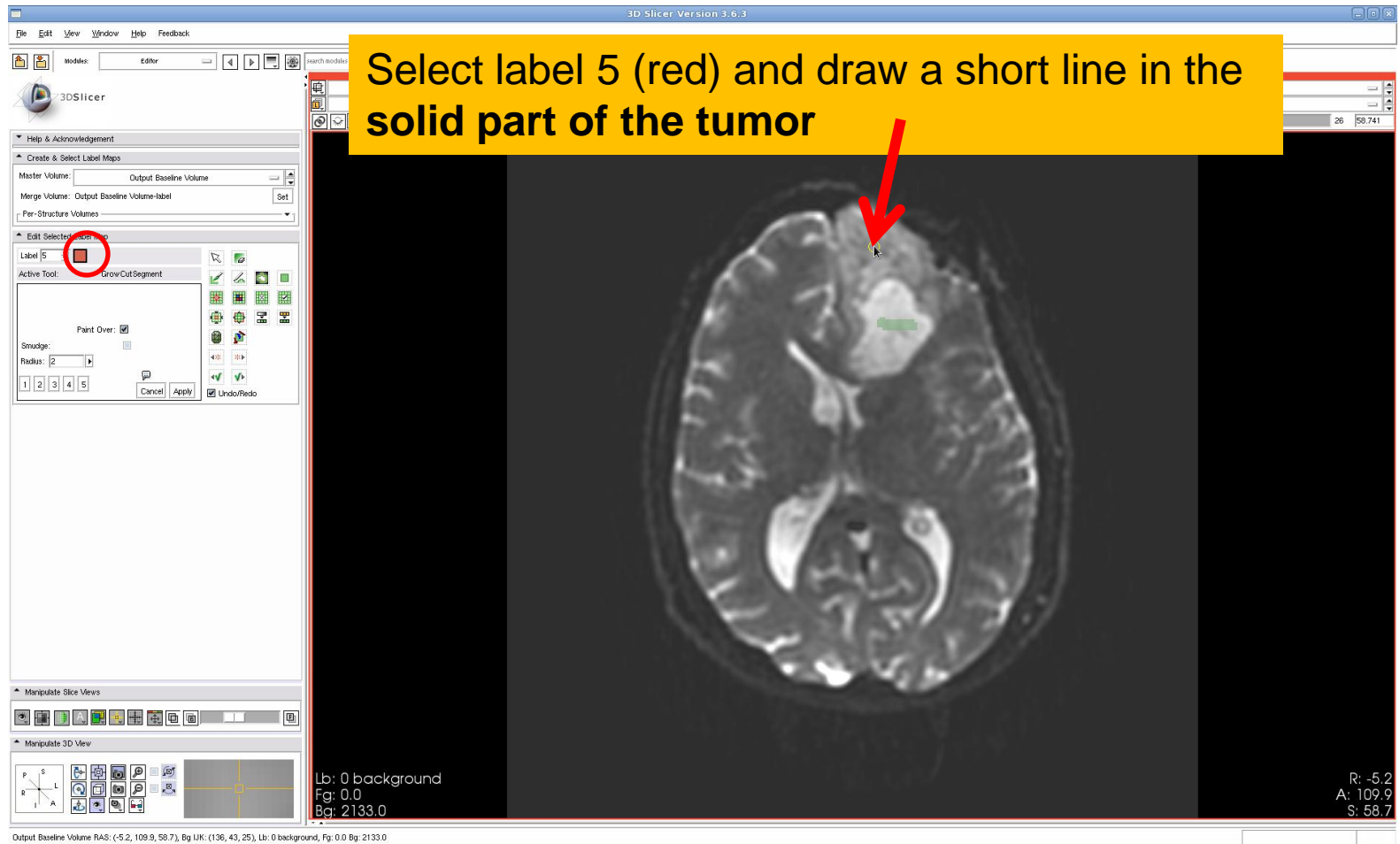


- The **Grow Cut Segmentation** method is a competitive region growing algorithm using Cellular Automata.
- The algorithm performs multi-label image segmentation using a set of user input scribbles.
- V. Vezhnevets, V. Konouchine. "Grow-Cut" - Interactive Multi-Label N-D Image Segmentation". *Proc. Graphicon*. 2005 . pp. 150–156.

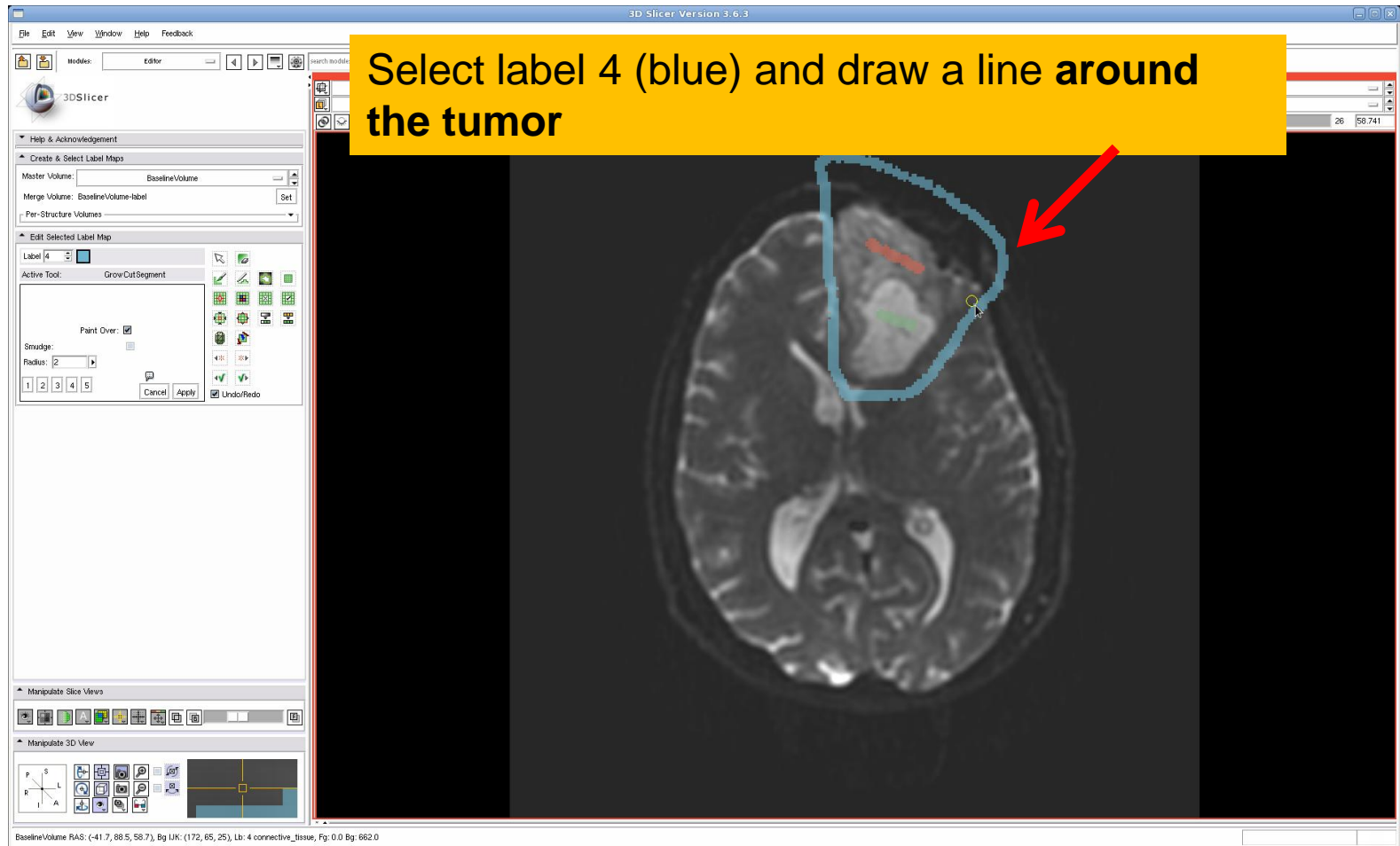
Tumor Segmentation



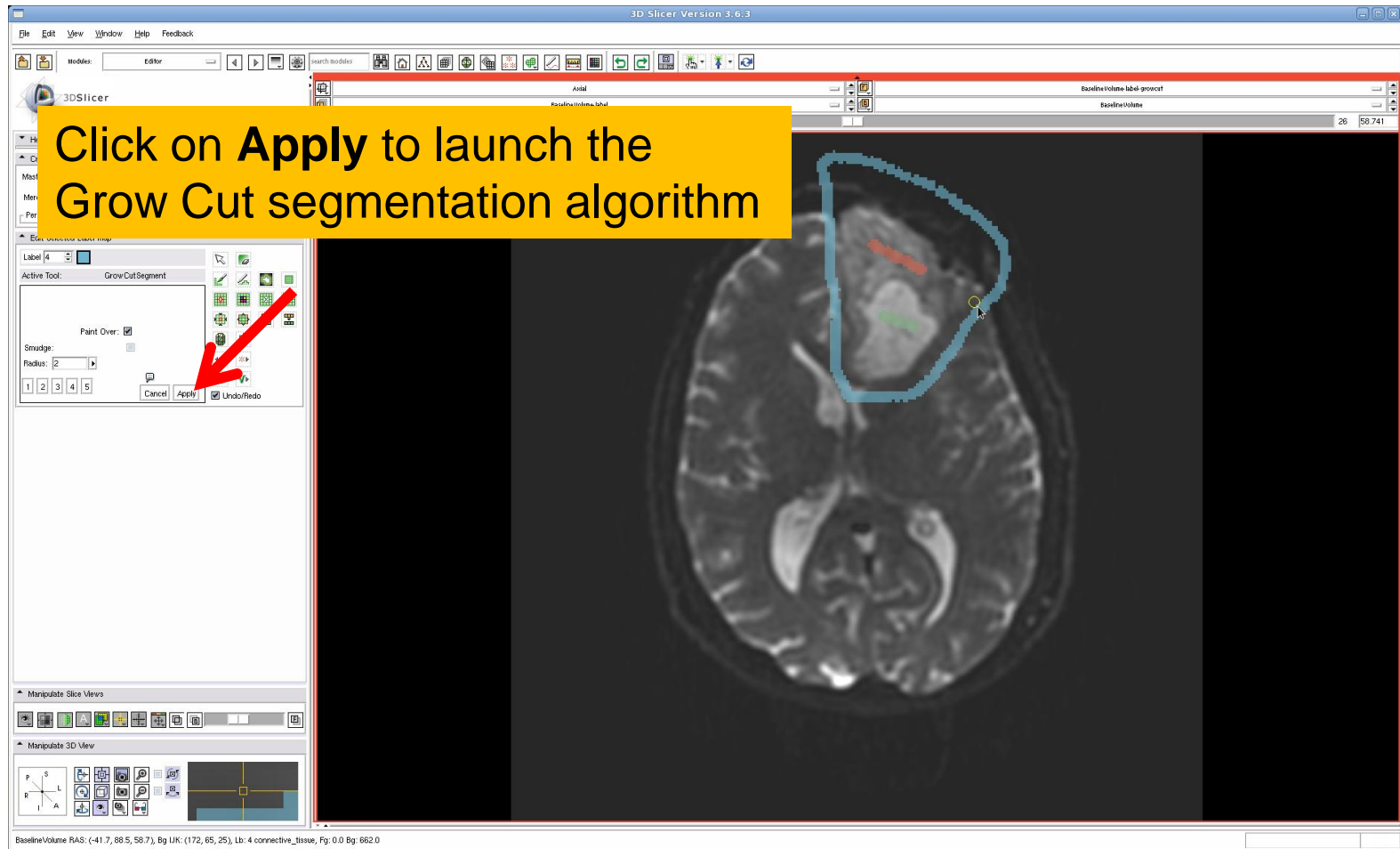
Tumor Segmentation



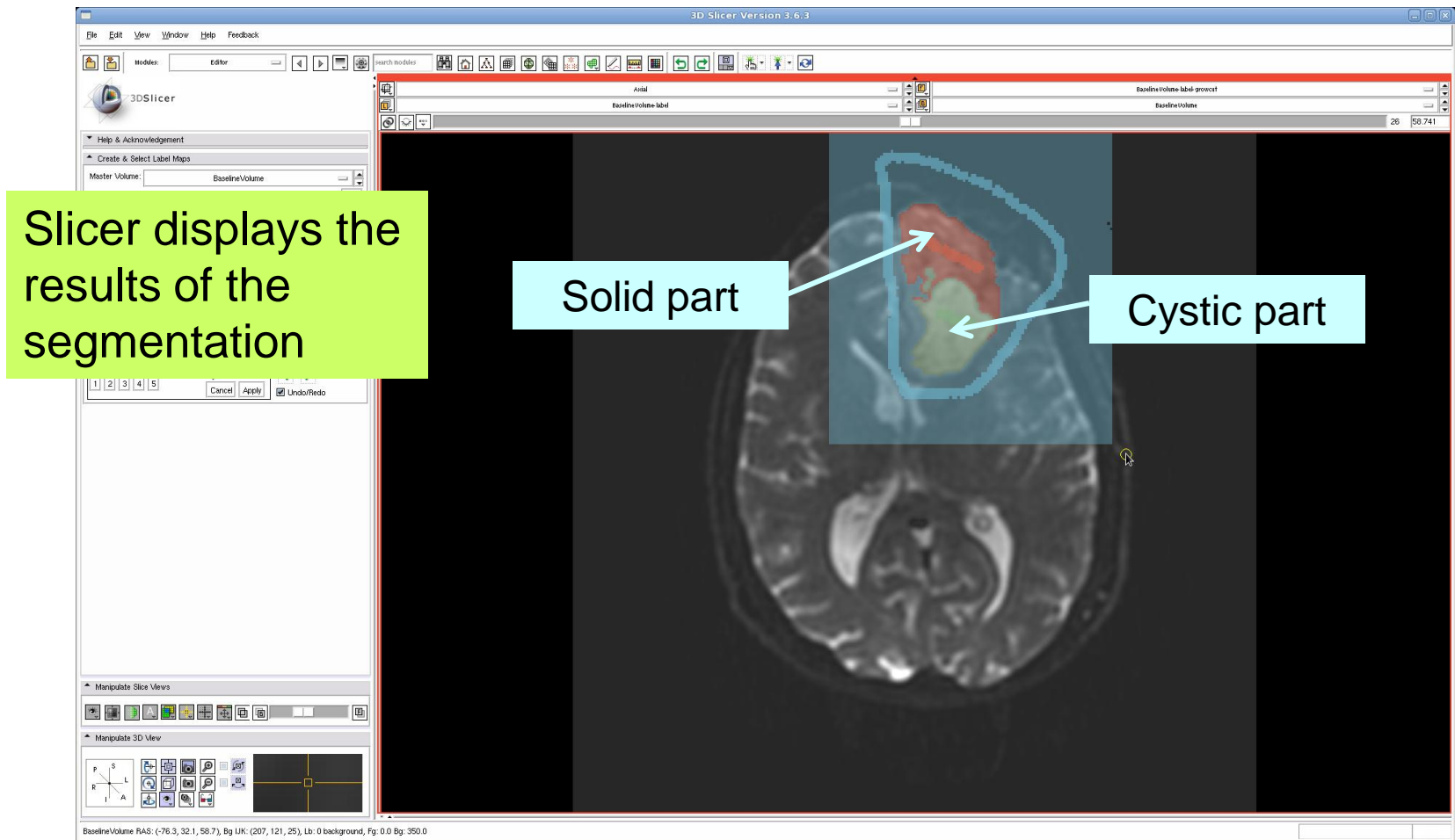
Tumor Segmentation



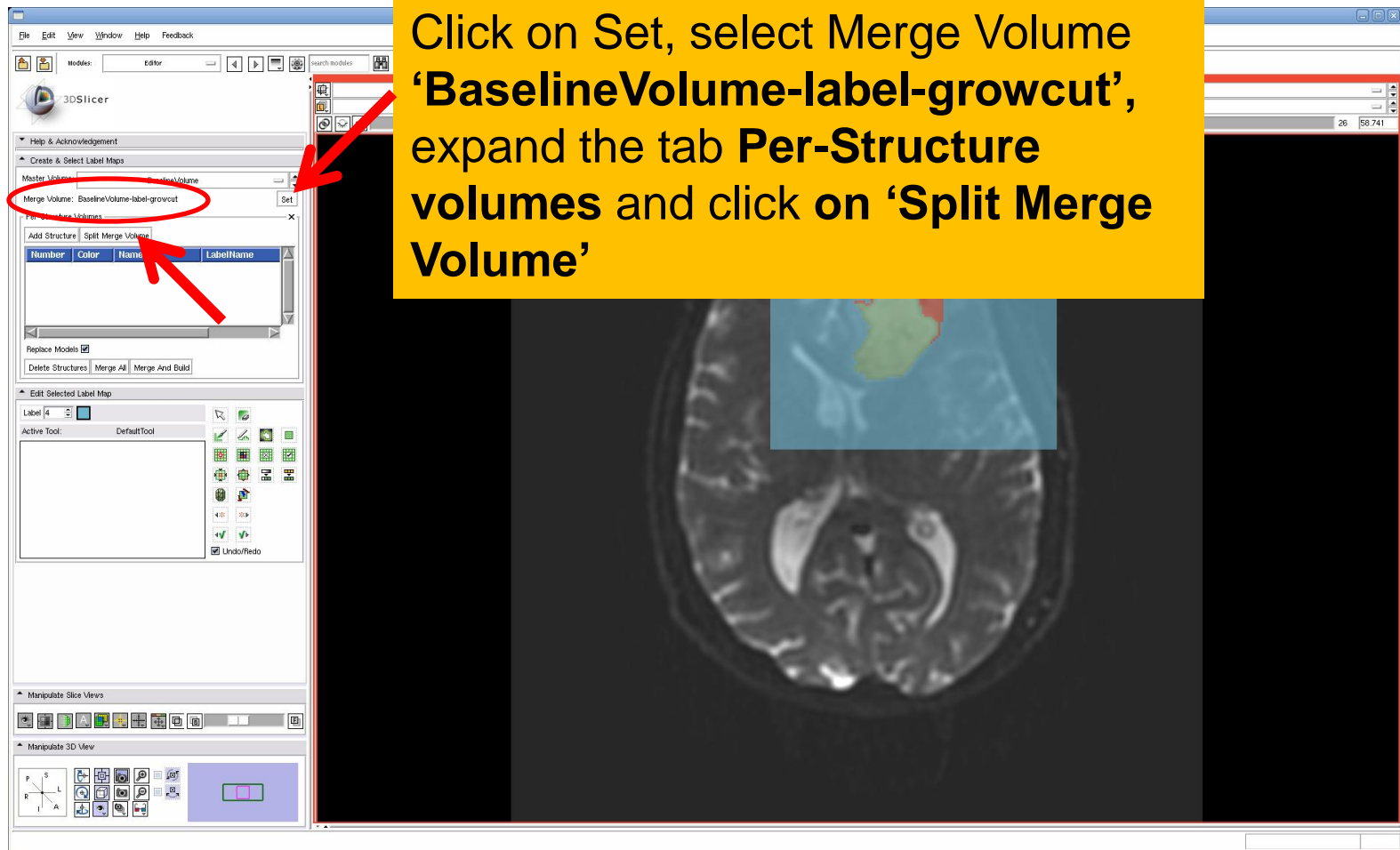
Tumor Segmentation



Tumor Segmentation



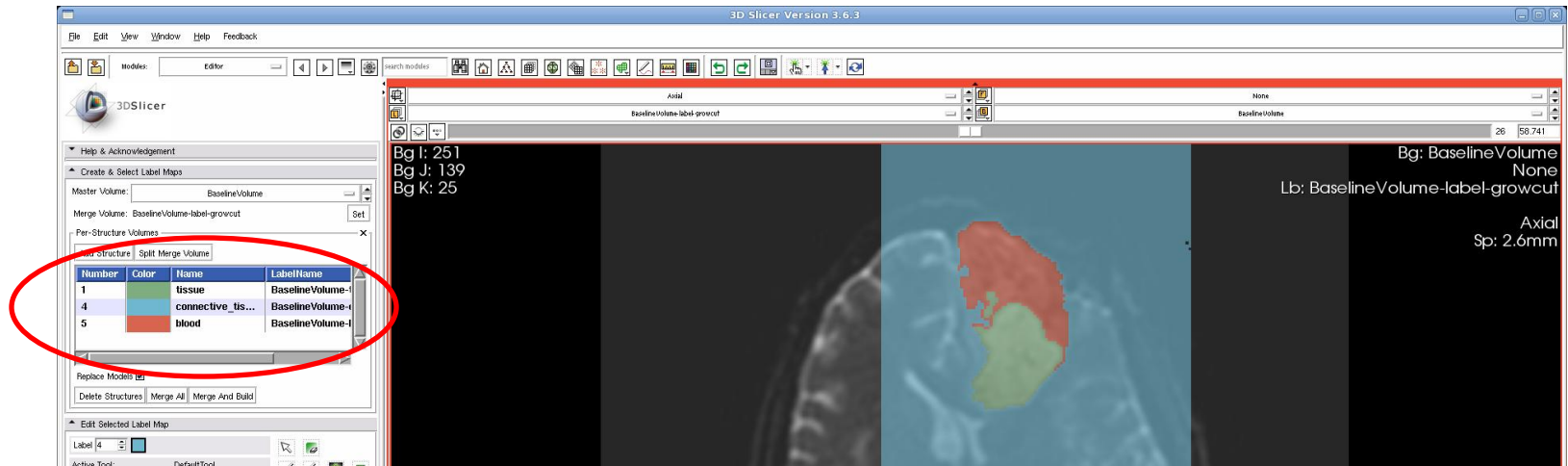
Tumor Segmentation



Click on Set, select Merge Volume 'BaselineVolume-label-growcut', expand the tab **Per-Structure volumes** and click on 'Split Merge Volume'

Number	Color	Name	LabelName
--------	-------	------	-----------

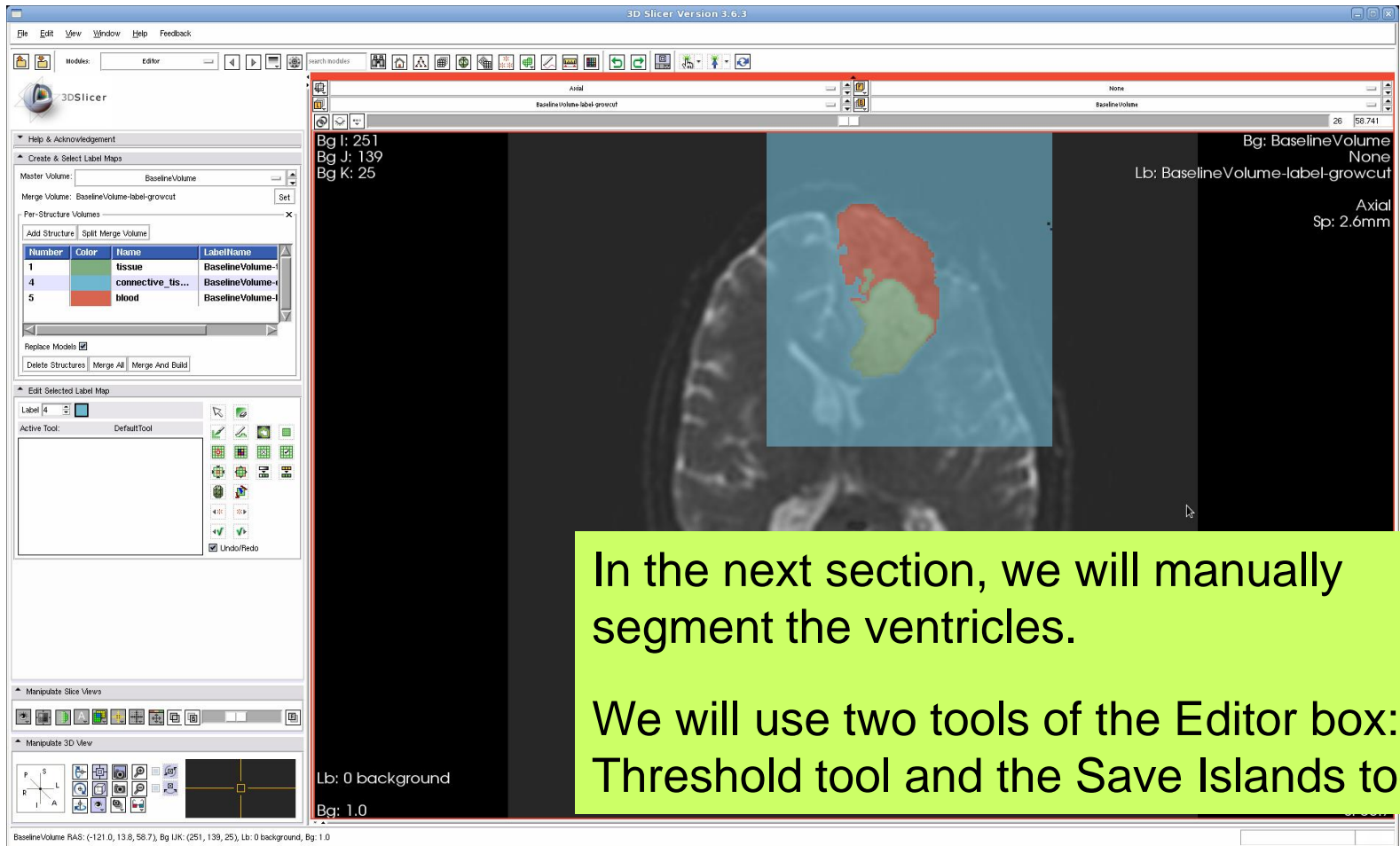
Tumor Segmentation



The label map **BaselineVolume-label-growcut** has been split into three volumes:

- BaselineVolume-tissue-label** (label1): cystic part of the tumor
- BaselineVolume-connective_tissue-label** (label 4): ventricles
- BaselineVolume-blood-label** (label 5): solid part of the tumor

Ventricles Segmentation




In the next section, we will manually segment the ventricles.

We will use two tools of the Editor box: the Threshold tool and the Save Islands tool.

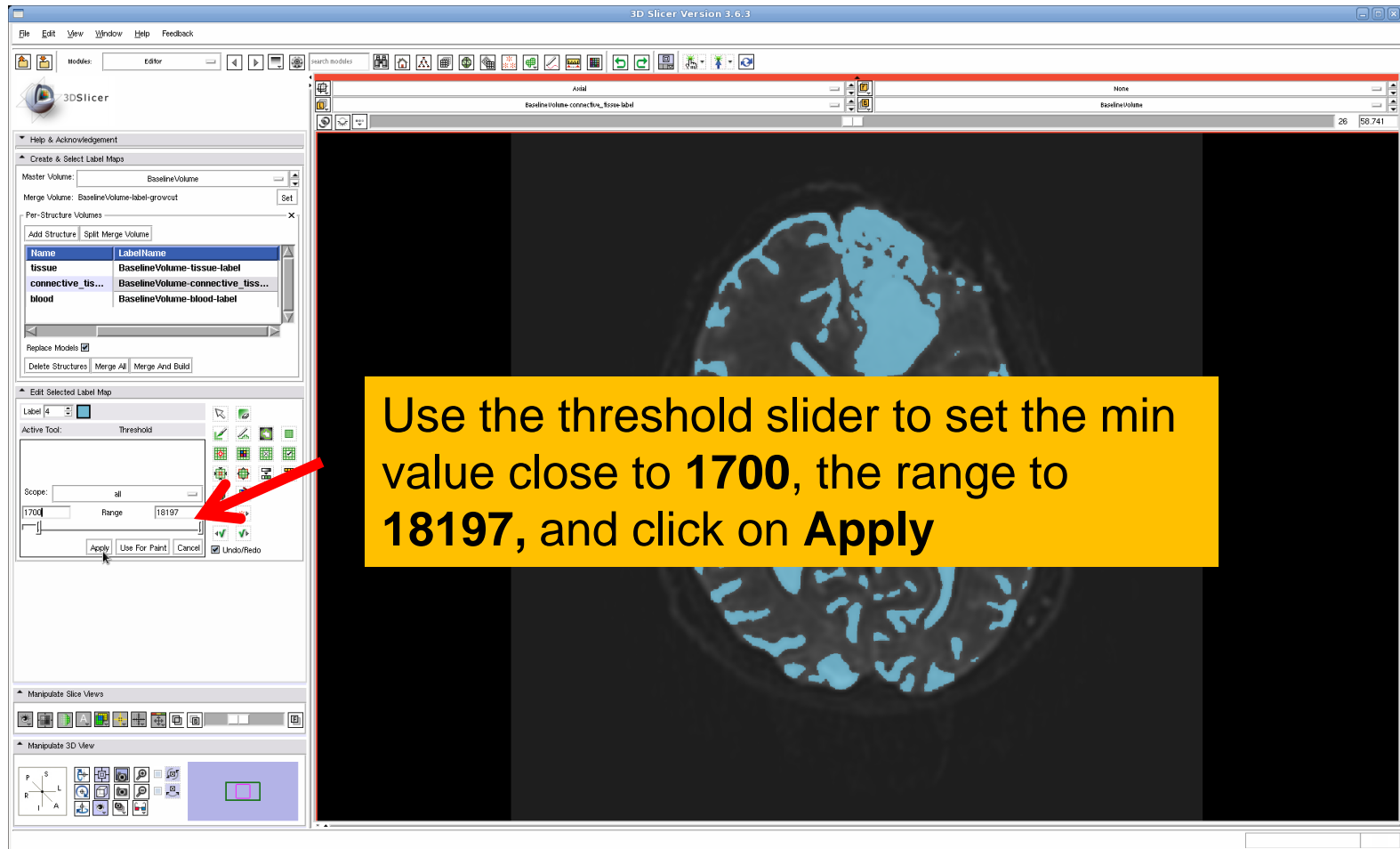
Ventricles Segmentation

Select the volume
'BaselineVolume-connective_tissue-label' (label 4)

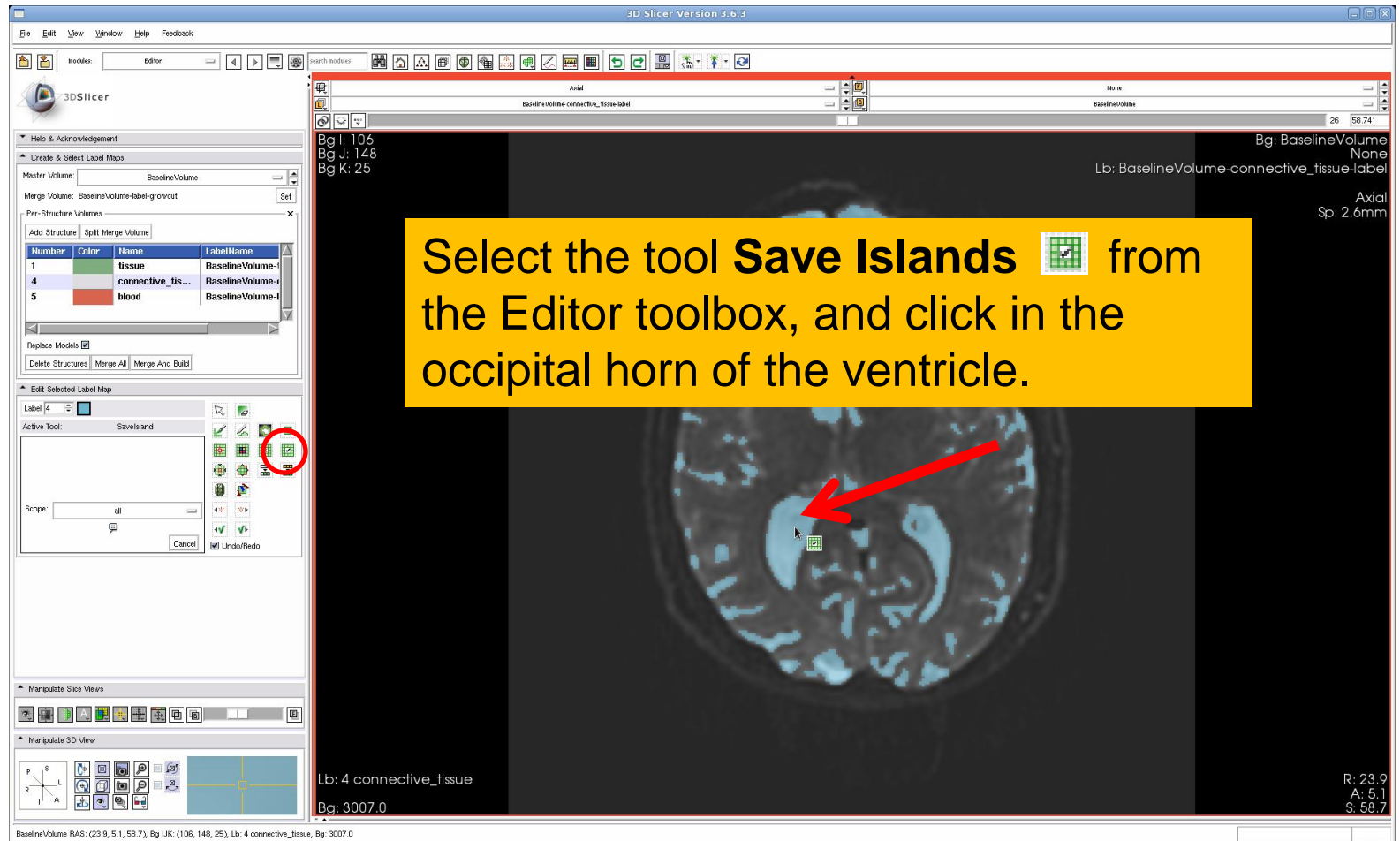
Select the Threshold tool  in the
Editor toolbox

Number	Color	Name	LabelName
1	Green	tissue	BaselineVolume-t...
4	Blue	connective_tis...	BaselineVolume-t...
5	Red	blood	BaselineVolume-t...

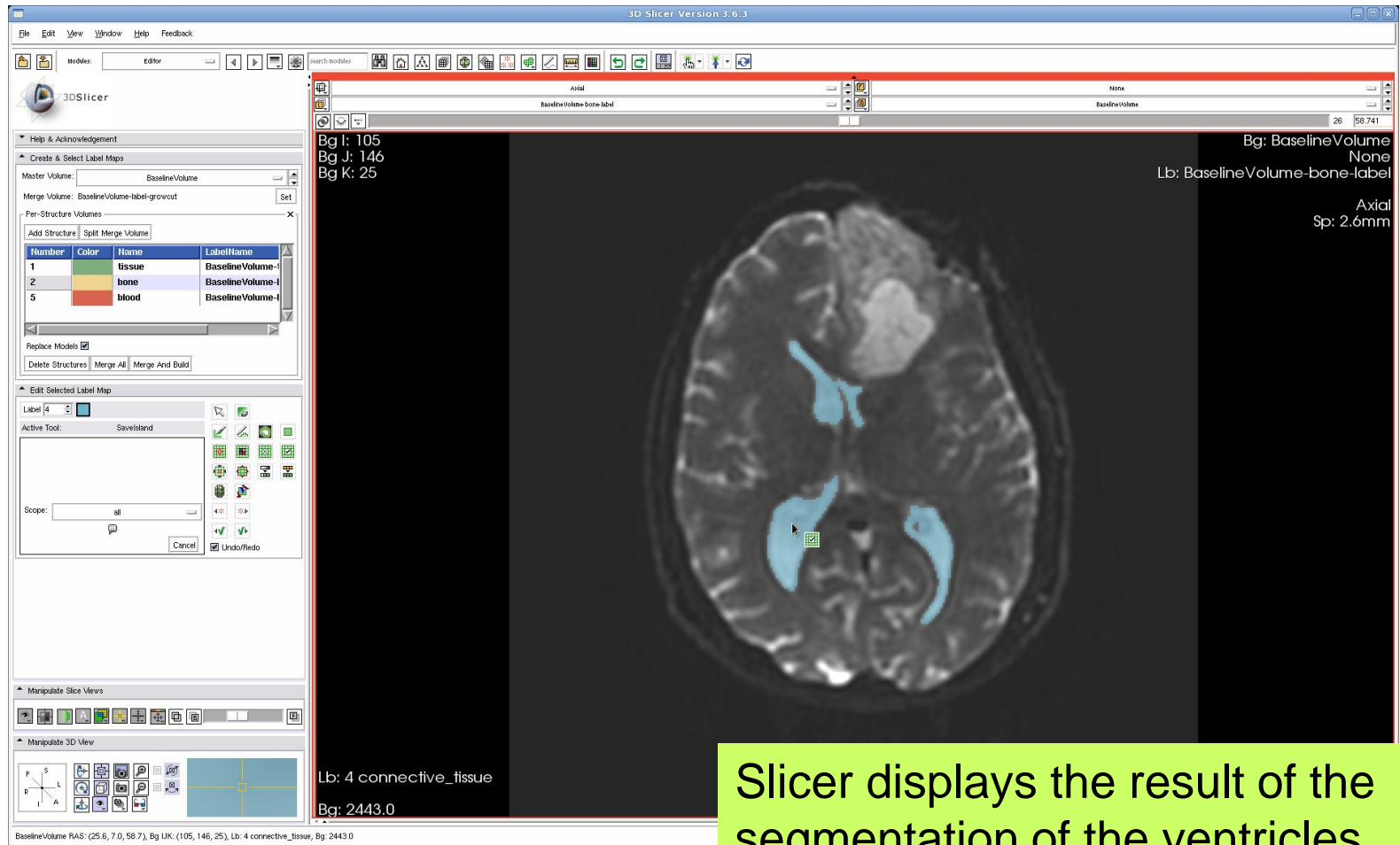
Ventricles Segmentation



Ventricles Segmentation



Final Result of the Segmentation



Final Result of the Segmentation

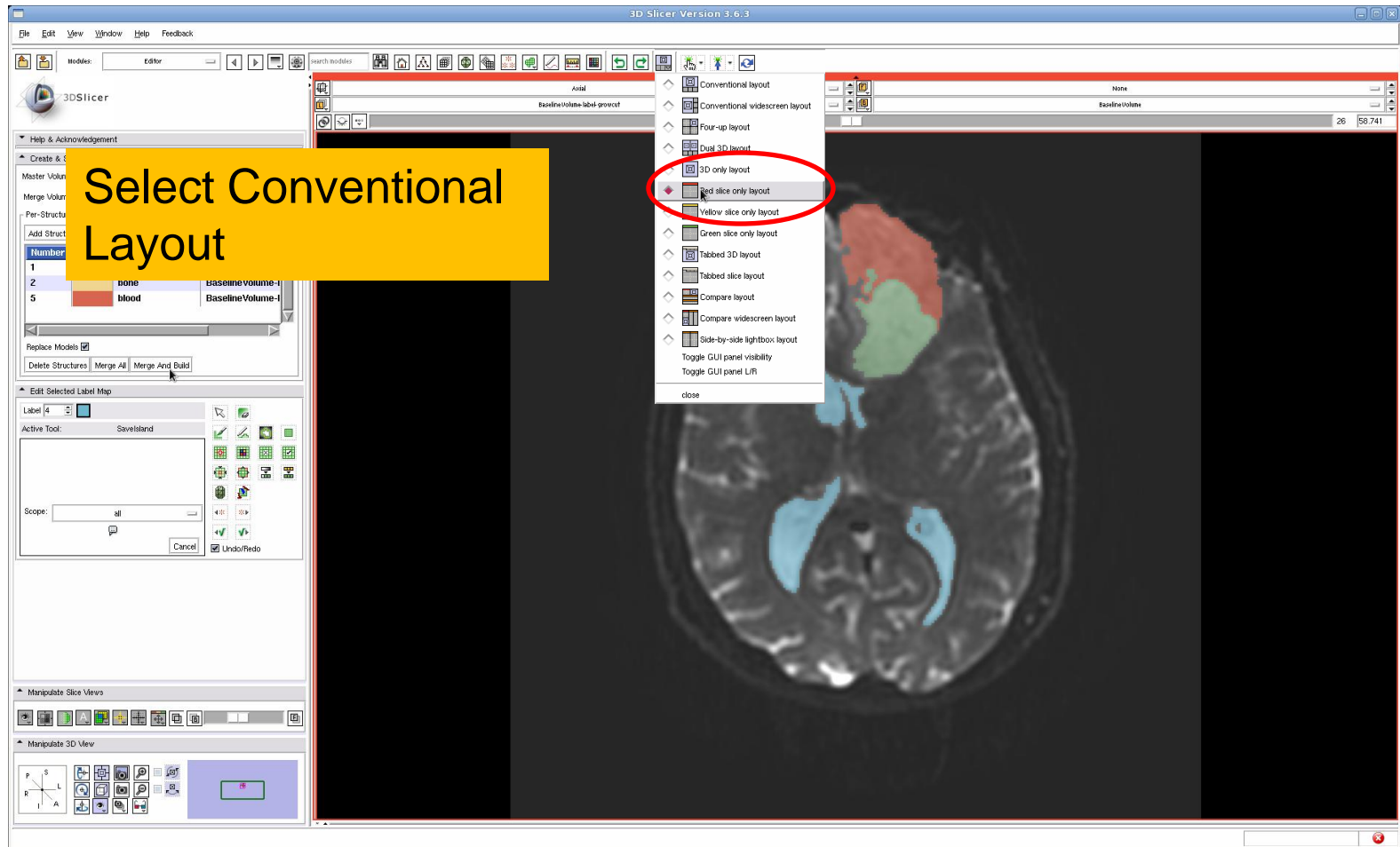
Click on **Merge and Build** to merge the different labelmaps, and generate the 3D models of the tumor and ventricles using a Marching Cubes algorithm

Number	Color	Name	LabelName
1	green	tissue	BaselineVolume-1
2	orange	bone	BaselineVolume-1
5	red	blood	BaselineVolume-1

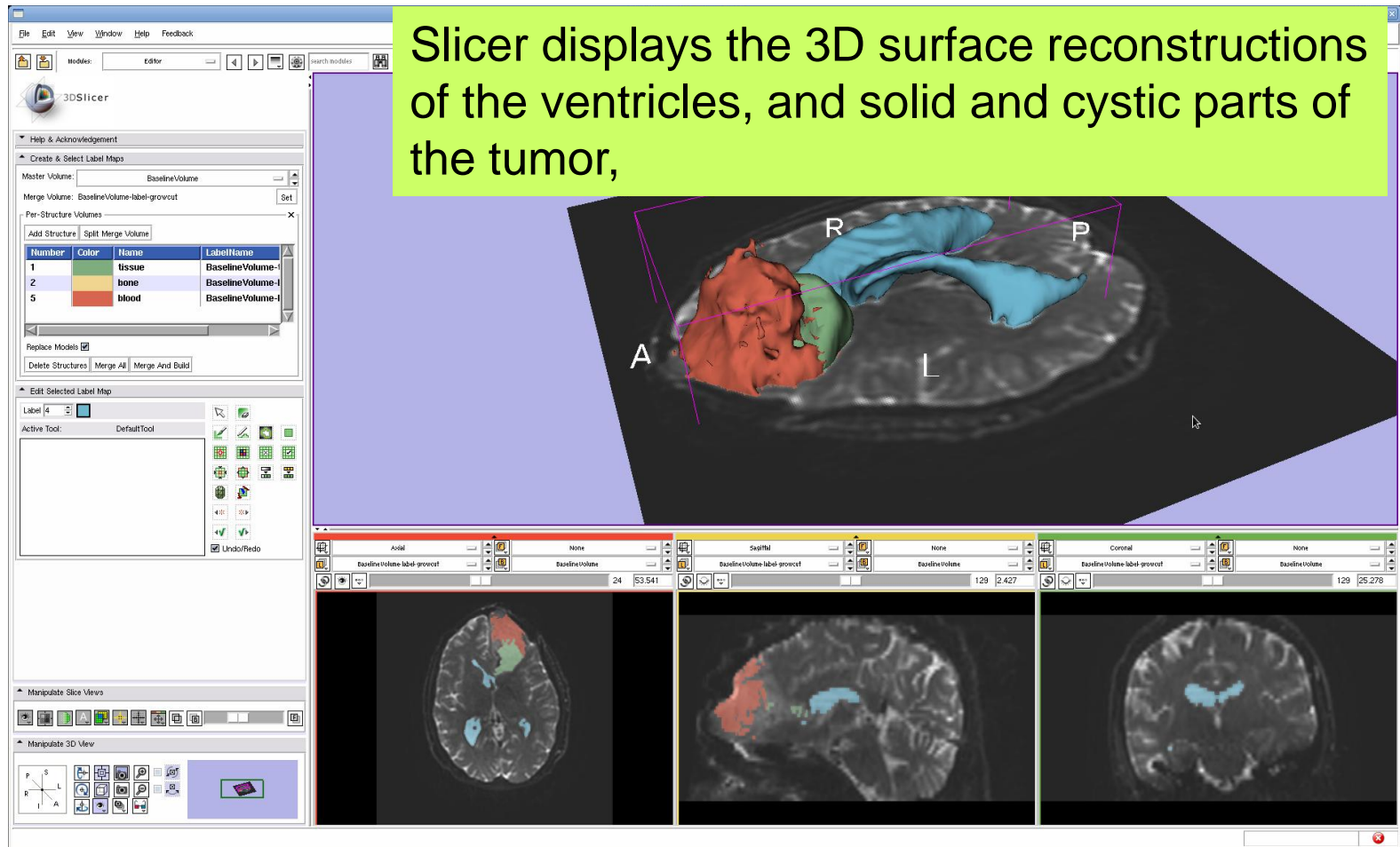
BaselineVolume RAS: (25.6, 7.0, 58.7), Bg UK: (105, 146, 25), Lb: 4 connective_tissue, Bg: 2443.0


R: 25.6
A: 7.0
S: 58.7

Final Result of the Segmentation



Final Result of the Segmentation





Part 2: Tractography exploration of peri- tumoral white matter fibers

Definition of the peri-tumoral volume

Select the label map 'BaselineVolume-tissue' (label 1, green), and select the tool 'Dilate' in the Editor toolbox

Number	Color	Name	LabelName
1	Green	tissue	BaselineVolume-t
2	Yellow	bone	BaselineVolume-t
5	Red	blood	BaselineVolume-t

The screenshot shows the 3D Slicer interface. The 'Create & Select Label Maps' panel is visible on the left, with a red arrow pointing to the 'tissue' label (label 1, green). The 'Edit Selected Label Map' panel below it shows the 'Dilate' tool selected in the 'Active Tool' section. The main 3D view shows a brain scan with a green volume highlighted, and the 'Manipulate 3D View' panel at the bottom shows three orthogonal views (Axial, Sagittal, Coronal).

Definition of the peri-tumoral volume

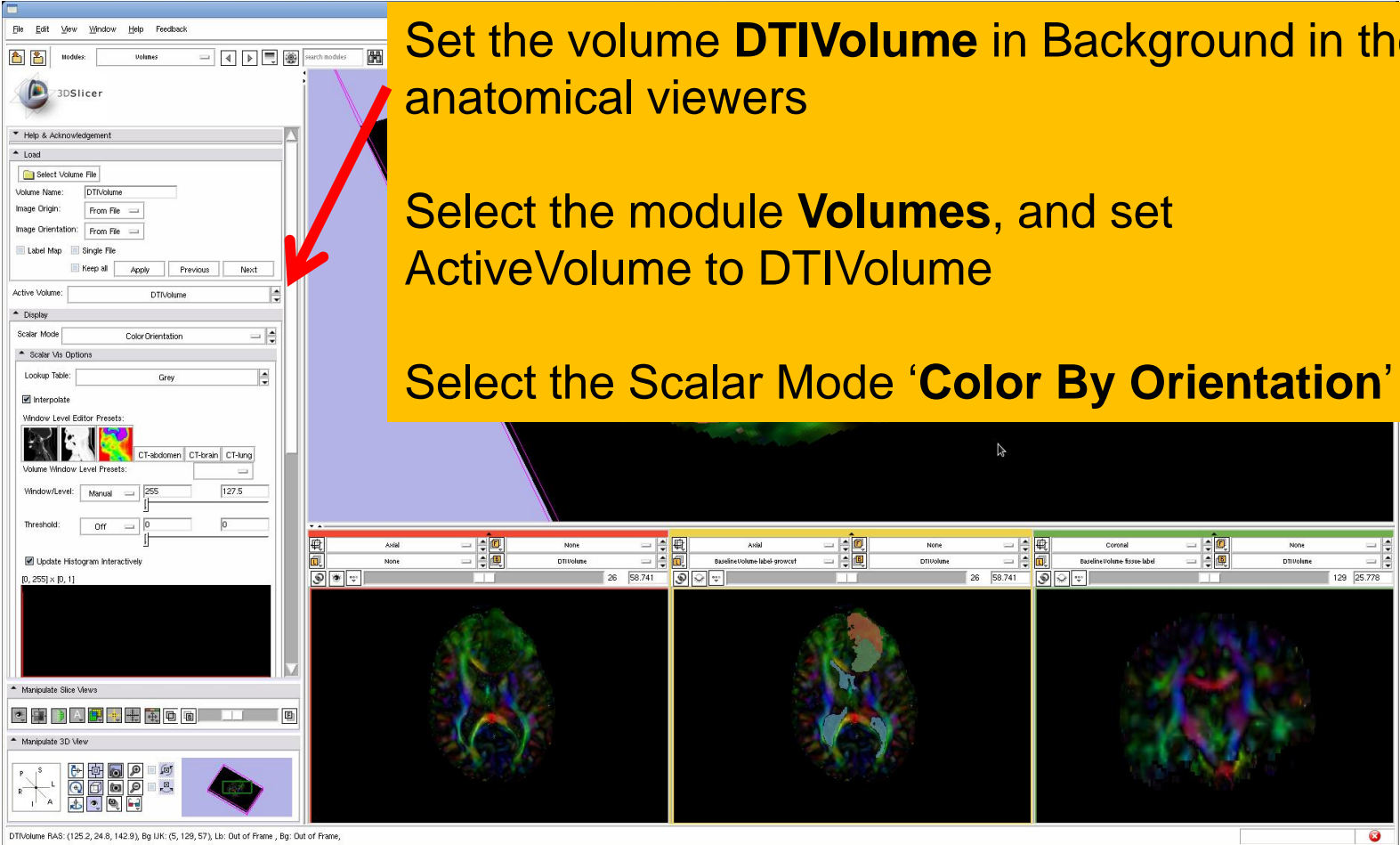
Position the mouse the cystic part of the tumor in the axial slice, and click on Apply three times to generate the peritumoral volume

The screenshot displays the 3D Slicer interface. On the left, the 'Create & Select Label Maps' panel shows a table of structures:

Number	Color	Name	LabelName
1	tissue	BaselineVolume-t	BaselineVolume-t
2	bone	BaselineVolume-l	BaselineVolume-l
5	blood	BaselineVolume-l	BaselineVolume-l

Below the table, the 'Edit Selected Label Map' panel is visible, with the 'Apply' button circled in red. The main 3D view shows a brain model with a red tumor and a green peri-tumoral volume. The axial slice view at the bottom left shows a red arrow pointing to the green highlighted area. The status bar at the bottom indicates: 'BaselineVolume RAS: (-102.8, 46.8, 53.5), Bg IJK: (233, 106, 23), Lb: 0 background, Bg: 1.0'.

Visualization of the DTI Volume



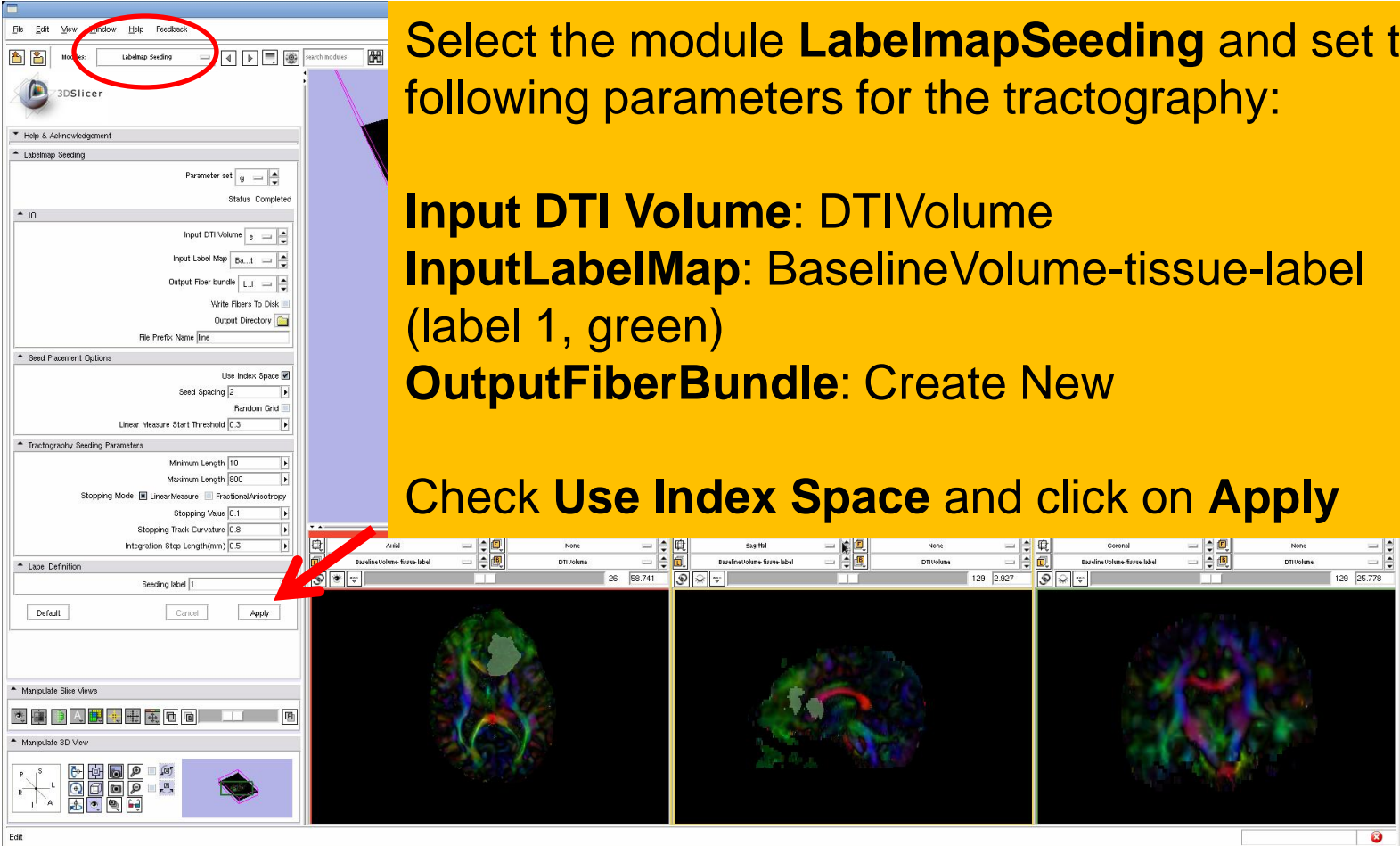
The screenshot shows the 3DSlicer software interface. On the left, the 'Load' panel is active, showing 'Volume Name: DTIVolume' and 'Active Volume: DTIVolume'. The 'Display' panel is also visible, with 'Scalar Mode' set to 'Color Orientation'. A red arrow points from the 'DTIVolume' text in the 'Active Volume' field to the 'DTIVolume' text in the yellow callout box. The main window displays three viewports: Axial, Coronal, and Sagittal, each showing a color-coded DTI volume. The status bar at the bottom indicates 'DTIVolume RAS: (125.2, 24.8, 142.9), Bx LH: (5, 129, 57), Lb: Out of Frame, Bq: Out of Frame'.

Set the volume **DTIVolume** in Background in the anatomical viewers

Select the module **Volumes**, and set ActiveVolume to DTIVolume

Select the Scalar Mode '**Color By Orientation**'

Tractography Parameters

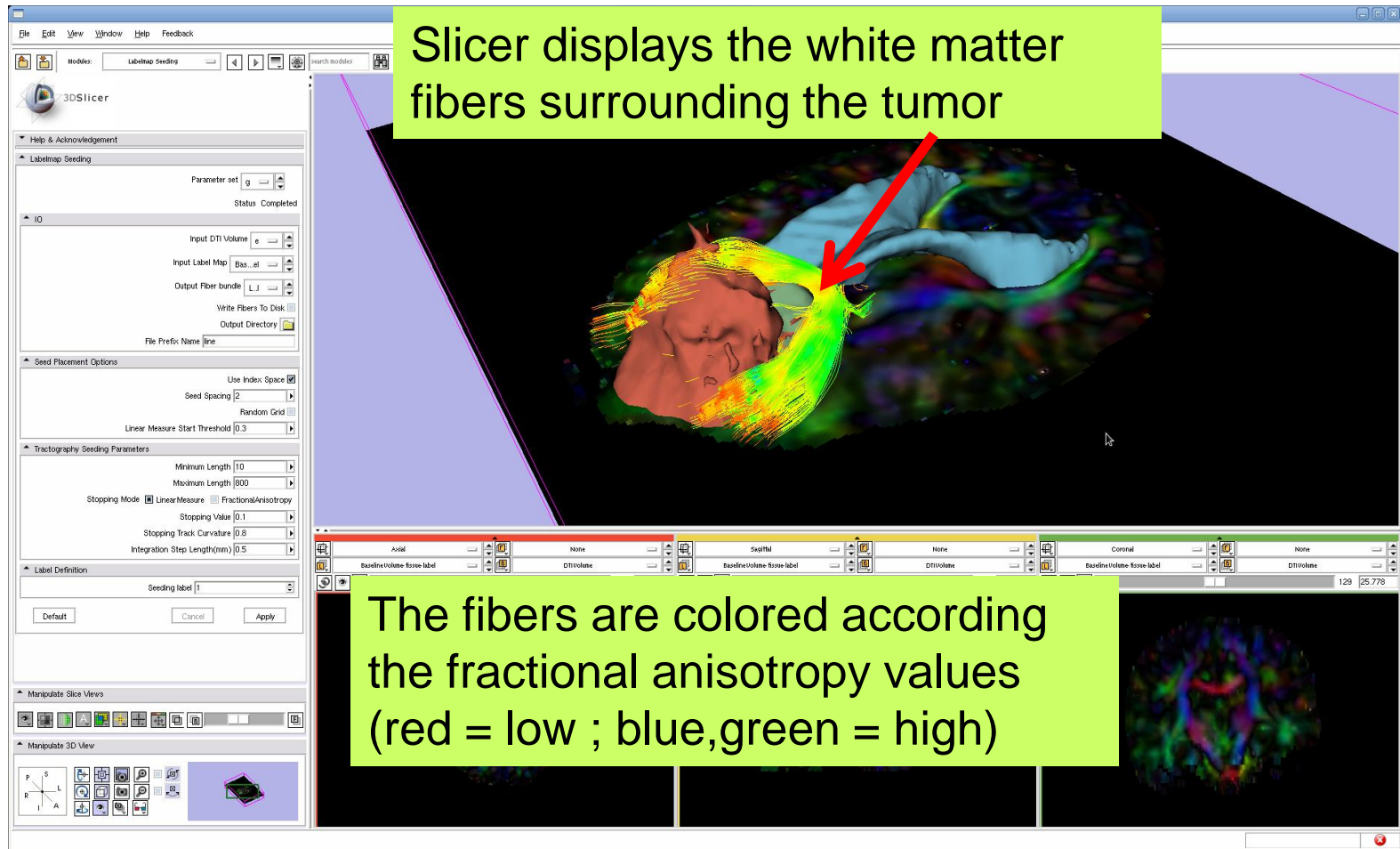


Select the module **LabelmapSeeding** and set the following parameters for the tractography:


- Input DTI Volume:** DTIVolume
- InputLabelMap:** BaselineVolume-tissue-label (label 1, green)
- OutputFiberBundle:** Create New

Check **Use Index Space** and click on **Apply**

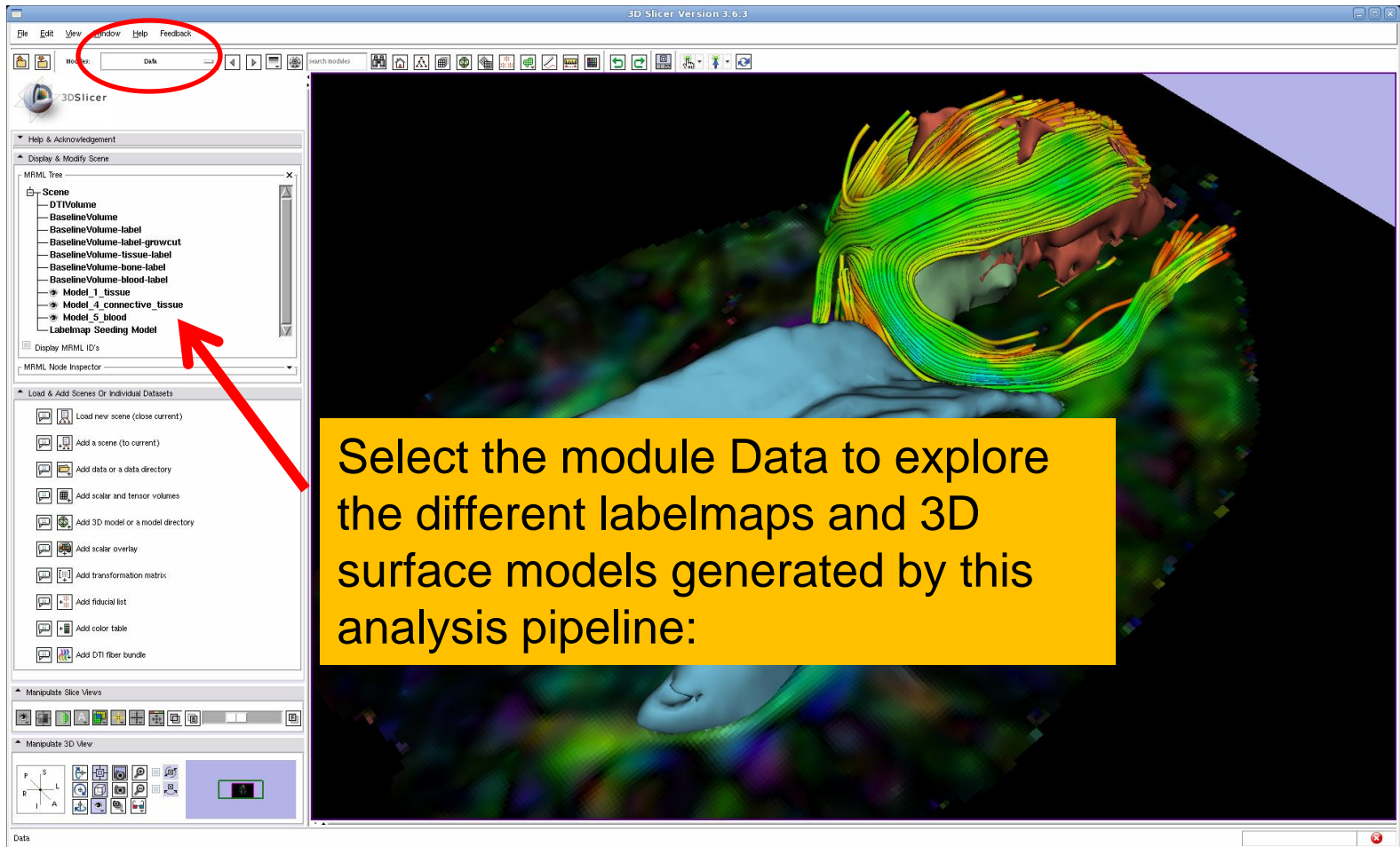
Tractography Results




Tractography Results



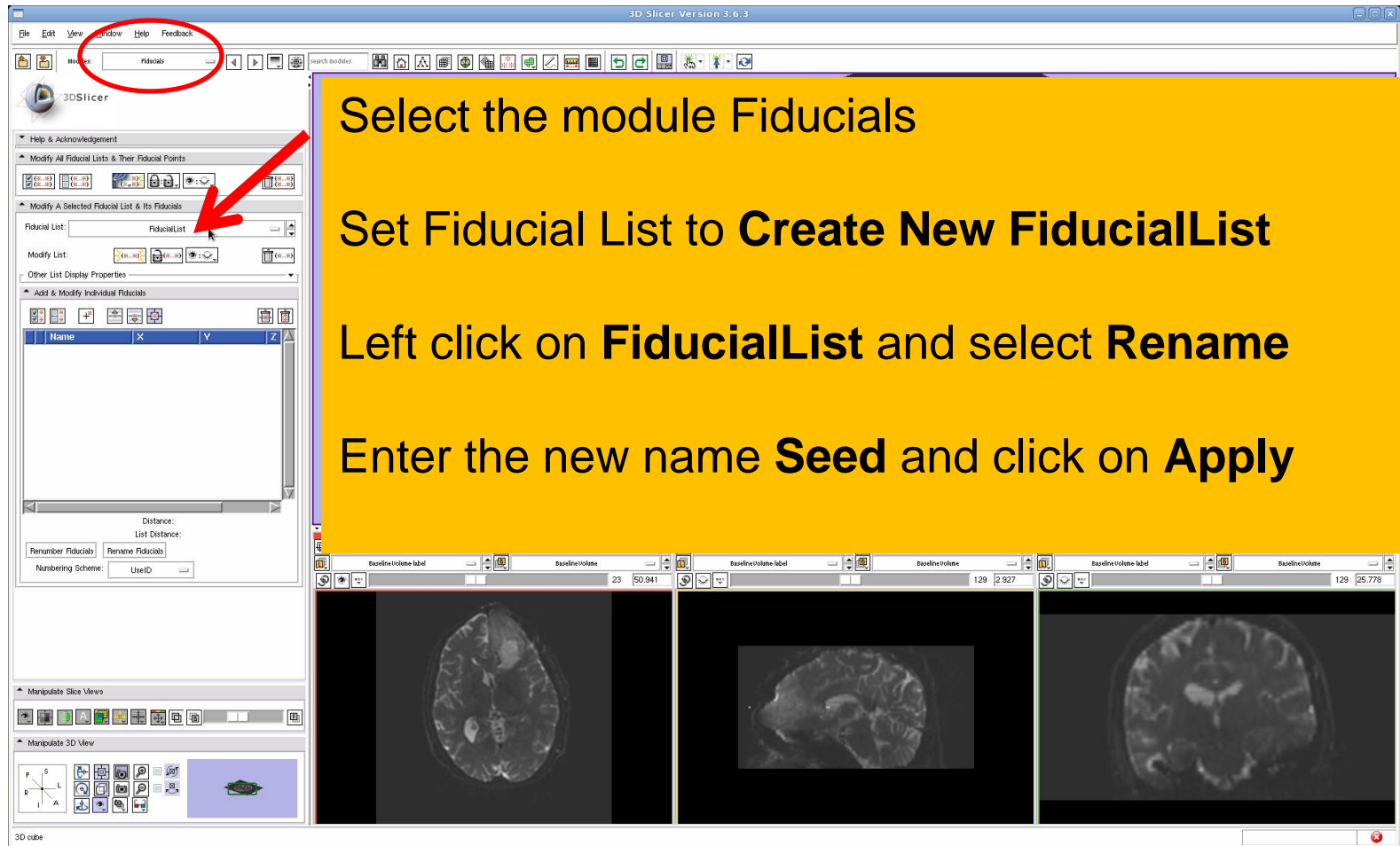
Tractography Results





Part 4: Tractography exploration of the ipsilateral and contralateral side

Tractography on-the-fly




Select the module **Fiducials**

Set Fiducial List to **Create New FiducialList**

Left click on **FiducialList** and select **Rename**

Enter the new name **Seed** and click on **Apply**

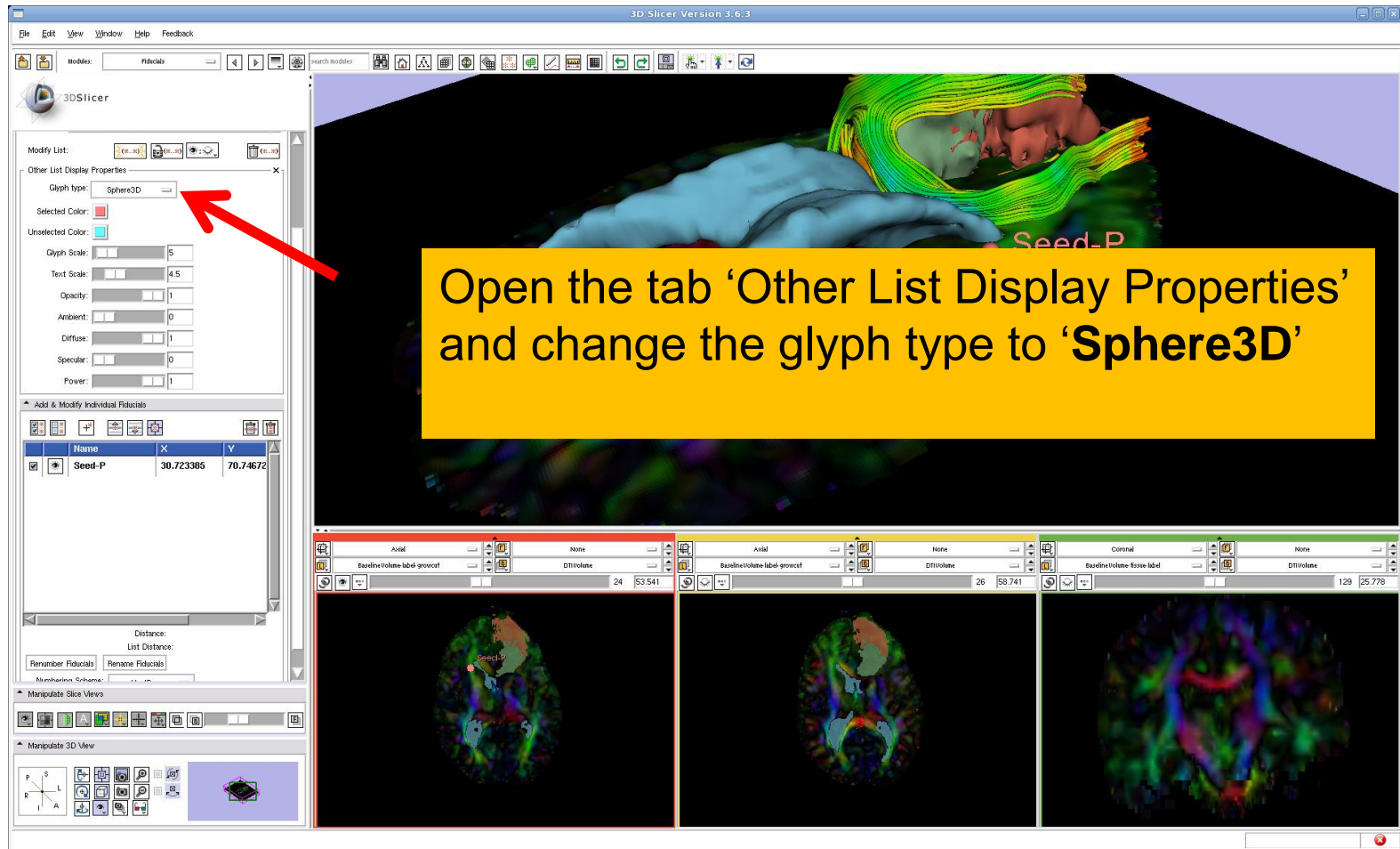Tractography on-the-fly

Click on the cross icon  to add a fiducial to the list Seed

Check the box to activate the fiducial **Seed-P1**

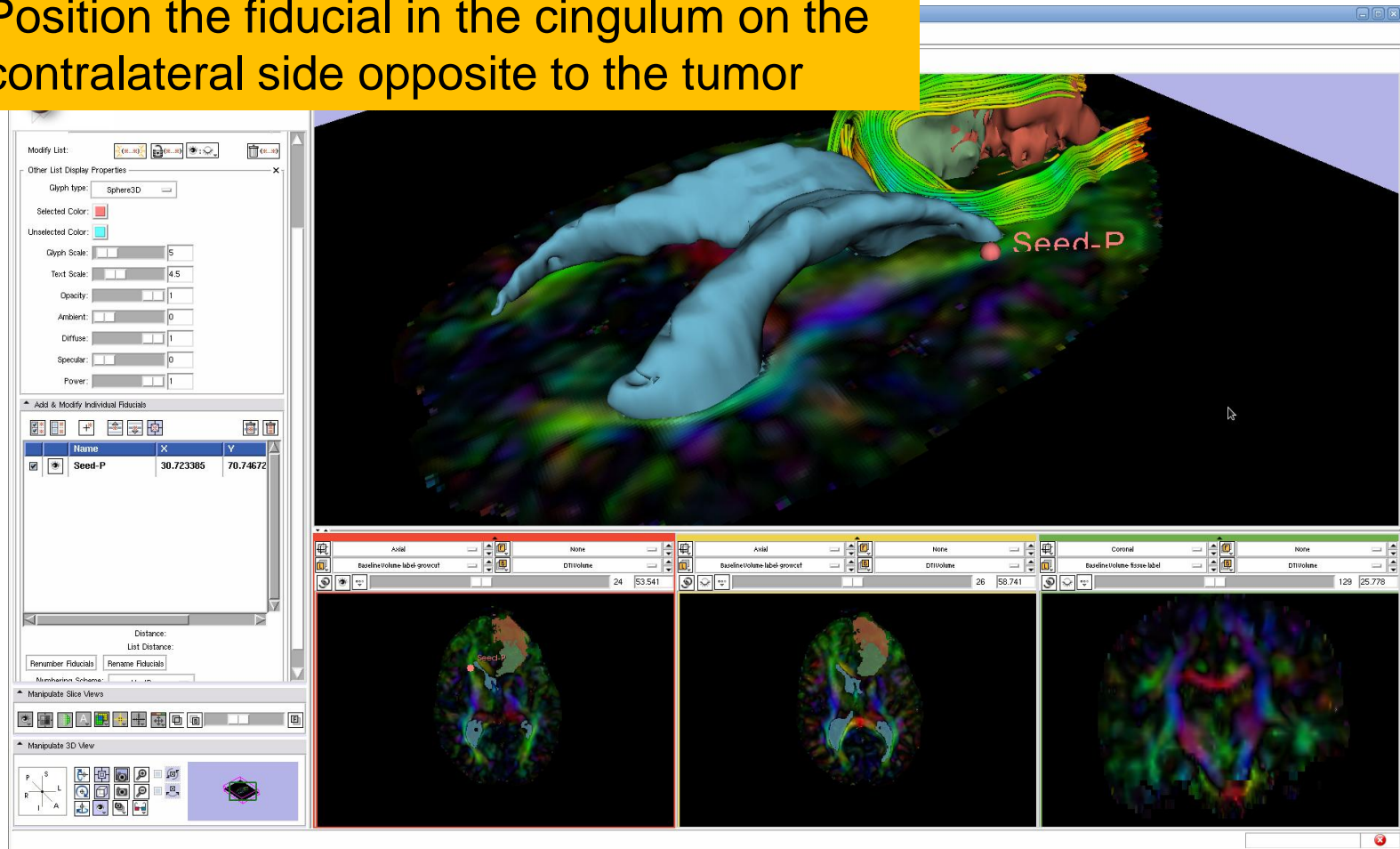
	Name	X	Y
<input checked="" type="checkbox"/>	Seed-P1	0.000000	0.000000

Fiducial Seeding

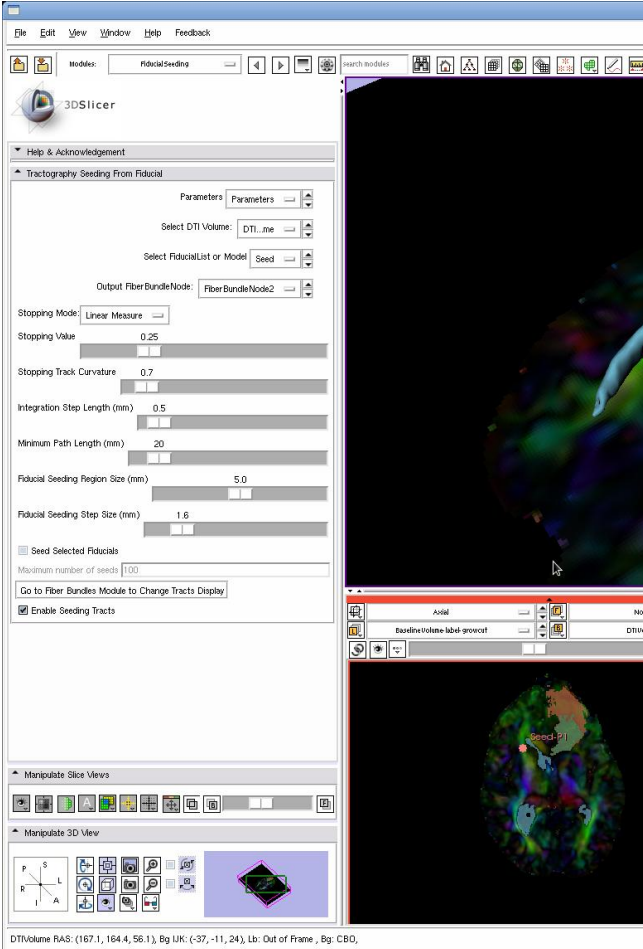


Fiducial Seeding

Position the fiducial in the cingulum on the contralateral side opposite to the tumor



Tractography on-the-fly



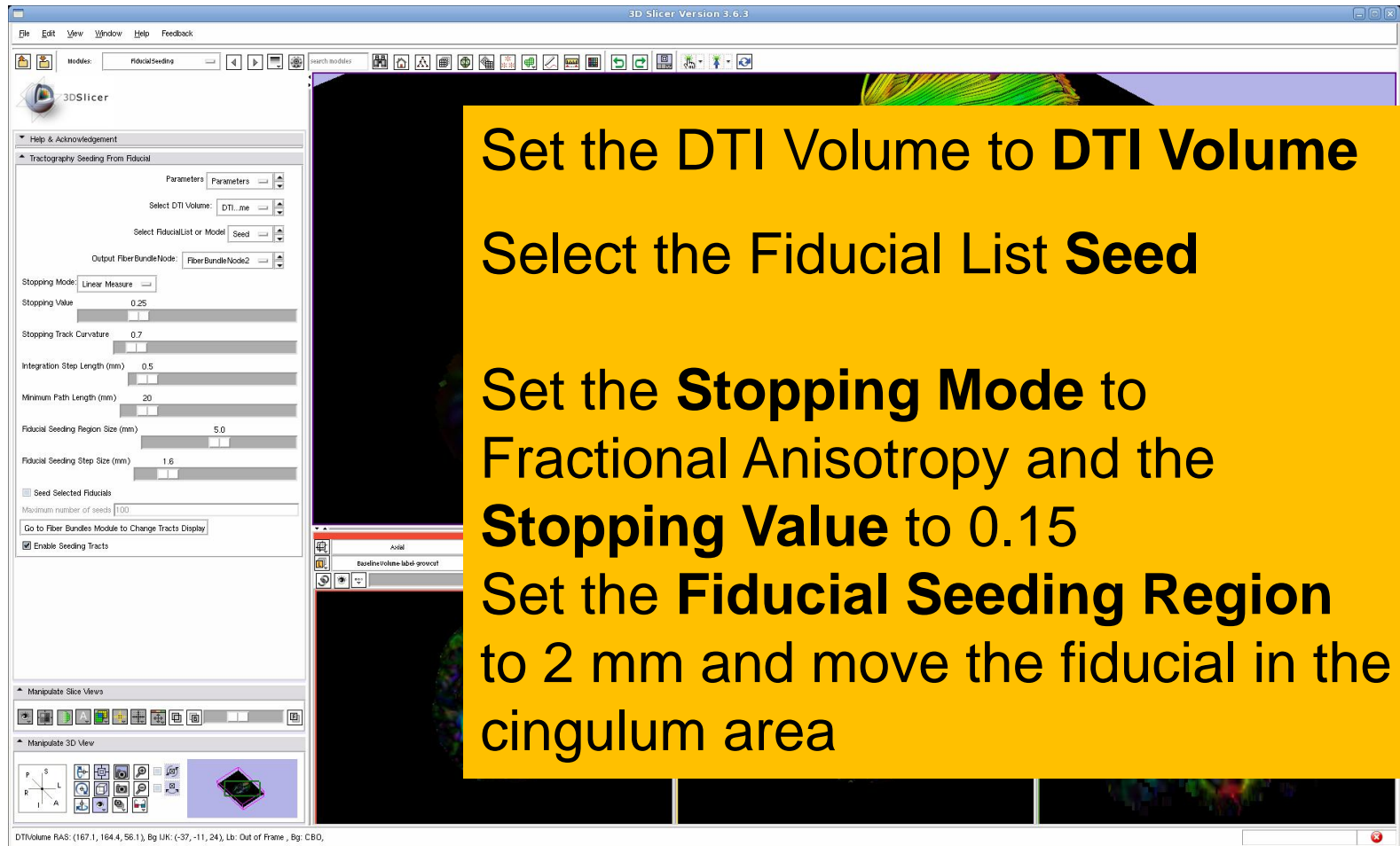
Select the module **Fiducial Seeding**

Set the Output FiberBundleNode to **Create New FiberBundle**

Important: this step must be done first

DTIVolume RAS: (167.1, 164.4, 56.1), By IJK: (-37, -11, 24), Lb: Out of Frame , Bg: C80.

Tractography on-the-fly



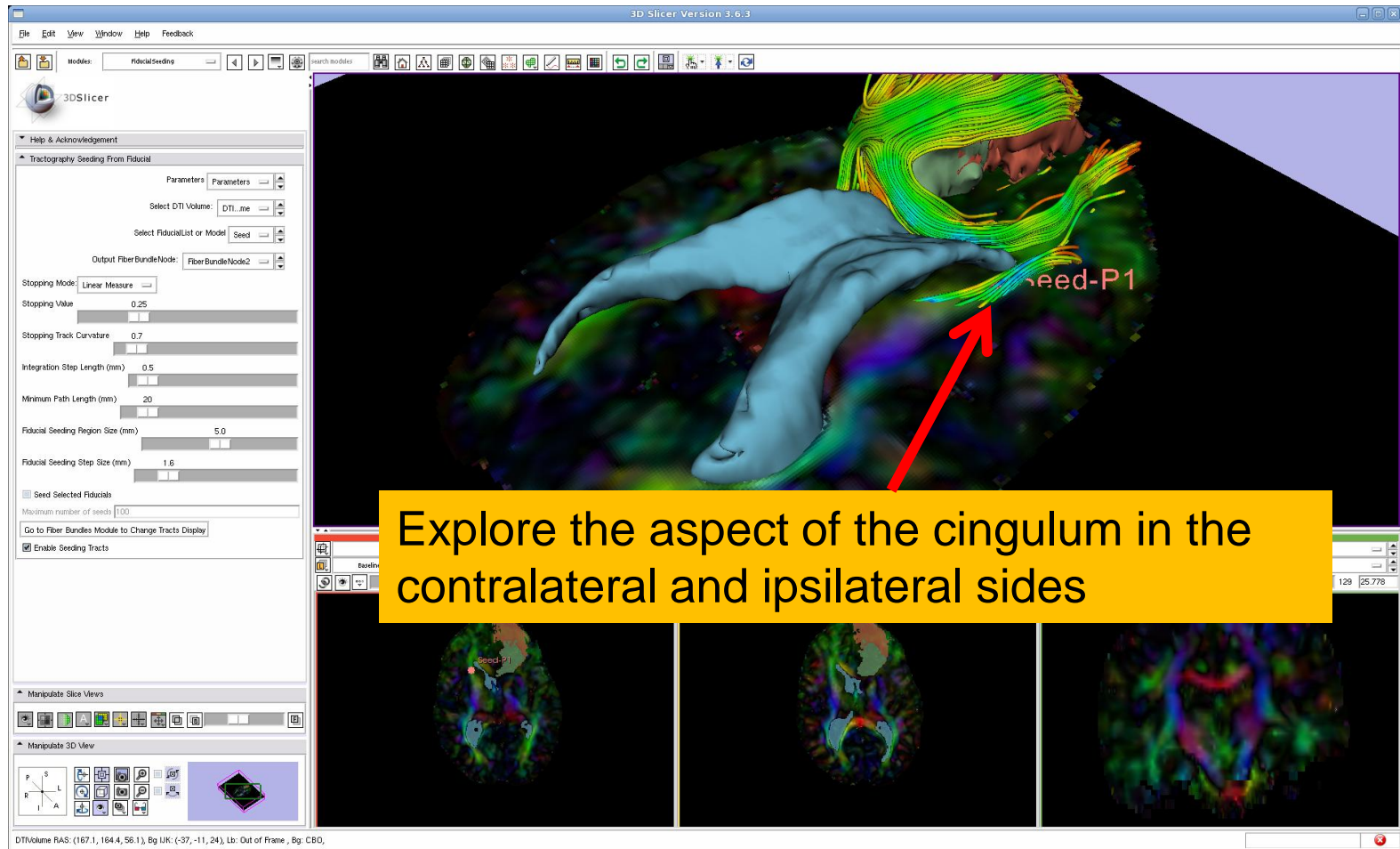
Set the DTI Volume to DTI Volume

Select the Fiducial List Seed

Set the Stopping Mode to Fractional Anisotropy and the Stopping Value to 0.15

Set the Fiducial Seeding Region to 2 mm and move the fiducial in the cingulum area

Tractography on-the-fly



Conclusion

- Fully integrated pipeline for semi-automated tumor segmentation and white matter tract reconstruction
- 3D interactive exploration of the white matter tracts surrounding a tumor (peri-tumoral tracts) for neurosurgical planning
- Validation of tractography findings still needed

Neurosurgical Planning Workshop, September 18, 2011 - Toronto

page discussion view source history

Events: DTI Tractography Challenge MICCAI 2011

Contents [hide]

- 1 DTI Tractography for Neurosurgical Planning: A Grand Challenge
- 2 Overview
- 3 Faculty
- 4 DTI Tractography Challenge
- 5 Workshop Datasets
- 6 Workshop Format
- 7 Submission Guidelines
- 8 Evaluation
- 9 How to participate in the Challenge
- 10 Logistics



18-22 September
MICCAI 2011
Toronto, CANADA

14th International Conference on Medical Image Computing and Computer Assisted Intervention

DTI Tractography for Neurosurgical Planning: A Grand Challenge

Welcome to the 'DTI Tractography for Neurosurgical Planning: A Grand Challenge' workshop. The goal of this initiative is to compare Diffusion Tensor Imaging Tractography algorithms for reconstructing white matter bundles for pre-surgical planning. The workshop is part of the 14th International Conference on Medical Image Computing and Computer Assisted Intervention [MICCAI 2011](#), to be held from 18th to 22th September 2011 in Toronto, Canada.

Overview

Diffusion Tensor Imaging (DTI) tractography has a unique potential for neurosurgical planning since it provides a window on the complex organization of white matter pathways *in-vivo*. During the past decade, the MICCAI community has been a major contributor to the development and refinement of a wide variety of advanced tractography techniques. Still the transfer of these cutting-edge algorithms to clinical routine is hindered by the difficulties of validating tractography results. The DTI Tractography Challenge workshop will give participants the opportunity to evaluate the performances of their tractography algorithms in a neurosurgical context. Participants will gain insights on the currently available gold-standard for evaluating tractography results in the Operating Room, in the absence of ground truth.

Faculty

- Sonia Pujol, Ph.D., Surgical Planning Laboratory, Brigham and Women's Hospital, Harvard Medical School
- Ron Kikinis, M.D., Surgical Planning Laboratory, Brigham and Women's Hospital, Harvard Medical School
- Alexandra Golby, M.D., Department of Neurosurgery, Brigham and Women's Hospital, Harvard Medical School
- Guido Gerig, Ph.D., The Scientific Computing and Imaging Institute, University of Utah
- Martin Styner, Ph.D., Neuro Image Research and Analysis Laboratory, University of North Carolina
- William Wells, Ph.D., Surgical Planning Laboratory, Brigham and Women's Hospital, Harvard Medical School
- Carl-Fredrik Westin, Ph.D., Laboratory of Mathematics in Imaging, Brigham and Women's Hospital, Harvard Medical School
- Sylvain Goutard, M.Sc., The Scientific Computing and Imaging Institute, University of Utah



Neurosurgical case with left frontoparietal tumor. Neurosurgery 2011 Feb; 88(2):496-505. Image courtesy of Dr. Alexandra Golby.

DTI Tractography for Neurosurgical Planning: A Grand Challenge

September 18, 2011
MICCAI 2011 Conference
The Westin Harbor Castle
Toronto, Canada

[http://www.na-mic.org/Wiki/index.php/Events: DTI Tractography Challenge MICCAI 2011](http://www.na-mic.org/Wiki/index.php/Events:DTI_Tractography_Challenge_MICCAI_2011)

Acknowledgments



National Alliance for Medical Image
Computing (NA-MIC)

NIH U54EB005149



Neuroimage Analysis Center (NAC)

NIH P41RR013218